

JKIMSU, (2012), Vol. 1 (1) 127-131  
ISSN 2231-4261

## LETTER TO EDITOR

### Role of Oxygen-Ozone ( $O_2-O_3$ ) Injection in Discogenic Pain

Asmita P. Karnalkar<sup>1\*</sup> and Pratap B. Karnalkar<sup>2</sup>

<sup>1</sup>Department of Anesthesia, Krishna Institute of Medical Sciences University, Karad, 415539, (Maharashtra), India; <sup>2</sup> Karnalkar Backache Management & Research Centre, Sangli, 416415, (Maharashtra), India.

#### Abstract:

Medical ozone is a mixture of oxygen-ozone ( $O_2-O_3$ ) which can be used for several medical applications. Ozone chemonucleolysis by injecting mixture of oxygen-ozone is a minimally invasive technique to treat discogenic pain. Considering invasiveness and possible morbidity with surgery for discogenic pain, minimal invasive techniques are preferred. Ozone chemonucleolysis is currently available such technique which has shown promising result in recent years. It involves injection of ozone gas into the intervertebral disc under fluoroscopic guidance. This article deals with mechanism of action, indications, procedure and side effects of this technique in detail.

**Key Words:** Ozone chemonucleolysis, Discogenic pain

#### Introduction:

The short term success rate after surgery for disc herniation is around 95-98%. This decreases to 88% in long term [1]. These findings have led to research into newer minimal invasive techniques to improve clinical results. Ozone chemonucleolysis is a newer minimal invasive technique and has shown promise for the relief of herniated disc related back pain. In 2003, Andruela first reported a multicentre study of large group of

patients (600) with excellent and good outcomes of 78.3% which received intradiscal and periganglionic injection of ozone [4]. Number of studies have been published in the literature on the  $O_2-O_3$  treatment of disc herniation with satisfactory results in selected cases with positive outcome are in the range of 70-80 percent of patients [2-6]. It is effective and safe procedure. According to meta-analysis of ozone chemonucleolysis; pain and functional outcomes are similar to the outcomes for lumbar disc treated with surgery with fewer complications (<0.1%), recovery time being significantly shorter [7, 10, 15-17].

#### Mechanism of Action:

Oxygen-Ozone ( $O_2-O_3$ ) therapy exploits chemical properties of  $O_3$ , an unstable allotropic form of  $O_2$  with symbol of  $O_3$  and molecular weight of 48 k Da [8-10].

After  $O_2-O_3$  mixture is injected into the disc, ozonolysis of the nucleus pulposus proteoglycans results. Subsequent loss of water leads to shrinkage of the disc which is compressing on the nerve roots. There is further cell degeneration of the matrix of nucleus pulposus which is then replaced by fibrous tissue in about next 4-5 weeks. As the disc shrinks and mummifies, there is reduction in the venous stasis caused by the disc

compression of the surrounding vessels resulting in improved local microcirculation. Also there is increased oxygenation to the diseased tissue due to increased 2, 3 diphosphoglycerate level in the red blood cells. In addition to these effects there is also anti-inflammatory effect due to oxidizing effect of the ozone on pain producing mediators. Prostaglandins cause pain and they enhance sensitivity of nerve (endings) roots and other pain producing substances. Experimental studies have shown that  $O_2-O_3$  mixture has the same effect as steroid on cytokine production and hence pain induced by the same [11].

### Indications [13-14, 18]:

1. It is indicated in discogenic back pain where there is disc bulge without any prolapse and nerve root irritation.
2. It can be done in contained disc prolapse or disc bulge with root irritation. (Fig. -1)
3. It may be done in non-contained disc as well. (Fig. -1)

### Contraindications:

Pregnancy, G-6PD deficiency, active hyperthyroidism and progressive sensory and motor loss of the affected limb.

### Procedure:

The patient is taken to the operation room and is positioned prone with a pillow underneath the lower abdomen. The patient may or may not receive premedication. The area is prepared with anti-septic lotions and draped in sterile linen. The target disc is identified. After local anaesthesia and needle tip position

confirmation, 22G spinal needle is advanced by posterior paramedian approach towards the disc at an angle of 45 to 60 degree under fluoroscope or CT guidance. When needle enters into the disc a specific resistance is felt. Before injection, it is confirmed that needle tip is into the nucleopulposus under the anteroposterior (AP) and lateral views to avoid injection into the outer annulus (Fig. - 2 & 3). Mutto suggested intradiscal injection under CT guidance. The advantage of CT is that it confirms needle tip in nucleopulposus without need of contrast. The contrast used; though in small amount occupies space available for  $O_3$  and hinders intradiscal absorption of  $O_3$ . Intradiscal and intra- foraminal injection can be given by posterior paramedian approach or by interlaminar approach. The site of injection is chosen on the basis of main location of symptoms. Fluoroscope is positioned in exact AP view and then fluoroscope is tilted cranially or caudally to abolish any double endplates for getting widest possible view of the disc [7, 18-19]. After that fluoroscope is rotated in axial plain so that ipsilateral facet joint divides width of vertebral body into two. The needle enters with end-on view (tunnel trajectory) into disc just lateral to superior articular process. Tip of needle is confirmed at the centre of the disc in AP and lateral views. Then 2 to 2.5 ml of  $O_2-O_3$  mixture at concentration of 20-30 microgram/ml (safe therapeutic limits) obtained with help of ozone generator is injected into the disc. Only ozone resistant syringes should be used.

**Adverse effects:**

Besides few cases reported, O<sub>2</sub>-O<sub>3</sub> therapy seems to be safe. Adverse effects like pyogenic discitis with epidural abscess and a case of verteobasilar stroke has been documented till date [20, 21].

**Role of Intramuscular Ozone [12]:**

Although natural history of acute low back pain (LBP) is often self limiting, conservative therapy is not always effective. In such cases intramuscular paravertebral injection of O<sub>2</sub>-O<sub>3</sub> mixture seems to safely and effectively relieve pain as well as reduce both disability and intake of analgesic drugs.

**Summary:**

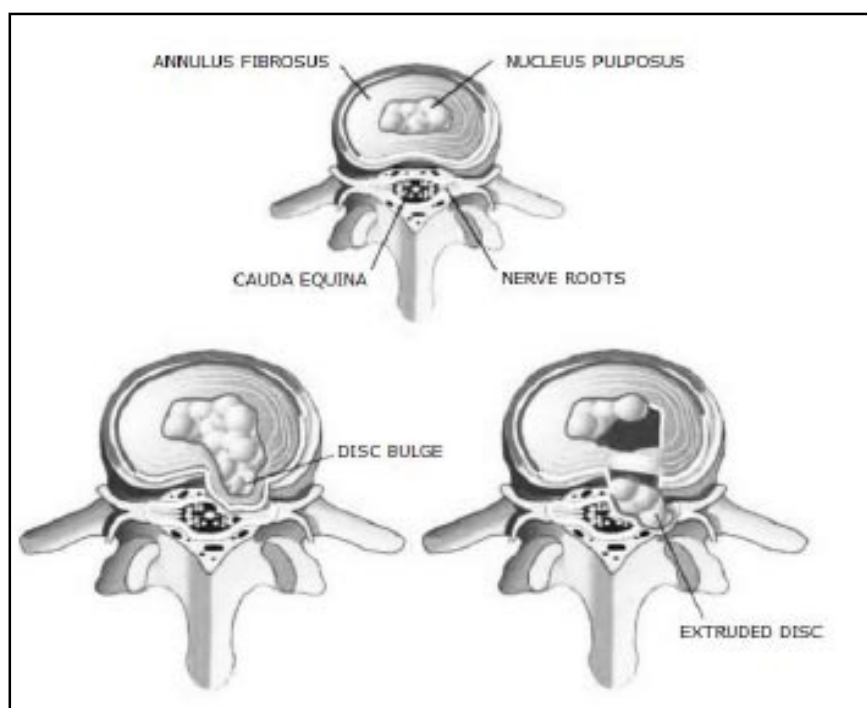
Ozone therapy due to its ease of execution and minimal invasiveness permits the successful

outcome of treatment of lumbar sciatic pain. Moreover minimum complications and satisfactory results are obtained in comparison to other methods such as chymopapain chemonucleolysis, open or microsurgery. This conservative O<sub>2</sub>-O<sub>3</sub> therapy can be considered the treatment of choice for lumbar sciatic pain and a valid alternative to surgery in the majority of selected cases.

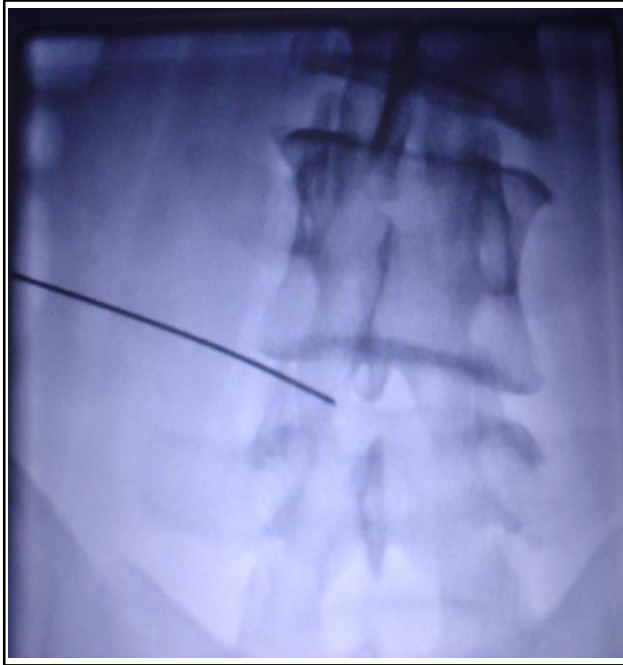Intradiscal O<sub>2</sub>-O<sub>3</sub> treatment of selected herniated lumbar disc has revolutionized the percutaneous approach to nerve root disease by making it safer, cheaper and easier than treatments currently in use. O<sub>2</sub>-O<sub>3</sub> treatment has advantage of being feasible as a treatment option in patients with root syndromes.

Careful selection of patients is recommended to ensure high success rate. Accurate

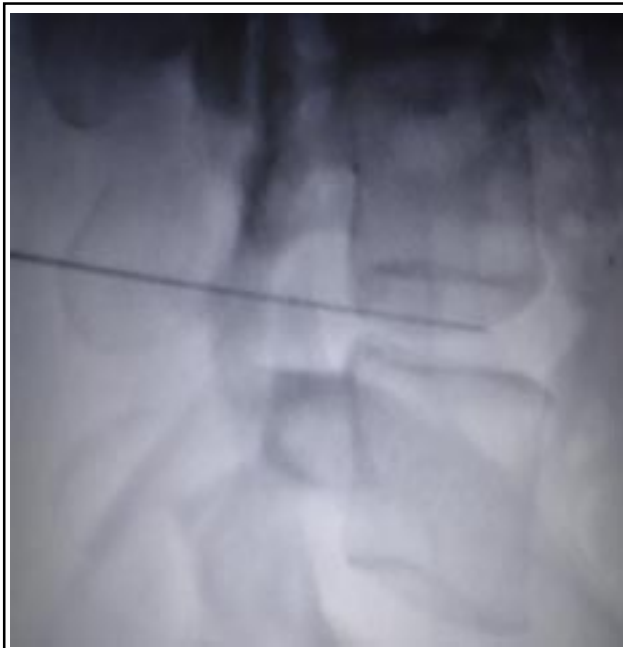**Fig 1: Normal Intervertebral disc, Disc bulge without prolapsed and extruded disc with root irritation**



**Fig 2-Antero Posterior View of L-S Spine (showing position of the needle)**



**Fig 3-Lateral View of L-S Spine (showing position of the needle)**



diagnosis of the lesion and the recognition of spinal level to be treated along with accurate technical execution under fluoroscopy or CT are key factors in ensuring the successful outcome for this common condition.

#### References:

1. Osborn AG. Non-neoplastic disorder of spine and spinal cord in diagnostic neuroradiology. St. Louis, Mosby. 1994; 820-875.
2. Alexander A, Coro L. Intradiscal inj. of O<sub>2</sub>-O<sub>3</sub> mixture for treatment of cervical disc herniation. *Acta Neurochir* 2005 (Suppl); 92:79-82.
3. Buric J, Molino LR. Ozone chemonucleolysis in non contained lumbar disc herniation. *Acta Neurochir* 2005(Suppl); 92: 92-97.
4. Muto M, Andreulla C, Treatment of herniated lumbar disc by intradiscal and intraforaminal Ozone inj. *J. NeuroRadiology* 2004; 31(3):183-189.
5. Muto M *et al.* Low back pain and sciatica treatment with intradiscal transforaminal O<sub>2</sub>-O<sub>3</sub> injection are experience. *Radio med* 2008; 113(5):695-706.
6. Andreulla C. Lumbar Herniated disk and degenerative changes. Interventional spinal treatment with chemiodiscolysis with nucleoptesis with O<sub>3</sub> and perigangliar infiltration in 150 cases. *Rivista di Neuroradiologia* 2002; 14: 81-88.
7. Gallucci M, Limbucci N .Sciatica treatment with intradiscal and intraforaminal inj. of steroid and O<sub>2</sub>-O<sub>3</sub>

- vs. steroid only-Radiology 2007, 242(3)907-13
8. Jim Steppan *et al*, A meta analysis of effectiveness and safety of ozone treatment for herniated lumbar disc, *Journal of Vascular and interven. Radio.* 2010; 21(4): 534-538
  9. Rilling S, Veibahn R; The use of ozone in medicine, 2<sup>nd</sup>ed. Kar Hang Publisher, 1994, 1-17.
  10. Staal J B, de Bie R. Injection treatment for chronic low back pain. *Cochrane data base syst. Review* 2008; 16(3) C D 001824
  11. Bocei V. Biological and clinical effects of O<sub>3</sub>. *Br J Biomed. Sc.* 56; 1990:270-279
  12. Paoloni M, Di Sante L. Intramuscular O<sub>2</sub>-O<sub>3</sub> treatment in treatment of acute back pain lumbar: multicenter, randomized, double blind, clinical trial, active and simulated lumbar paravertebral injection. *Spine* 2009; 34 (13) 1337-44.
  13. Das G, Ray S. Ozone chemonucleolysis for management of pain and disability in PIVD. *International Neuro. Radio* 2009; 15:330-4.
  14. Oder B, Loewe M. CT guided O<sub>3</sub>/steroid for treatment of the degeneration specially diseases effect of age, gender, disc pathology and multi-segments. *Neuro. Radio* 2008-50(9); 777-85.
  15. Bonetti M, Fontara A. Intraforaminal O<sub>2</sub>-O<sub>3</sub> vs. periradicular steroid in LBP: randomized control study. *AJNR.* 2005; 26:996-1000
  16. T Lehnert, M S Heri. Result of combined intra discal and periganglionic injection of medical ozone and periganglionic steroid for treatment of lumbar disc herniation. *Journal of Vascular and interven. Radio.* 2010; 21(2) S70
  17. Gautam J, Rastogi V. Comparative evaluation of ozone treatment and combined use of ozone treatment with percutaneous intradiscal radio-frequency thermocoagulation for treatment of lumbar disc herniation. *Pain Pract* 2010 (2), 160-166.
  18. Baheti DK, Bakshi S. Interventional Pain Management – A Practical Approach. First edition. 2009:308-13.
  19. Muto M, Andrela C. Treatment of herniated lumbar disc by intradiscal and intraforaminal O<sub>2</sub>-O<sub>3</sub> injection. *J Neuroradiology* 2004; 31(3):183-9.
  20. Bo W, Longyi C *et al*. Pyogenic discitis at C3-C4 with epidural abscess involving C1-C4 alter intradiscal O<sub>2</sub>-O<sub>3</sub> chemonucleolysis-a case report. *Spine* 2009, Apr; 15(3418) E: 298-304.
  21. Corea F, *et al*. A case of vertebrobasilar stroke. *Cerebrovascular diseases. J. Stroke* 2004/13(6):259-261.

\*Corresponding Author: Dr. A. P. Karnalkar, Department of Anesthesia, Krishna Institute of Medical Sciences University, Karad, 415539, (Maharashtra), India. E-mail: asmitak55@ymail.com; Cell No. : 919881584233.