

Increased percentage of L-selectin⁺ and ICAM-1⁺ peripheral blood CD4⁺/CD8⁺ T cells in active Graves' ophthalmopathy

Przemysław Pawlowski¹, Janusz Mysliwiec², Anna Stasiak-Barmuta³,
Alina Bakunowicz-Lazarczyk¹, Maria Gorska²

¹Department of Paediatric Ophthalmology and Strabismus, ²Department of Endocrinology, Diabetology and Internal Diseases, ³Laboratory of Flow Cytometry, Children's Teaching Hospital in Białystok, Medical University of Białystok, Białystok, Poland

Abstract: The purpose of the study was to evaluate the percentage of CD4⁺/CD8⁺ peripheral T cells expressing CD62L⁺ and CD54⁺ in patients with Graves' disease and to assess if these estimations could be helpful as markers of active ophthalmopathy. The study was carried out in 25 patients with Graves' disease (GD) divided into 3 groups: 1/ 8 patients with active Graves' ophthalmopathy (GO) (CAS 3-6, GO complaints \leq 1 year), 2/ 9 patients with hyperthyroid GD without symptoms of ophthalmopathy (GDtox) and 3/ 8 patients with euthyroid GD with no GO symptoms (GDeu). The control group consisted of 15 healthy volunteers age and sex matched to groups 1-3. The expression of lymphocyte adhesion molecules was evaluated by using three-color flow cytometry. In GO group the percentage of CD8⁺CD54⁺, CD8⁺CD62L⁺, CD4⁺CD54⁺ and CD4⁺CD62L⁺ T cells was significantly higher as compared to controls ($p < 0.001$, $p < 0.05$, $p < 0.01$, $p < 0.001$ respectively). In addition, the percentage of CD8⁺CD54⁺ T lymphocytes was elevated in GO group in comparison to hyperthyroid GD patients ($p < 0.05$). CD4⁺CD62L⁺ and CD8⁺CD54⁺ percentages were also increased in GDtox and GDeu as compared to controls. We found a positive correlation between the TSHRab concentration and the percentage of CD8⁺CD62L⁺ T cells in all studied groups ($r = 0.39$, $p < 0.05$) and between the TSHRab level and CAS ($r = 0.77$, $p < 0.05$). The increased percentage of CD8⁺CD54⁺ and CD8⁺CD62L⁺ T cells in patients with Graves' ophthalmopathy may be used as a marker of active orbital inflammation.

Key words: Graves' ophthalmopathy, ICAM-1, L-selectin, T lymphocytes subsets

Introduction

Despite recent progress in understanding of its pathogenesis, Graves' ophthalmopathy (GO) remains a pathogenetic enigma and a therapeutic dilemma [1,2]. GO is currently characterized as an autoimmune infiltration of the orbital connective tissue and/or extraocular muscles predominantly by activated T cells together with some B cells, plasmocytes and mastocytes. The thyrotropin receptor (TSHR) autoantigen is the probable culprit involved in GO [3,4]. Both anti-TSHR antibodies (TSHRab) and homing of autoreactive T lymphocytes can initiate or perpetuate the inflammatory process of retrobulbar tissues in GO

[5,6]. T lymphocytes which infiltrate retroocular tissues, by releasing cytokines act upon retroocular fibroblasts to stimulate cells proliferation [7]. T cells play a direct role promoting adipogenesis, glycosaminoglycan synthesis and expression of immunomodulatory proteins within the orbit [3]. The process of autoreactive T lymphocytes recruitment may be facilitated by either circulating or locally produced adhesion molecules [3], the expression of which may be induced by cytokines [6] and be related to the activity of the disease [8,9]. Adhesion molecules play a central role not only in T lymphocyte activation and localization but also T cell costimulation and various effector-target cell functions at the inflammatory sites, which result in amplification of the cellular immune process in active GO [6]. In our previous study serum L-selectin and Intercellular Adhesion Molecule-1 (ICAM-1) were found to be elevated in patients with active GO, suggesting enhanced T cell recruitment

Correspondence: P. Pawlowski, Dept. of Paediatric Ophthalmology and Strabismus, Medical University of Białystok, Waszyngtona 17 Str., 15-274 Białystok, Poland; tel.: (+4885) 7450558, fax.: (+4885) 7422775, e-mail: przem38@wp.pl

Table 1. The median and interquartile range values of CD4⁺ and CD8⁺ T lymphocytes' percentage in patients with Graves' ophthalmopathy (GO), hyperthyroid (GDtox) and euthyroid Graves' disease (GDeu)

	CD4 ⁺ T lymphocytes	CD8 ⁺ T lymphocytes	CD4 ⁺ /CD8 ⁺ ratio
GO	45.0 (36.7-47.2)	28.0 (23.3-30.5)	1.5
GDtox	44.0 (41.0-47.6)**	23.0 (22.0-24.0)* [#]	1.8
GDeu	41.0 (32.5-43.1)	31.8 (27.4-34.9)*	1.3
controls	39.0 (37.5-41.5)	28.0 (23.0-29.5)	1.4

[10]. Moreover the ICAM-1 gene polymorphism could influence the intensity and duration of the autoimmunity process and the infiltration of orbital tissues [11].

The aim of the present study was to evaluate the percentage of L-selectin⁺ (CD62L⁺) and ICAM-1⁺ (CD54⁺) expressing CD4⁺/CD8⁺ T lymphocytes in patients with Graves' disease and to assess if these estimations could be helpful as markers of active ophthalmopathy.

Material and Methods

The study was carried out in three groups comprising a total of 25 patients from Outpatient Clinic of the Department of Endocrinology, Diabetology and Internal Diseases, Medical University of Białystok

All patients were examined by the same clinician, who was blinded for the TRSHab data and who assessed the following ophthalmological parameters: visual acuity, lid width, downward movement of the lids (in millimeters), proptosis (in millimeters), inflammatory signs (redness and swelling of lids and conjunctiva), and eye motility. In case of reduced visual acuity, the cornea was stained with fluorescein, and if slit lamp and fundus examination revealed normal anatomical conditions, visual evoked potentials were done to examine optic nerve function.

Grouping of patients. The eye signs of GO were classified according to Clinical Activity Score (CAS) classification and NOSPECS amended by EUGOGO [12]: 1) active disease – CAS equal to or greater than 4 and/or NOSPECS equal to or greater than 5 (marked symptoms of GO); 2) and 3) inactive disease, CAS less than 4 and NOSPECS less than 5 (mild symptoms of GO) or no signs of ophthalmopathy and different thyroid status (hyperthyroid, euthyroid).

1) 8 patients with clinical symptoms of ophthalmopathy (GO) (5 females and 3 males, mean age 41,4±11,5 years). All the GO patients presented a Clinical Activity Score of eye changes (CAS) > 3, anamnesis of GO≤1 year, were euthyroid with thiamazol. The euthyroid state was confirmed by thyrotropin and free thyroxin estimation. They had never been treated with corticosteroids or other immunosuppressive drugs.

2) 9 patients with hyperthyroid Graves' disease without symptoms of active ophthalmopathy (GDtox) (7 females and 2 males, mean age 40,2±11,6 years) with a duration of the disease from 3-12 months. Hyperthyroidism was confirmed by thyrotropin and free thyroxin estimation.

3) 8 patients with euthyroid Graves' disease without symptoms of active ophthalmopathy (GDeu) (7 females and 2 males, mean age 42,4±11,2 years) with a duration of the disease from 3-12 months. Patients in this group were euthyroid before and during the study and euthyreoidism was confirmed TSH and free thyroxin determination.

The control group (ctrl) consisted of 15 healthy volunteers (14 females and 6 males, aged 22-40 years) who had neither a family history of Graves' disease nor other autoimmune diseases. No acute infections were observed in the GO, GD and control subjects 3 weeks prior to the study.

Written informed consent was obtained and the protocol for the study was approved by the Ethics Committee of Medical University of Białystok.

Flow cytometric analysis. Between 7.30 and 8.30 a.m. fasting peripheral venous blood samples were obtained in collection tubes containing ethylenediaminetetraacetic acid stored at room temperature for no longer than 2 hours before staining and CD phenotyping. A complete blood cell count, including an automated differential count, was performed used Coulter MAXM® counter. Briefly, 100 µL of whole blood was stained with 10 µL of the following three-colour monoclonal antibodies directly conjugated to activated peridinin-chlorophyll-protein complex (PerCP) and fluorescein isothiocyanate (FITC) or phycoerythrin (PE): CD4-PerCP, CD8-PerCP, CD62L-FITC, CD54-PE. After incubation at room temperature for 20 minutes, the samples were then processed with a 35-second cycle on a rapid no-wash whole blood lysis work station (Beckman Coulter). A minimum of 10⁴ cells were analyzed by Cytomics FC 500 flow cytometer (Beckman Culter). The peripheral blood lymphocytes were gated by forward-scattering and side-wa-scattering characteristics. The percentage of CD4⁺PerCP lymphocytes expressing CD54⁺PE and CD62L⁺FITC and then the percentage of CD8⁺PerCP lymphocytes expressing CD54⁺PE and CD62L⁺FITC were analyzed and calculated by the software. For each mAb isotype, specific negative control was used. The percentage of positive cells was determined by setting the lower limit over the non-specific fluorescence with suitable controls.

TSHRab analysis. All the sera were kept frozen at -70°C until used. The levels of serum TSH receptor antibodies (TSHRab) were determined by the second-generation radioimmuno assay using human recombinant TSH receptor (DYNTest TRAK human, BRAHMS, Berlin, Germany): sensitivity 0.3 IU/l; mean inter-assay precision (VC) 7.0%.

Statistical analysis. The statistical significance was estimated by the Mann-Whitney U-test. Spearman's test was performed to evaluate the relationships between variables. A p value of less than 0.05 was considered statistically significant. All data were performed using Statistica 6.0 (StatSoft®, Tulsa, OK, U.S.A.).

Results

The percentages of T cell subsets in examined groups are shown as median and interquartile ranges (Table 1, Fig. 1 and 2). CD4⁺ and CD8⁺ values are given in Table 1.

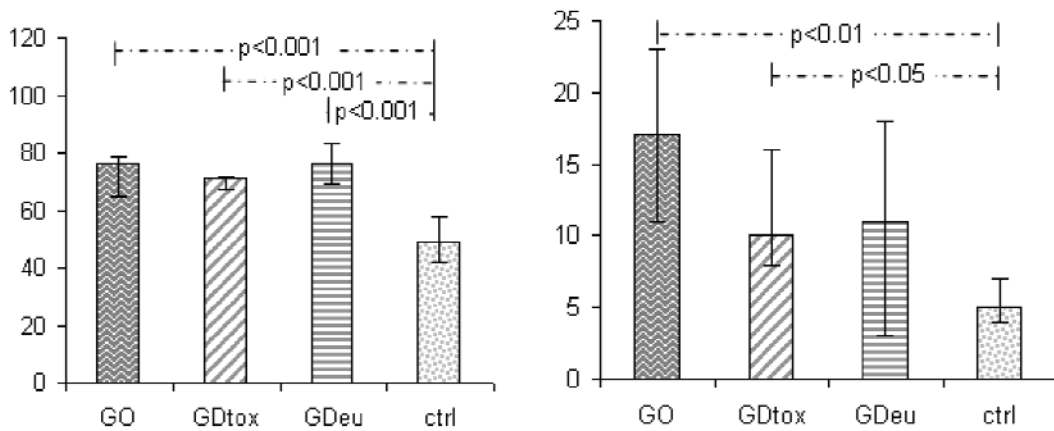


Fig. 1. The median percentage of CD4⁺CD62L⁺ and CD4⁺CD54⁺ T lymphocytes in patients with Graves' ophthalmopathy (GO), hyperthyroid Graves' disease (GDtox), euthyroid Graves' disease (GDeu) compared to controls (ctrl), (whiskers display the interquartile range).

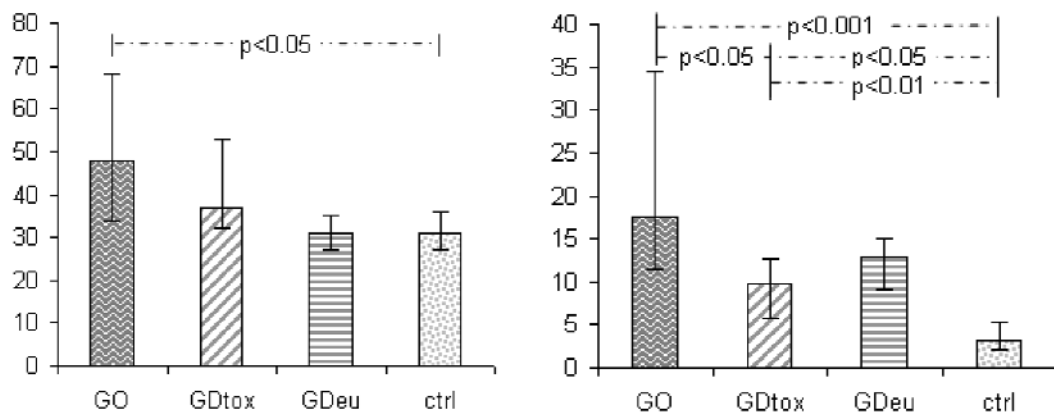


Fig. 2. The median percentage of CD8⁺CD62L⁺ and CD8⁺CD54⁺ T lymphocytes in patients with Graves' ophthalmopathy (GO), hyperthyroid Graves' disease (GDtox), euthyroid Graves' disease (GDeu) compared to controls (ctrl), (whiskers display the interquartile range).

The median percentage of CD4⁺CD62L⁺ T lymphocytes (Fig. 1) was significantly higher ($p < 0.001$) in all studied groups as compared to controls (49.0 (42.5-58.5)): in GO patients 76.2 (64.7-78.7), in hyperthyroid GD 71.0 (67.2-71.9) and in euthyroid GD 76.0 (69.0-83.1).

We found the median percentage of CD4⁺CD54⁺ T lymphocytes (Fig. 1) significantly higher in GO patients ($p < 0.01$) 17.0 (11.2-23.5) and in hyperthyroid GD ($p < 0.05$) 10.0 (8.3-16.0) as compared to controls 5.1 (3.8-6.6). In euthyroid GD patients the median percentage of CD4⁺CD54⁺ T cells was 11.2 (2.6-18.5).

The median percentage of CD8⁺CD62L⁺ T lymphocytes (Fig. 2) was significantly higher ($p < 0.05$) in the GO group 48.5 (34.5-68.2) as compared to controls 31.0 (27.5-36.5). The median CD8⁺CD62L⁺ T lymphocytes' percentage in the hyperthyroid GD was 37.0 (32.0-53.0) and in the euthyroid GD was 31.0 (27.4-34.9).

We found the median percentage of CD8⁺CD54⁺ T lymphocytes (Fig. 2) significantly elevated in GO

patients ($p < 0.001$) 17.5 (11.3-33.7), in hyperthyroid GD ($p < 0.05$) 9.7 (6.1-13.0) and in euthyroid GD ($p < 0.01$) 13.0 (8.4-14.7) as compared to controls 3.2 (2.1-5.1). The significant difference in the median percentage of CD8⁺CD54⁺ T lymphocytes was also observed between the GO group and hyperthyroid GD patients.

We found positive correlation between TSHRab concentration and the percentage of CD8⁺CD62L⁺ T lymphocytes in all studied groups ($r = 0.39$, $p < 0.05$) (Fig. 3) and between TSHRab level and CAS ($r = 0.77$, $p < 0.05$) (data not shown).

Discussion

In previous reports the elevated levels of serum ICAM-1 and L-selectin were demonstrated in patients with Graves' disease and GO [10,13,14]. Moreover the analysis of CD62L⁺ and CD54⁺ antigen expression on peripheral mononuclear cells revealed increased percentages of L-selectin and ICAM-1 positive cells in patients with GD before methimazole therapy [15].

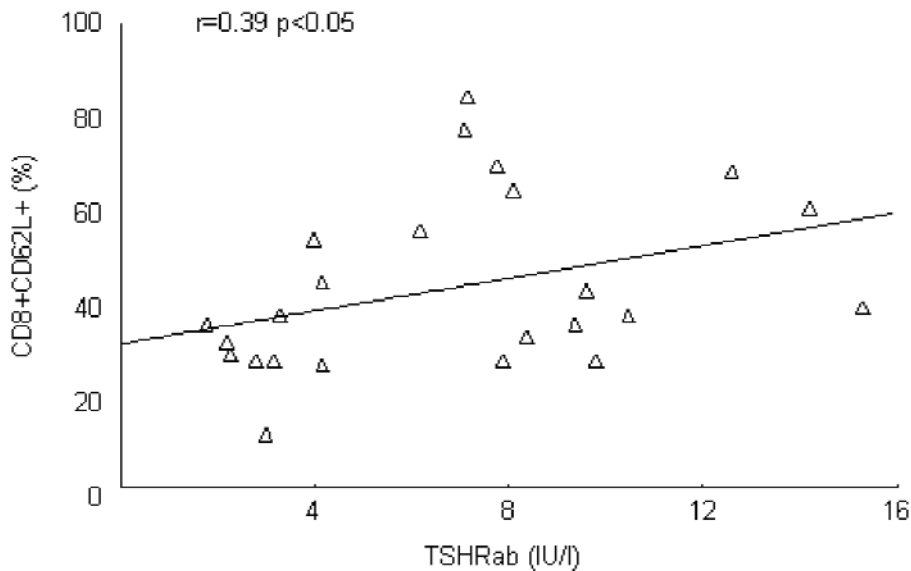


Fig. 3. The positive correlation between TSHRab concentration and the percentage of CD8⁺CD62L⁺ T lymphocytes in all studied groups ($r=0.39$, $p<0.05$)

Consistently with these findings we demonstrated the increased percentage of CD4⁺CD62L⁺ T lymphocytes both in patients with GD and GO. The elevated serum concentration and enhanced expression on cell surface can result from increased shedding of CD62L molecule from activated CD4⁺ T cells and in the consequence reflect the ongoing immune process [10]. Although the percentage of CD4⁺ T cells was only significantly higher in patients with hyperthyroid GD the percentage of its subset expressing ICAM-1 was considerably increased in GO group. In agreement with that, the subset of CD4⁺ T cells was found to predominate in the orbit infiltration in GO [16,17]. After antigen recognition, CD4⁺ T lymphocytes could secrete cytokines that amplify the immune reaction by either activating CD8⁺ T lymphocytes or autoantibody-producing B cells [18]. Th1 cell-mediated immune response seem to play an important role in the early GO [19]. In a recent study the percentage of CD4⁺ T lymphocytes was higher and the percentage of CD8⁺ T cells was lower in both groups of patients with GD and GO [19]. Our data suggest that the immune reaction in early GO is probably unique and different from that in GD without ophthalmopathy (especially with thyrotoxicosis). Although there is no difference in the percentage of CD8⁺ in patients with GO vs. control there are considerable shifts in the subpopulations of CD8⁺ T cells expressing L-selectin and ICAM-1 molecules. The elevated percentage of these subsets may reflect the T cell activation into cellular immune response [18]. The significantly higher percentage of CD8⁺CD54⁺ T lymphocytes in patients with GO (not only vs. control but also vs. hyperthyroid GD) proves evidence for this notion.

In GO ICAM-1 is thought to play a key role in lymphocyte infiltration into the orbit and ICAM-1

antibody produced a concentration dependent inhibition of the IL-1 alpha-induced adhesion of peripheral blood mononuclear cells to the orbital fibroblasts [20]. ICAM-1 serum level was positively correlated to Clinical Activity Score and was established to be a good parameter of disease activity in progressive infiltrative GO [9,13]. An assessment of soluble forms of both ICAM-1 and L-selectin were found helpful as prognostic for immunotherapeutic efficacy during treatment with corticosteroids [10,21]. De Bellis *et al.* demonstrated that serial determinations of ICAM-1 serum levels could help to identify the subgroup of GD patients prone to develop severe clinical ophthalmopathy with retroocular connective inflammation [13]. More recently Wakelkamp *et al.* found that the major determinant of soluble ICAM-1 level in GO patients is the severity of their eye disease [14]. Our data suggest that the evaluation of the percentage of CD8⁺CD54⁺ and CD8⁺CD62L⁺ T lymphocytes in patients with GO could help to identify those GD patients who prone to develop active inflammatory ophthalmopathy and need intensive treatment for GO. The positive correlation of the percentage of CD8⁺CD62L⁺ T lymphocytes and TSHRab seem to confirm a role of these autoreactive cells in the autoimmune process in GO.

In conclusion, the increased percentage of CD8⁺CD54⁺ and CD8⁺CD62L⁺ T cells in patients with Graves' ophthalmopathy may be used as a marker of immune inflammation activity. Assessment of CD4⁺CD62L⁺ peripheral blood cells can not discriminate patients with GO though it may become a good parameter of ongoing autoimmune process in patients with Graves with and without ophthalmopathy. Nevertheless, since the limitation of the study, our data need further analysis on larger populations.

References

- [1] Boulou PR, Hardy I. Thyroid-associated orbitopathy: a clinicopathological and therapeutic review. *Curr Opin Ophthalmology*. 2004;15:389-400.
- [2] Kazim M, Goldberg RA, Smith TJ. Insights into the pathogenesis of thyroid associated orbitopathy. *Arch Ophthalmology*. 2002;120:380-386.
- [3] Bartalena L, Wiersunga WM, Pinchera A. Graves' ophthalmopathy: state of the art and perspectives. *J Endocrinol Invest*. 2004;27:295-301.
- [4] Wakelkamp IM, Bakker O, Baldeschi L, Wiersinga WM, Prummel MF. TSH-R expression and cytokine profile in orbital tissue of active vs inactive Graves's ophthalmopathy patients. *Clin Endocrinol (Oxf)*. 2003;58:280-287.
- [5] Bahn RS. Thyrotropin receptor expression in Orbital Adipose/Connective Tissues from Patients with Thyroid-Associated Ophthalmopathy. *Thyroid*. 2002;12:193-195.
- [6] Heufelder AE. Pathogenesis of ophthalmopathy in autoimmune thyroid disease. *Rev Endocr Metab Disord*. 2000;1:87-95.
- [7] Yan SX, Wang Y. Inhibitory effects of Triptolide on interferon-gamma-induced human leucocyte antigen-DR, intercellular adhesion molecule-1, CD40 expression on retro-ocular fibroblasts derived from patients with Graves' ophthalmopathy. *Clin Experimental Ophthalmology*. 2006;34:265-71.
- [8] Pappa A, Calder V, Ajjan R, et al. Adhesion molecules expression in vivo on extraocular muscles (EOM) in thyroid-associated ophthalmopathy (GO). *Clin Experimental Immunol*. 1997;108:309-313.
- [9] Kulig G, Pilarzka K, Kulig J, Krzyzanowska-Swiniarska B, Andrysiak-Mamos E, Robaczyk M. Magnetic resonance imaging and soluble forms of adhesion molecules: sICAM and sVCAM in assessing the activity of thyroid orbitopathy. *Pol Arch Med Wewn*. 2004;111:161-9.
- [10] Mysliwiec J, Kretowski A, Szelachowska M, Topolska J, Mikita A, Kinalska I. Serum L-selectin and ICAM-1 in patients with Graves' ophthalmopathy during treatment with corticosteroids. *Immunol Letters*. 2001;78:123-126.
- [11] Kretowski A, Wawrusiewicz N, Mironczuk K, Mysliwiec J, Kretowska M, Kinalska I. Intercellular adhesion molecule 1 gene polymorphisms in Graves' disease. *J Clin Endocrinol Metab*. 2003;88:4945-9.
- [12] Wiersinga WM, Perros P, Kahaly GJ, et al. Clinical assessment of patients with Graves' Orbitopathy: The European Group on Graves' Orbitopathy (EUGOGO) recommendations to generalists, specialists and clinical researchers. *Eur J Endocrinol*. 2006;155:207-2011.
- [13] De Bellis A, Di Martino S, Fiordelisi F, et al. Soluble intercellular adhesion molecule-1 (sICAM-1) concentrations in Graves's disease patients followed up for development of ophthalmopathy. *J Clin Endocrinol Metab*. 1998;83:1222-5.
- [14] Wakelkamp IM, Gerding MN, van der Meer JW, Prummel MF, Wiersinga WM. Smoking and disease severity are independent determinants of serum adhesion molecule levels in Graves' ophthalmopathy. *Clin Exp Immunol*. 2002;127:316-20.
- [15] Bossowski A, Urban M, Stasiak-Barmuta A, Turowski D. Expression of Very Late Antigen-4 and Lymphocyte Function-Associated Antigen-1 on Peripheral Blood Lymphocytes from Patients with Graves Disease. *Pediatr Res*. 2002;52:533-7.
- [16] Pappa A, Lawson JM, Calder V, Fells P, Lightman S. T cells and fibroblasts in affected extraocular muscles in early and late thyroid associated ophthalmopathy. *Br J Ophthalmol*. 2000;84:517-522.
- [17] Foerster G, Otto E, Hansen C, Ochs K, Kahaly G. Analysis of orbital T cells in thyroid-associated ophthalmopathy. *Clin Exp Immunol*. 1998;112:427-434.
- [18] Aniszewski JP, Valyasevi RW, Bahn RS. Relationship between disease duration and predominant orbital T cell subset in Graves's ophthalmopathy. *J Clin Endocrinol Metab*. 2000;85:776-780.
- [19] Xia N, Zhou S, Liang Y et al. CD4⁺ T cells and the Th1/Th2 imbalance are implicated in the pathogenesis of Graves' ophthalmopathy. *Int J Mol Med*. 2006;17:911-6.
- [20] Liu GQ, Wu ZY, Yang HS, Zheng JL, Lin Z. The inhibition effect of interleukin-1 alpha-induced intercellular adhesion molecule-1 expression on orbital fibroblasts and adhesion of peripheral blood mononuclear cells. *Zhonghua Yan Ke Za Zhi*. 2003;39:528-32.
- [21] Modelska-Ziolkiewicz A, Gembicki M, Bednarek J, Sowinski J. Prognostic role of adhesion molecules sELAM-1 and sICAM-1 in glucocorticoid therapy of active ophthalmopathy. *Pol Arch Med Wewn*. 2003;109:469-75.

Submitted: 28 January, 2008

Accepted after reviews: 15 July, 2008