

CASE REPORT / OLGU SUNUMU

**A case of primary gastric choriocarcinoma and a review of the Turkish literature:
An extremely rare carcinoma of the stomach*****Bir primer mide koryokarsinomu olgusu ve Türk literatürünün gözden geçirilmesi: Midenin
çok nadir görülen bir kanseri*****Cüneyt Kırkıl¹, Koray Karabulut¹, Erhan Aygen¹, Yavuz Selim İlhan¹, Mesut Yur¹,
İbrahim Hanifi Özercan²**¹Fırat University, Medical School, Department of General Surgery, Elazığ, Turkey²Fırat University, Medical School, Department of Pathology, Elazığ, Turkey

Geliş Tarihi / Received: 23.07.2011, Kabul Tarihi / Accepted: 23.12.2011

ABSTRACT

Primary choriocarcinoma of the stomach is an extremely rare and highly malignant tumor. A 60 years old man visited another hospital for the chief complaint of the stomachache and black stools. A large ulcero-vegetative tumor occupying the gastric body and antrum was seen in the upper gastrointestinal endoscopy. It was diagnosed as gastric adenocarcinoma by endoscopic biopsy. The patient admitted to our hospital for treatment. The patient was assessed as a gastric adenocarcinoma complicated with hemorrhage. In the exploration, it was observed that the mass arising from gastric body was invaded the transverse colon and pancreas. The lymphadenopathies in the celiac axis were conglomerated and had invaded the celiac vessels. A subtotal gastrectomy and an extended right hemicolectomy were performed for palliation. In pathological findings, typical characteristics of two cell pattern consisting of syncytiotrophoblasts and cytotrophoblasts were observed. The tumor consisted of only choriocarcinoma. For the definite diagnosis of choriocarcinoma, immunohistochemical tests were performed. Beta-HCG and EMA staining were positive. The patient was invited for control because of gastric choriocarcinoma three weeks later surgery. His serum beta-HCG level was 458 mIU/mL (normal range, <0.5 mIU/mL). For the differentiation from the primary choriocarcinoma in the testis or mediastinum, testicular ultrasonography and chest CT were performed. Abnormal findings were not detected in the tests, so it was diagnosed as primary gastric choriocarcinoma. The patient refused chemotherapy. Three months later, he had inguinal lymphadenopathies and multiple metastases in lung. He died 5 months after surgery because of respiratory failure.

Key words: Choriocarcinoma, stomach, metastasis.**ÖZET**

Primer mide koryokarsinomu son derece nadir ve yüksek derecede malign bir tümördür. 60 yaşında bir erkek, mide ağrısı ve siyah dışkılama şikayetleri ile başka bir hastaneye başvurmuştu. Üst gastrointestinal endoskopide mide korpusu ve antrumu dolduran ülserovejetan büyük bir tümör görülmüştü. Endoskopik biyopsi ile mide adenokarsinomu tanısı konulmuştu. Hasta tedavi için hastanemize kabul edildi. Kanama ile komplike olmuş mide adenokarsinomu olarak değerlendirildi. Cerrahi gözlemde mide korpusundan kaynaklanan kitlenin transvers kolon ve pankreasa invaze olduğu görüldü. Çölyak aksta konglomere lenfadenopatiler vardı ve çölyak damarları invaze etmiş idi. Palyasyon için subtotal gastrektomi ve genişletilmiş sağ hemikolektomi yapıldı. Patolojik incelemede sitotrofoblastlar ve sinsityotrofoblastlardan oluşan iki hücre paterninin tipik özellikleri görüldü. Tümör sadece koryokarsinomdan ibaretti. Koryokarsinom kesin tanısı için immünohistokimyasal testler yapıldı. Beta-HCG ve EMA boyama pozitif. Hasta ameliyattan 3 hafta sonra mide koryokarsinomu tanısı nedeniyle kontrole çağrıldı. Serum beta-HCG düzeyi 458 mIU/mL idi (normal aralık, <0.5 mIU/mL). Testis veya mediastendeki primer bir koryokarsinomu ayırt etmek için testis ultrasonografisi ve göğüs tomografisi yapıldı. Testlerde anormal bulgu saptanmadı ve böylece primer mide koryokarsinomu tanısı kondu. Hasta kemoterapiyi reddetti. Üç ay sonra inguinal bölgede lenfadenopatileri ve çok sayıda akciğer metastazları vardı. Cerrahiden 5 ay sonra solunum yetmezliği nedeniyle öldü.

Anahtar kelimeler: Koryokarsinom, mide, metastaz.**Yazışma Adresi /Correspondence:** Dr. Mesut YurFırat Üniversitesi Hastanesi Genel Cerrahi A.D.23119 Elazığ, Türkiye Email: mesutyur@hotmail.com
Copyright © Dicle Tıp Dergisi 2012, Her hakkı saklıdır / All rights reserved

INTRODUCTION

Choriocarcinoma is a beta-human chorionic gonadotropin (beta-HCG) secreting, fast-growing and widely metastatic malignant tumor that develops from trophoblastic or totipotential germ cells. Almost all choriocarcinomas form in the uterus after fertilization and arise from chorionic villi in association with normal or abnormal gestation.¹ However, it may also occur without associated gestation. Non-gestational choriocarcinoma primarily occurs in the gonads as ovary or testis.^{2,3} Non-gestational forms may also occur as primarily in the extra-gonadal sites, such as mediastinum, liver, gall bladder, urinary bladder, prostate and gastrointestinal system.⁴ Primary choriocarcinoma of the stomach is extremely rare, and most such cases are not diagnosed correctly before operation.⁵ We report a case of primary gastric choriocarcinoma (PGC) diagnosed as gastric adenocarcinoma initially, and diagnosed as PGC by surgery.

CASE

A 60 years old man visited another hospital for the chief complaint of the stomachache and black stools. A large ulcerovegetative tumor occupying the gastric body and antrum accompanied by areas of hemorrhage and necrosis was seen in the upper gastrointestinal endoscopy. It was diagnosed as gastric adenocarcinoma by endoscopic biopsy. The patient admitted to our hospital for treatment.

He had been suffering for 4 months from epigastric pain and for a week from black stool. He had lost approximately 10 kg in body weight. He had not any significant medical history. The family history was negative for familial or hereditary disease. On examination, the patient was pale because of severe anemia, and had an ill-defined immobile epigastric mass, approximately 8 cm by 15 cm in size. Supraclavicular, axillary and inguinal lymph nodes were not palpable. There was not any mass in the rectal digital examination, but there was mealena. Initial laboratory study results were normal, except for hemoglobin, at 8.6 g/dl, and a hematocrit of 25.9 per cent. Computed tomography (CT) of the abdomen demonstrated a large necrotic tumor filled the 2 to 3 of stomach, and multiple lymphadenopathies with necrotic areas in the celiac axis (Figure 1). As to tumor markers, serum carcinoembryonic antigen (CEA), alpha-fetoprotein (AFP), and carbohydrate antigen (CA) 19-9 levels were within normal limits.

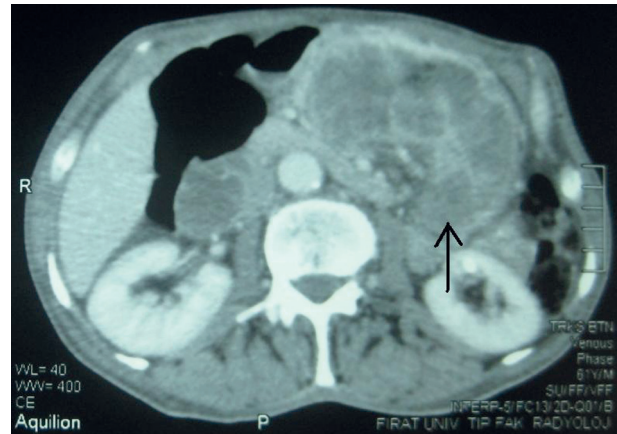

Figure 1. Computed tomography cross-section of a large necrotic tumor filled gastric body.

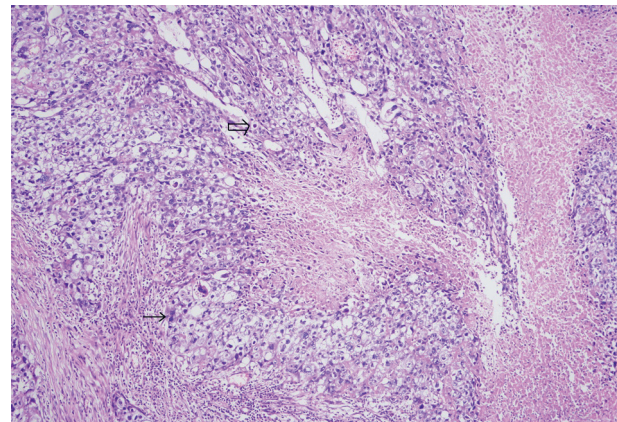


Figure 2. The microscopic appearance of the two cell pattern consisting of syncytiotrophoblasts and cytotrophoblasts and the wide necrotic areas in choriocarcinoma (hematoxylen-eosin staining, x200 magnification).

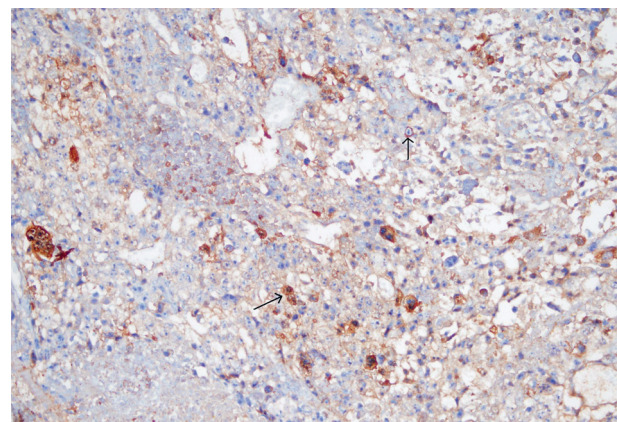


Figure 3. The microscopic appearance of the syncytial cells showed positive immunoreactivity for beta-human chorionic gonadotropin (x200 magnification)

The patient was assessed as a gastric adenocarcinoma complicated with hemorrhage. The gastric resection and lymph node dissection were decided for surgical treatment. In the exploration by midline incision, it was observed that the mass arising from gastric body was invaded the transverse colon and pancreas. And the lymphadenopathies in the celiac axis were conglomerated, and had invaded the celiac vessels. A subtotal gastrectomy and an extended right hemicolectomy were performed for palliation. Polya gastrojejunostomy and ileotransversostomy were preferred for reconstructions. There was no operation-related mortality or morbidity.

In pathological findings, tumor size was 12x10x4 cm and typical characteristics of two-cell pattern consisting of syncytiotrophoblasts and cytotrophoblasts were observed all of the sections (Figure 2). The tumor consisted of only choriocar-

cinoma, there was not adenocarcinoma component. For the definite diagnosis of choriocarcinoma, immunohistochemical test was performed. Beta-HCG and EMA staining were positive, AFP staining was negative (Figure 3). The patient was invited for control because of gastric choriocarcinoma three weeks later surgery. His serum beta-HCG level was 458 mIU/mL (normal range, <0.5 mIU/mL). For the differentiation from the primary choriocarcinoma in the testis or mediastinum, testicular ultrasonography and chest CT were performed. Abnormal findings were not detected in the tests, so it was diagnosed as PGC. The patient was advised a chemotherapy regimen but he refused chemotherapy. Three months later, he had inguinal lymphadenopathies and multiple metastases in lung. He died 5 months after surgery because of respiratory failure.

Table 1. Demographics and characteristics of the patients reported in Turkey

Author(s)	Coskun et al.	Bayhan et al.	Gursoy et al.	Deniz et al.	Present
Year	1998	2000	2000	2006	2010
Age	37	26	38	44	60
Sex	Female	Female	Female	Male	Male
Endoscopic biopsy	Choriocarcinoma	Not taken	Choriocarcinoma	Adenocarcinoma	Adenocarcinoma
Location	Antrum	Great curvature	Antrum	Antrum	Corpus and antrum
Depth (involved organ)	NA	UM	NA	T2	T4 (colon and pancreas)
Surgery	-	Tumor resection	-	Total gastrectomy + Omentectomy	Subtotal gastrectomy + Extended right hemicolectomy
Indication	NA	Bleeding	NA	UM	Bleeding
Residual tumor classification	NA	UM	NA	R2	R2
Size	UM	3x2x1 cm	UM	3x2 cm	12x10x4 cm
Pure or mixed	Pure (having only Endoscopic biopsies)	UM	UM	2/3 chorio + 1/3 adeno	Pure
Lymph node	+	UM	UM	+	+
Metastases	Liver	Lung (postop)	Liver	Liver	Lung (postop)
Chemotherapy	Unknown regimen	Methotrexate + Dactinomycin + Cyclophosphamide	Methotrexate + Etoposid	Unknown regimen	-
Prognosis	UM	18 months, disease free	12 days, death	4 months, death	5 months, death
Cause of death	UM	NA	Bleeding, DIC, Hepatic insufficiency	UM	Respiratory failure

UM: unmentioned; NA: not allowed

PRIMARY GASTRIC CHORIOCARCINOMA CASES REPORTED FROM TURKEY

To date, four cases with PGCs apart from the present case had been reported in Turkey. The table summarizes the characteristics and demographics of the patients. Three articles had published in English, one in Turkish.⁶⁻⁹ The data about these patients was not comparable and there were a lot of lost data, as survival, the indications and the techniques of surgery. Three patients had liver metastases at the time of initial diagnosis. Two of them underwent liver biopsy as well as endoscopic biopsy, and they truly diagnosed. Having only endoscopic biopsies, the authors thought that they were pure choriocarcinomas. The remaining patient underwent only endoscopic biopsy and misdiagnosed as adenocarcinoma. Three patients underwent surgery. Two of them died within 5 months; only one patient lived disease free for 18 months after surgery. Four patients had chemotherapy but one of them died because of bleeding into the mass followed by disseminated intravascular coagulation and hepatic insufficiency at the 12th day of chemotherapy.

DISCUSSION

Primary gastric choriocarcinoma is a rare tumor that is reported to account for approximately 0.08% of all gastric cancers.¹⁰ The number of PGC cases reported in international medical literature (as a PubMed based literature screening) has not yet reached to one hundred and fifty. The clinicopathology and prognostic factors of PGC is not clear, because most studies reported to date are the case reports or small series. However, Kobayashi et al reported that male/female ratio was 2.3:1, median age was 63 years, and most frequently location was the lower third of the stomach in a pooled analysis of 53 patients with PGC. The mean tumor size was 7 cm and nearly all the tumors were accompanied by macroscopic hemorrhage or necrosis. Seventy per cent of patients had PGCs that exhibited an adenocarcinoma component.¹⁰ The presented patient who had 60 years old man was consistent with the literature and had a necrotic large tumor.

Several theories regarding the pathogenesis of gastric choriocarcinoma have been presumed. According to the most accepted view known as retrodifferentiation theory, the trophoblastic elements present

in primary gastric choriocarcinoma are differentiated from malignant adenomatous tissue. By 30% of the reported cases were pure choriocarcinomas and some authors proposed that this might be the result of complete replacement of gastric adenocarcinoma by choriocarcinoma or metaplasia of gastric adenocarcinoma to choriocarcinoma. The most cases of PGCs are not diagnosed correctly before operation because of the coexistence of adenocarcinoma and choriocarcinoma. The rates of correctly diagnosed PGCs by endoscopic biopsies were between 8% and 15%. Similarly, our patient had misdiagnosed as adenocarcinoma after endoscopic biopsy. In fact, there was no adenocarcinoma component in this case. It recommended that clinicians should take more biopsy specimens when encountering large and hemorrhagic tumors, in order to correctly diagnose the gastric choriocarcinoma.⁵ Kobayashi et al reported that most patients with Primary gastric choriocarcinoma had metastatic lesions at the time of operation. The rates of lymph node, liver, peritoneal, and lung metastases were 87%, 45%, 23%, and 8%, respectively. The percentage of patients with a choriocarcinoma component in the liver was 96%.¹⁰ It means that the choriocarcinoma component of the tumor was more capable to metastasis into the liver than adenocarcinoma component. So, it may explain why the accurate diagnosis more possible in patients with liver metastases underwent biopsy. In our case, the patient hadn't got any metastases at the presentation. But, the lung metastases were occurred 3 months later. The most of patients with PGCs were died at 6 months after surgery.¹⁰ Our patient also died 5 months later than surgery because of respiratory failure. However, Noguchi et al reported a patient had live for 4 years and 6 months after gastrectomy followed by chemotherapy.⁵ The most frequent cause of death in patients with PGCs was hepatic failure because of tumor metastasis, and the cancerous hemorrhage was the next. The synchronous liver metastasis, residual tumor after surgery, and the absence of chemotherapy were significant prognostic parameters of a short overall survival.¹⁰ For the treatment of gastric choriocarcinoma, chemotherapy engaging methotrexate, actinomycin D, etoposide, folinic acid, vincristin, cyclophosphamide, etc. is the main therapy, and as supplement, surgery or radiation therapy is administered. Kobayashi et al discussed that the presence of synchronous liver metastasis at the time of op-

eration might represent an advanced metastatic state and might be associated with a poor clinical course in PGC patients.¹⁰ They suggested that a palliative gastrectomy should never be performed in such patients, as it is likely that the patients would die soon after such a procedure. On the contrary, Yoon et al advocated that such a treatment should be considered for the treatment of choriocarcinomas causing gastrointestinal bleeding.¹¹

In conclusion, preoperative diagnosis of PGC is difficult. Physicians must be careful and should take more biopsy specimens when they encounters with a old patient has large necrotic and hemorrhagic tumor on the stomach.

REFERENCES

1. Berkowitz RS, Im SS, Bernstein MR, Goldstein DP. Gestational trophoblastic disease. Subsequent pregnancy outcome, including repeat molar pregnancy. *J Reprod Med* 1998;43(1):81-6.
2. Gerbie MV, Brewer JI, Tamimi H. Primary choriocarcinoma of the ovary. *Obstet Gynecol* 1975;46(6):720-3.
3. Schill H, Arborio M, Gros P, Gripari JL. Pathologic anatomy of tumors of the testis. *Arch Anat Cytol Pathol* 1992;40(4):195-201.
4. Liu Z, Mira JL, Cruz-Caudillo JC. Primary gastric choriocarcinoma: a case report and review of the literature. *Arch Pathol Lab Med* 2001;125(12):1601-4.
5. Noguchi T, Takeno S, Sato T, Takahashi Y, Uchida Y, Yokoyama S. A patient with primary gastric choriocarcinoma who received a correct preoperative diagnosis and achieved prolonged surgery. *Gastric Cancer* 2002;5(2):112-7.
6. Coskun M, Agildere AM, Boyvat F, Tarhan C, Niron EA. Primary choriocarcinoma of the stomach and pancreas: CT findings. *Eur Radiol* 1998;8(8):1425-8.
7. Gursoy M, Gur G, Ustundag Y, Demirhan B, Baysal C, Boyacioglu S. Primary gastric choriocarcinoma: A case report and review of the literature. *Turk J Gastroenterol* 2000;11(1):34-8.
8. Bayhan G, Yaldiz M, Yalinkaya A, Kilinc N, Gul T, Erden AC. Primary gastric choriocarcinoma: case report. *Eur J Gynaecol Oncol* 2000;21(3):316-7.
9. Deniz K, Taşdemir A, Patıroğlu TE. Primer gastrik koryokarsinom: Olgu sunumu. *Türk Patoloji Dergisi* 2006;22(3):192-5.
10. Kobayashi A, Hasebe T, Endo Y, et al. Primary gastric choriocarcinoma: two case reports and a pooled analysis of 53 cases. *Gastric Cancer*. 2005;8(3):178-185.
11. Yoon JH, Kim MS, Kook EH, et al. Primary gastric choriocarcinoma: Two case report and review of the literatures. *Cancer Res Treat* 2008;40(3):145-50