



## SUCCESS FOR REMOVING OR BYPASSING INSTRUMENTS FRACTURED BEYOND THE ROOT CANAL CURVE – 45 CLINICAL CASES.

Kalin K. Shiyakov, Radosveta I. Vasileva,  
*Department of Conservative Dentistry, Faculty of Dental Medicine, Medical University - Sofia, Bulgaria*

### SUMMARY:

The **aim** of the study is to compare success rates for ultrasonic removal or bypassing endodontic instruments, fractured below the curve of root canals.

**Methods:** 45 clinical cases – 30 MB and 5 ML root canals of mandibular molars, as well as 8 MB, 2 DB root canals of maxillary molars were selected from the authors' private practice. 18 of the fragments are stainless steel files, 6 are rotary Ni-Ti files and 21 – lentulos. Fragments, to which visual access could be achieved by safe straightening of the root canal (26) were treated ultrasonically under dental microscope (OPMI Pico, Carl Zeiss) with magnification 10x and 16x. Bypass is chosen for fragments (19) without visibility.

**Results:** Ultrasonic group: 22 of 26 fragments (84,61%) were totally removed, and full working length was consequently reached in 69,23% of the cases (18 fragments). Four fragments (15,38%) separated additionally from the vibrations and could not be totally ultrasonically removed. Bypass group: only 7 of 19 fragments (36,84%) could be successfully bypassed.

**Conclusions:** Ultrasonic technique for broken instruments removal is significantly more successful than bypassing. Straight visible access to the fragment under dental microscope is crucial for successful fragments retrieval.

**Key words:** Broken, separated instruments retrieval, ultrasonic technique, bypass,

### INTRODUCTION

The presence of a separated instrument in the root canal may lead to a failure of the treatment of the tooth. The prognosis depends on the degree of contamination of the canal at the moment of separation and the presence of apical pathology. When the fragment prevents the necessary instrumentation and decontamination of the root canal, an attempt for its removal should be considered [1, 2, 3].

The operating microscope in endodontics gives opportunities for direct enhanced visualization of separated instruments deep in the root canal, and using fine ultrasonic tips makes it possible to loosen and remove the fragment. The probability of removing a fractured instrument is directly connected to visibility – i.e. possibility to create

straight line access to it. When the fragment is located inside or beyond the root canal's curvature, visibility requires straightening of the root canal to a different extent, which may lead to removing excessive amount of dentin and root weakening or even perforation. That's why such cases require very good assessment of the risk and indications for the procedure [4, 5, 6, 7].

An alternative technique, which historically precedes those for broken instruments removal, is the so called "bypass". Inserting a fine file between the fragment and the root canal wall may lead to negotiating the canal to full working length and enable thorough instrumentation and root canal obturation with the fragment remaining in situ. Incorporating the fragment in the root canal obturation material considerably improves the case prognosis [8]. This technique does not require direct visibility to the fragment – i.e. it can be suitable for when the fragment is located beyond a considerable root canal curvature.

Current information from scientific literature on the subject of broken instruments' retrieval is insufficient and mainly comprises clinical case presentations [9, 10, 11]. There are a few studies comparing different methods and techniques, but using different working protocols [12, 13, 14, 15]. Souter [16] and Ward [17, 18] examine only the ultrasonic technique using fragments with different location in the root canal and report success rates between 33,3% and 95%. Nevares et al [19] in their clinical survey report higher success rates for the ultrasonic technique compared to bypass, using fragments with different locations in relation to the curvature.

The **aim** of the study is to compare success rates between ultrasonic technique and bypass in managing separated instruments located beyond the root canal curvature.

### MATERIALS AND METHODS

Forty five clinical cases from the authors' private practice with separated instruments beyond the root canals curvature were selected for the study. 30 fragments were situated in MB canals of mandibular molars, 5 in ML canals of mandibular molars, 8 in MB and 2 in DB canals of maxillary molars. The 45 fragments include 18 stainless steel files, 6 rotary nickel-titanium files and 21 paste carriers (lentulos) (tables 1 and 2).

**Table 1.**

GROUP	TECHNIQUE	FRAGMENTS Type and numbers	Mandibular molars		Maxillary molars		RESULTS
			MB	ML	MB	DB	
1. achieved visibility to the fragment  26 fragments	ULTRASONICS	Stainless steel 12	7	1	4	–	removed + WL = 10 removed – WL = 0 partially removed = 2 removed + WL = 1 removed – WL = 0 partially removed = 0 removed + WL = 7 removed – WL = 4 partially removed = 2
		Ni-Ti 1	1	–	–	–	
		Paste carriers 3	10	2	1	–	
2. NOT achieved visibility to the fragment 19 fragments	BYPASS	Stainless steel 6	4	1	1	–	successful bypass = 2 Non-successful bypass = 4  successful bypass = 1 Non-successful bypass = 4  successful bypass = 4 Non-successful bypass = 4
		Ni-Ti 5	2	1	1	1	
		Paste carriers 8	5	1	2	–	

**Table 2.**

GROUP	fragments	Mandibular molars		Maxillary molars		RESULTS IN FRAGMENTS	RESULTS IN PERCENTAGES	
		MB	ML	MB	DB			
ULTRA- SONICS	26	18	3	4	1	removed + WL = 18	=69.23%*	84.61%*
						removed – WL = 4	=15.38%*	
						partially removed = 4	=15.38%*	
BYPASS	19	11	3	4	1	successful bypass = 7	=36.84%*	
						Non-successful bypass = 12	=63.15%*	

\* the differences between groups 1 and 2 are statistically significant, chi-square independence test

The ultrasonic technique, described by Ruddle [4, 5, 6, 7] was used. All canals were enlarged to the level of the fragment to ISO number 40, and then with Gates Glidden number 1, 2 and 3. Under magnification 10x and 16x with a dental operating microscope (OPMI Pico, Carl Zeiss) using ultrasonic K-files (EMS) the MB and ML canals of mandibular molars were additionally enlarged in lingual and buccal directions respectively, and MB canals of maxillary molars – towards MB2. Doing that, the curvatures of the canals were partially straightened in the safe areas of the root with the largest amount of dentine present. When visible access to the fragment was achieved, ultrasonic attempt to remove it was undertaken. The following ultrasonic endodontic tips were used – ET25 (Satelec), Redo 2 (VDW) and a prototype instruments, created by our team (diameter at the tip 0.175 mm, active tip and smooth walls). In all cases with lack of visibility of the fragment, because the curvature was too big to be completely safely straightened, bypass was attempted, using C+ files (VDW).

Some fragments from the ultrasonic group separated additionally, the apical part of the fragment remaining dangerously deep beyond the curve – they were also transferred to the bypass group.

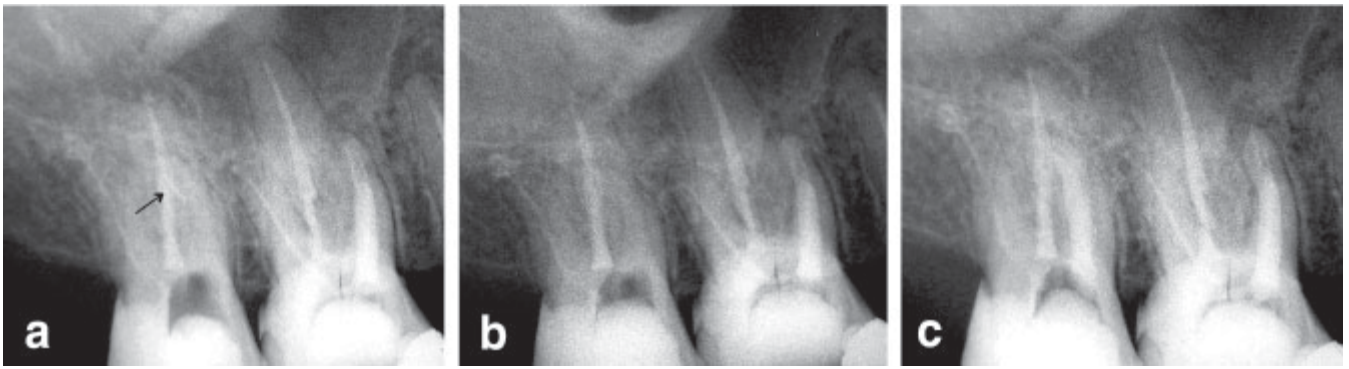
In total 26 fragments were treated ultrasonically, and 19 with bypass.

**RESULTS**

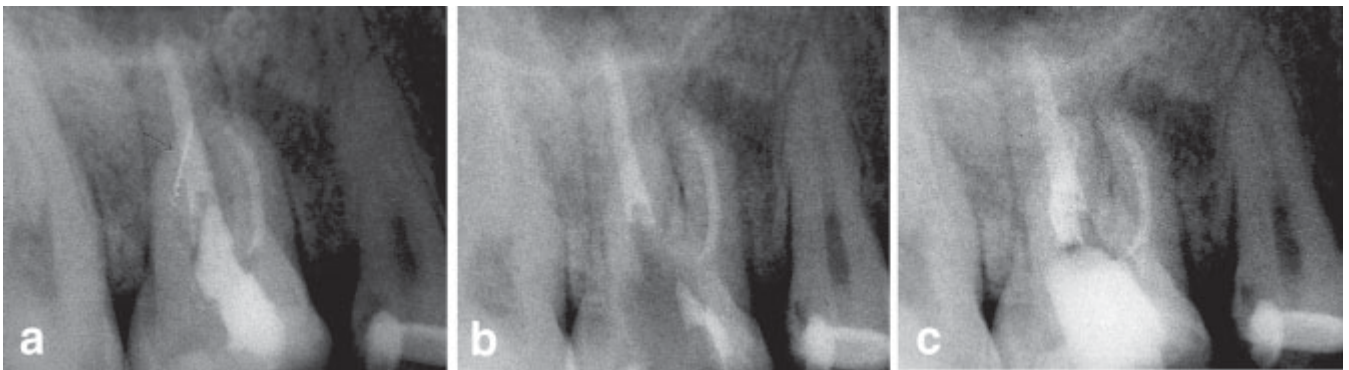
Ultrasonic group: 22 of 26 fragments were completely removed ultrasonically (84.61%), and full working length was achieved after the removal of 18 fragments (69.23%). Four of the 26 fragments separated additionally (15.38%) and the remaining part of the fragment, being too deep beyond the curve, could not be removed (fig. 1 and 2).

Bypass group: successful bypass was achieved in 7 of the 19 cases in the group – 36.84% (fig. 3 and 4).

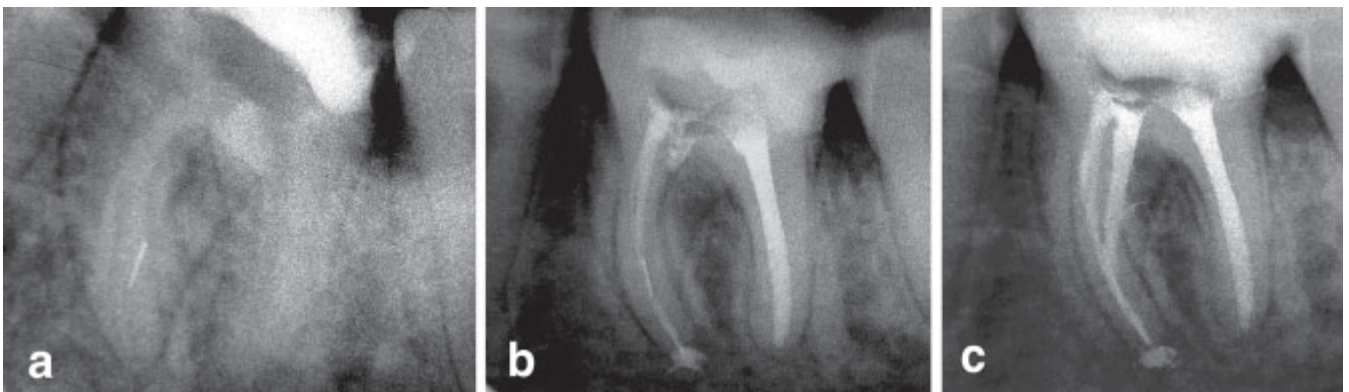
The differences between the groups are statistically significant (chi-square independence test, table 3).



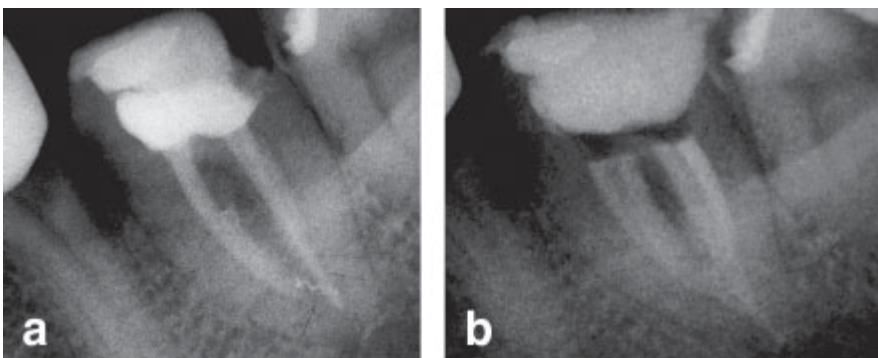
**Fig. 1. a)** a fragment in MB canal of 17; **b)** the fragment removed; **c)** MB canal obturated;



**Fig. 2. a)** a fragment in DB canal of 16; **b)** the fragment removed; **c)** DB canal obturated;



**Fig. 3. a)** a fragment in ML canal of 36; **b)** Successful bypass; **c)** all root canals obturated;



**Fig. 4. a)** a fragment in MB canal of 36; **b)** successful bypass and all canals obturated;

**Table 3.** Chi-square independence test

condition	observed	expected	deviation	
Ultrasonic-successful	18	14.44	0.877673	
Ultrasonic-NOT successful	8	11.55	1.091125	
Bypass-successful	7	10.55	1.194549	
Bypass-NOT successful	12	8.44	1.501611	
Ultrasonic-total	26		<b>chi sq =</b>	<b>4.664958</b>
Bypass-total	19		<b>df =</b>	<b>2</b>
Total successful	25			
Total NOT successful	20		<b>0.0307842</b>	
Grand total	45			

The differences are statistically significant,  $p < 0.05$  ( $p = 0.03078$ )

### DISCUSSION

First we would like to discuss the definition “fragments, located INSIDE the root canals’ curvature”. Hulsman and Schinkel [13], as well as Shen [14] and Ward [17] use radiographs to define the location of the fragment in accordance to the curvature. In the present study we have accepted the idea of Nevares [19] to do this clinically rather than radiographically. According to this idea, fragments, which can be visualized under magnification without necessity of root canal straightening, are located before the curve. All the rest are inside/beyond the curve. In the present study only cases requiring root canal straightening for visibility were included. We think that using radiographs for definition of canal curvatures may lead to mistakes, because of the two-dimensional image. Sometimes on the radiograph separated instruments seem to be situated in the straight portion of the root canal, but clinically they can not be visualized without considerable removal of dentin from the curve of the walls of the root canal. We think this is especially true for the mesial canals of lower molars.

Another important problem to be discussed is the criteria for SUCCESS in the present study, when using ultrasonic technique. We decided to record the complete removal of the fragment, but also recorded reaching full working length. We took this decision, because removing the fragment is not as an end in itself – it is a prerequisite for root canal instrumentation and decontamination. In most of the other studies (except that of Ward, [17] ) working length has not been discussed and it’s reaching probably goes without saying, but we can’t be sure [13, 14, 15, 16]. Reasons for not being able to negotiate the canal to full working length is a matter of vast discussion, and we intend to examine the problem in another study.

The present study is retrospective - the main purpose of the clinical work was to treat the patient successfully, and treatment has not been modified to suit the aim of the study.

Hulsman [13] reports success rates of 58% and 52% when the fragments were located inside and beyond the curve respectively. For the same locations Shen [14] reports

60% and 31%, but in both studies [13, 14] a number of different techniques for instruments removal was used. Suter [15] also used different techniques and concluded that crucial for success was not fragments location, but time, spent in the attempt to remove the fragment. Souter [16] used only ultrasonics and reported significantly higher success rates when fragments were located in the coronal 1/3 portion of the canal, compared to the apical 1/3. Ward [17, 18] also using ultrasonics, discovered a 30% decrease in success when the fragment was located beyond the curve. Nevares [19], comparing ultrasonics and bypass, received 85.3% success with ultrasonics and 47.7% using bypass.

In the present study we found that ultrasonic in the curvature resulted in removal of 84,61% of the fragments, and working length was reached in 69,23% of the cases, which is comparable to the results of other authors, cited above.

Ward [17] claims that bypass is impossible in cases when ultrasonics failed, and our results confirmed that too. Our bypass success rates (36.84%) are similar to those of Nevares (47.7%).

Interesting for us are the four cases (15.38% of the ultrasonic group, tables 1 and 2) in which although the fragment (lentulo) was completely removed, the root canal could not be negotiated to full working length. The reason for that was not connected with the presence of a ledge or some other “ultrasonic complication”, we think the portion of the canal beyond the fragment was calcified and obliterated.

### CONCLUSION

The ultrasonic technique for broken instruments removal systematically shows acceptable clinical success rates when the fragments are located inside the root canal curvature. The possibility for safe straightening of the root canal to achieve visibility to the fragment is a most important factor for the success. Bypass shows significantly lower success rates than ultrasonics, but in cases of lack of visibility to the fragment, it is the only alternative.

### Acknowledgement:

Publication of the article was sponsored by the Publisher of the magazine "Journal of IMAB".



## REFERENCES:

1. Bahcall JK, Carp S, Miner M, Skidmore L. The causes, prevention, and clinical management of broken endodontic rotary files. *Dent Today*. 2005 Nov;24(11):74, 76, 78-80; quiz 80. [PubMed]
2. Crump MC, Natkin E. Relationship of broken root canal instruments to endodontic case prognosis: a clinical investigation. *J Am Dent Assoc*. 1970 Jun;80(6):1341-1347. [PubMed]
3. Grossman LI. Fate of endodontically treated teeth with fractured root canal instruments. *J Br Endod Soc*. 1968 Jul-Sep;2(3):35-37. [PubMed]
4. Ruddle CJ. Nonsurgical retreatment. *J Endod*. 2004 Dec;30(12): 827-845. [PubMed] [CrossRef]
5. Ruddle CJ. Broken instrument removal. The endodontic challenge. *Dent Today*. 2002 Jul;21(7):70-72, 74, 76 pasim. [PubMed]
6. Ruddle CJ. Nonsurgical retreatment. In: Cohen S, Burns RC, eds. *Pathways of the pulp*, 8th ed. St Louis: Mosby; 2002:875-930.
7. Ruddle CJ. Micro-endodontic non-surgical retreatment. *Dent Clin North Am*. 1997 Jul;41(3):429-454. [PubMed]
8. Saunders JL, Eleazer PD, Zhang P, Michalek S. Effect of a separated instrument on bacterial penetration of obturated root canals. *J Endod*. 2004 Mar;30(3):177-179. [PubMed] [CrossRef]
9. D'Arcangelo C, Varvara G, De Fazio P. Broken instrument removal – two cases. *J Endod*. 2000 Jun;26(6):368-370. [PubMed] [CrossRef]
10. Flanders DH. New techniques for removing separated root canal instruments. *NY State Dent J*. 1996 May;62(5):30-32. [PubMed]
11. Rahimi M, Parashos P. A novel technique for the removal of fractured instruments in the apical third of curved root canals. *Int Endod J*. 2009 Mar;42(3):264-270. [PubMed] [CrossRef]
12. Gencoglu N, Helvacioğlu D. Comparison of the different techniques to remove fractured endodontic instruments from root canal systems. *Eur J Dent*. 2009 Apr;3(2):90-5. [PubMed]
13. Hülsmann M, Schinkel I. Influence of several factors on the success or failure of removal of fractured instruments from the root canal. *Endod Dent Traumatol*. 1999 Dec;15(6):252-258. [PubMed]
14. Shen Y, Peng B, Cheung GS. Factors associated with the removal of fractured NiTi instruments from root canal systems. *Oral Surg Oral Med Oral Pathol Oral Radiol Endod*. 2004 Nov;98(5):605-610. [PubMed] [CrossRef]
15. Suter B, Lussi A, Sequeira P. Probability of removing fractured instruments from root canals. *Int Endod J*. 2005 Feb;38(2):112-123. [PubMed] [CrossRef]
16. Souter NG, Messer HH. Complications associated with fractured file removal using an ultrasonic technique. *J Endod*. 2005 Jun;31(6):450-452. [PubMed]
17. Ward JR, Parashos P, Messer HH. Evaluation of an ultrasonic technique to remove fractured rotary nickel-titanium endodontic instruments from root canals: an experimental study. *J Endod*. 2003 Nov;29(11):756-63. [PubMed] [CrossRef]
18. Ward JR, Parashos P, Messer HH. Evaluation of an ultrasonic technique to remove fractured rotary nickel-titanium endodontic instruments from root canals; clinical cases. *J Endod*. 2003 Nov;29(11):764-767. [PubMed] [CrossRef]
19. Nevares G, Cunha RS, Zuolo ML, Bueno CE. Success rates for removing or bypassing fractured instruments: a prospective clinical study. *J Endod*. 2012 Apr;38(4):442-444. [PubMed] [CrossRef]

Please cite this article as: Shiyakov KK, Vasileva RI. SUCCESS FOR REMOVING OR BYPASSING INSTRUMENTS FRACTURED BEYOND THE ROOT CANAL CURVE – 45 clinical cases. *J of IMAB*. 2014 Jul-Sep;20(3):567-571. doi: <http://dx.doi.org/10.5272/jimab.2014203.567>

Received: 25/06/2014; Published online: 19/08/2014



### Address for correspondence:

Dr. Kalin Shiyakov,  
Department of Conservative Dentistry, Faculty of Dental Medicine, Medical University - Sofia  
1, St. Georgi Sofiyski Blvd, 1431 Sofia, Bulgaria  
Mobile phone +359 898 646 592  
E-mail: [kshiyakov@yahoo.com](mailto:kshiyakov@yahoo.com);