

Small Bowel Adenocarcinoma Mimicking a Large Adrenal Tumor

Miomira Ivović^{1,2}, Vladan Živaljević^{1,2}, Svetlana Vujović^{1,2}, Ljiljana Marina^{1,2}, Milina Tančić Gajić^{1,2}, Dušan Dundjerović³, Marija Barac^{1,2}, Dragan Micić^{1,2}

¹Clinic for Endocrinology, Diabetes and Metabolic Diseases, Clinical Center of Serbia, Belgrade, Serbia;

²School of Medicine, University of Belgrade, Belgrade, Serbia;

³Institute for Pathology, School of Medicine, University of Belgrade, Belgrade, Serbia

SUMMARY

Introduction Adenocarcinoma of the small bowel is a rare gastrointestinal neoplasm usually affecting the distal duodenum and proximal jejunum. Because of their rarity and poorly defined abdominal symptoms, a correct diagnosis is often delayed.

Case Outline We present a 43-year-old woman admitted at the Clinic for Endocrinology due to a large tumor (over 7 cm) of the left adrenal gland. The tumor was detected by ultrasound and confirmed by CT scan. The patient complained of abdominal pain in the left upper quadrant, fatigue and septic fever. Normal urinary catecholamines excluded pheochromocytoma. The endocrine evaluations revealed laboratory signs of subclinical hypercorticism: midnight cortisol 235 nmol/L, post 1 mg – overnight Dexamethasone suppression test for cortisol 95.5 nmol/L and basal ACTH 4.2 pg/mL. Plasma rennin activity and aldosterone were within the normal range. Surgery was performed. Intraoperative findings showed signs of acute peritonitis and a small ulceration of the jejunum below at 70 cm on the anal side from the Treitz's ligament. Adrenal glands were not enlarged. Pathohistology and immunochemistry identified adenocarcinoma of the jejunum without infiltration of the lymphatic nodules. The extensive jejunal resection and lavage of the peritoneum were performed. Due to complications of massive peritonitis, the patient died seven days after surgery.

Conclusion Poorly defined symptoms and a low incidence make the diagnosis of small bowel carcinoma, particularly of the jejunal region, very difficult in spite of the new endoscopic techniques.

Keywords: small bowel adenocarcinoma; adrenal incidentaloma; peritonitis

INTRODUCTION

Adenocarcinoma of the small bowel is a rare gastrointestinal neoplasm, usually affecting the distal duodenum and proximal jejunum. Because of their rarity and poorly defined abdominal symptoms, a correct diagnosis is often delayed. Peritonitis is one of the frequent complications of the small bowel adenocarcinoma due to ulceration as a first presentation of the disease. Incidentally discovered adrenal masses without prior suspicion of adrenal disease are defined as adrenal incidentaloma. Most of these tumors are hormonally silent.

CASE REPORT

A 43-year-old woman was admitted to the Department of Endocrinology due to a large tumor (over 7 cm) of the left adrenal gland. Three months before admission she experienced fatigue, vomiting and had septic fever, which lasted for five days. After a while, an intense abdominal pain occurred in the left upper quadrant without propagation. Chest X-ray was normal and symptoms resigned after 7 days of oral antibiotic therapy (Amoxicillin capsules 500 mg three times a day). Ultrasound and CT scan were performed. A large tumor,

over 7 cm, was found in the left adrenal gland, with a lot of heterodensity suspicious of primary tumor or metastases also with enlarged para-aortic lymph nodes in a block (density was not measured in Hounsfield units – HU) (Figures 1 and 2). On the day of admission the patient was without pain, vomiting, fever or any bowel movement problems. She denied previous diseases, allergies and surgeries. She was a smoker (about 20 cigarettes per day) for ten years, and without alcohol abuse. The patient had no family history of chronic diseases.

Physical finding was completely normal, with no signs of hypercorticism.

Laboratory findings: hypochromic, microcytic anemia, with reactive thrombocytosis and positive inflammatory syndrome (elevated erythrocyte sedimentation rate/ESR, leukocytosis, with neutrophilia and elevated fibrinogen). Proteinogram showed decreased level of albumin. Hemoculture and urine culture were sterile in several samples. The rest of biochemical analysis were within the normal range, including calcium, phosphorus, vitamin D and stool examination (for occult blood, fat, meat fibers, culture) (Tables 1 and 2). No indirect signs of malabsorption and no signs of hypokalemic alkalosis were found. Normal urinary catecholamines excluded pre-active pheochromocytoma. Endocrine evaluations revealed

Correspondence to:

Miomira IVOVIĆ
Clinic for Endocrinology, Diabetes
and Metabolic Diseases
Clinical Center of Serbia
Dr Subotića 13, 11000 Belgrade
Serbia
imiomira@yahoo.com

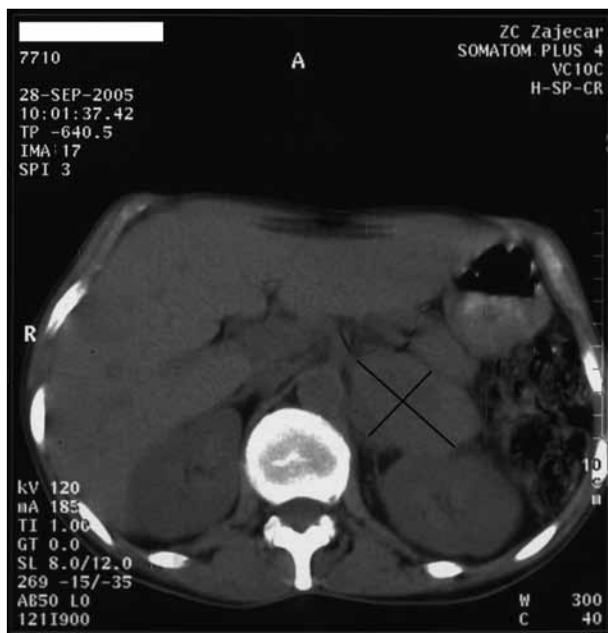


Figure 1. Abdominal CT scan

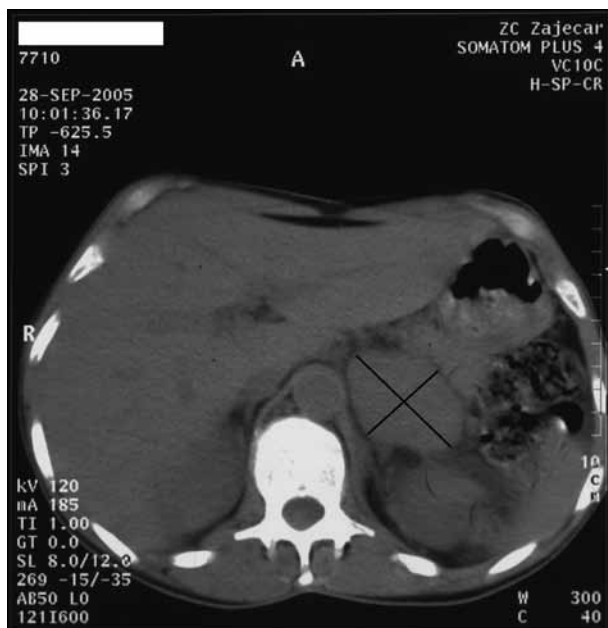


Figure 2. Abdominal CT scan

laboratory signs of subclinical hypercorticism: midnight cortisol 235 nmol/L, post 1 mg – overnight dexamethasone suppression test for cortisol 95.5 nmol/L and basal ACTH 4.2 pg/mL. Plasma renin activity (PRA) and aldosterone (ALD) were within the normal range with PRA/ALD ratio 5.2. The patient was euthyroid.

ECG: sinus tachycardia without other pathological finding. Chest X-ray: no active pathological finding. Abdominal ultrasonography: a large hypoechogenic adrenal tumor 75×55 mm in size with parapancreatic lymphadenopathy. The rest of the findings were normal. Pelvic ultrasound: a microcystic right ovary, size 31×25 mm. Ambulatory blood pressure monitoring (ABPM): lower values of systolic and diastolic blood pressure during the day and night with tachycardia during all day and night

Table 1. Hormone analysis

Hormone	Value	Reference range
TSH (mU/L)	1.2	0.3–5.5
Free T4 (ng/L)	18.2	7–22
PRL (mU/L)	300/397/324	151.5–757.5
FSH (IU/L)	6.6	2.5–15
LH (IU/L)	2.1	4–20
ACTH (ng/L)	4.2	10–90
Cortisol (nmol/l)	8 h 667/ 24 h 238	Morning: 131–642 Evening: 61–429
DHEAS (μmol/L)	0.66	1.9–10.5
Testosterone (nmol/L)	2.0	0.3–3.0
Chromogranin A (ng/ml)	64.4	19.4–98.1
PRA (ng/ml/h)	5.97	1.5–5.7
Aldosterone (ng/L)	312	97–626
PRA/ALD	5.2	
Adrenaline (μg/24 h)	3.2/1.52/1.32	1–6
Noradrenaline (μg/24 h)	19.74/17.95/16.89	10–25
Dopamine (μg/24 h)	120.34/105.8/102.63	100–300
1 mg overnight Dexamethasone test Cortisol (nmol/L)	95.5	<50
Vitamin D (25OHD) (ng/ml)	36	25–80

Table 2. Biochemical blood testing

Laboratory findings	Value		Reference range
	Before operation	After operation	
Red blood cells (10 ¹² /L)	3.64	3.2	3.86–5.08
Hematocrit	0.28	0.25	0.35–0.47
MCV (fL)	79	76	83–97
Hemoglobin (g/l)	97	98	119–157
White blood cells (10 ⁹ /L)	26	20	3.4–10
Neutrophils (%)	85	80	44–72
Platelets (10 ⁹ /L)	544	520	158–424
Fibrinogen (g/L)	5.6	5.8	1.8–3.7
SE (per hour)	80	92	24
Sodium (mmol/L)	140	142	135–148
Potassium (mmol/L)	4.5	4.3	3.5–5.1
Chlorides (mmol/L)	102	103	98–107
Bicarbonates (mmol/L)	26	27	22–32
Calcium (mmol/L)	2.24	2.20	2.15–2.65
Phosphates (mmol/L)	1.15	1.1	0.8–1.55
Alkaline phosphatase (U/L)	81	80	40–120
Cholesterol (mmol/L)	3.87	3.43	3.1–5.2
Triglyceride (mmol/L)	1.98	1.76	Up to 1.7
Albumin (g/L)	30	24	34–55

(day: 109/71 mmHg, 95 bpm, night: 106/68 mmHg, 89 bpm). During hospitalization at our Department she was febrile for most of the days (with body temperature up to 39.7°C in the afternoon – septic fever). We introduced antibiotics in her therapy: Ceftriaxone (2 g intravenously per day) with Gentamicin (80 mg intravenously three times a day). She exhibited no change in appetite or significant weight loss at that time, and had no gastrointestinal problems. After seven days the patient was transferred to the Department of Endocrine Surgery with the following

diagnosis: tumor of the left adrenal gland and febrile state. Except for subclinical hypercortisism, no signs of other tumor secretion were found. Surgery was performed after three weeks while still looking for the reason of the febrile state. During that time the hematologist (bone marrow puncture and blood smear without signs of lymphoproliferative disease), and the infectologist were consulted. Except confirmed positive inflammatory syndrome (elevated ESR, leukocytosis, with neutrophilia and elevated fibrinogen) without positive hemoculture, urinculture or coproculture, nothing else was found. The infectologist's opinion was that febrility was nonspecific due to the tumor presence. Intraoperative findings showed signs of acute peritonitis and small ulceration of the jejunum, at about 70 cm on the anal side from the Treitz ligament. Adrenal glands were not enlarged. Pathohistology and immunohistochemistry (IHC) identified a moderately differentiated adenocarcinoma of the jejunum (Cytokeratin 7 (CK7) +++, Cytokeratin 20 (CK20) +/-, CDX2 +/-, RCC -, Vimentin + (in stromal cells), S100 -, TTF1 -, Synaptophysin -, CD 56 -) (Figures 3, 4 and 5) without infiltration of lymphatic nodules, with purulent peritonitis and also with purulent lymphadenitis. Extensive jejunal resection and lavage of peritoneum were performed (about 2 liters of opalescent liquid was drained). Examination of peritoneal lavage showed mixture of aerobic and anaerobic bacteria with a predominance of *Escherichia coli* and *Clostridia*. After surgery her condition was stable and she was transferred to the Department of Surgery at the Clinic for Digestive Diseases. The patient continued to receive intravenous antibiotics, (Cephtriaxone 2 g per day, Vancomycin 1 g twice daily and Metronidazole 500 mg three times a day). She was afebrile, but with still positive inflammation syndrome. The patient died seven days later, due to chronic extensive peritonitis as a consequence of jejunal ulceration.

DISCUSSION

Together with lymphoma, leiomyosarcoma and carcinoid, adenocarcinomas represent the tumors of the small bowel [1]. However, considering their low incidence (less than 5%) and poorly defined clinical features their diagnoses is often delayed [1, 2, 3]. They make 50% of all malignant small bowel tumors with high incidence in patients with prolonged regional enteritis, celiac disease and acquired deficiency disease. They are usually localized in the distal part of the duodenum and proximal jejunum causing ulceration, hemorrhage and obstruction. In patients with prolonged regional enteritis, adenocarcinomas can be easily mistaken for chronic duodenal ulcer or Crohn's disease (X-ray). The diagnosis is achieved with endoscopic biopsy [8] and surgical resection is the therapy of choice [5, 6, 7, 9]. Our patient denied previous gastrointestinal illnesses. Also she had no symptoms such as sickness, vomiting, bowel movement problems, signs of malabsorption, loss of appetite or weight, thus no previous gastroenterology examination was performed. Adrenal incidentaloma – adrenal tumors previously diagnosed during abdominal

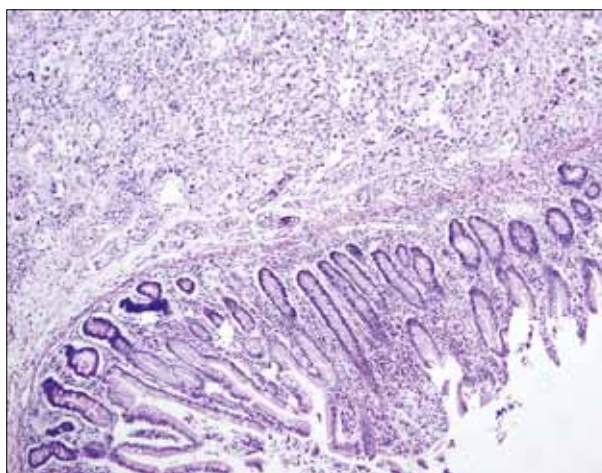


Figure 3. Small intestinal adenocarcinoma (H&E stain, 10x)

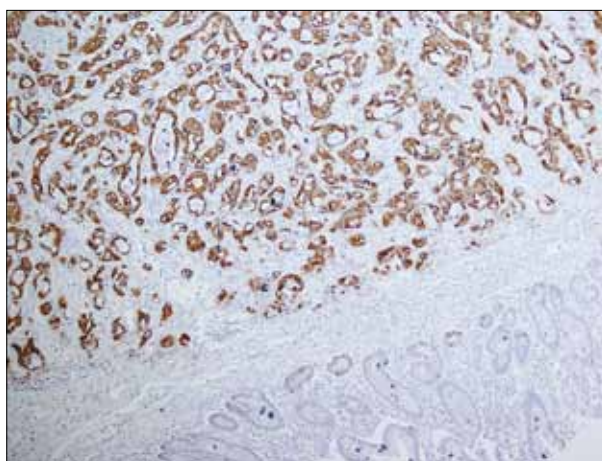


Figure 4. CK7 is diffusely and strongly reactive comparing to non-neoplastic mucosa (10x)

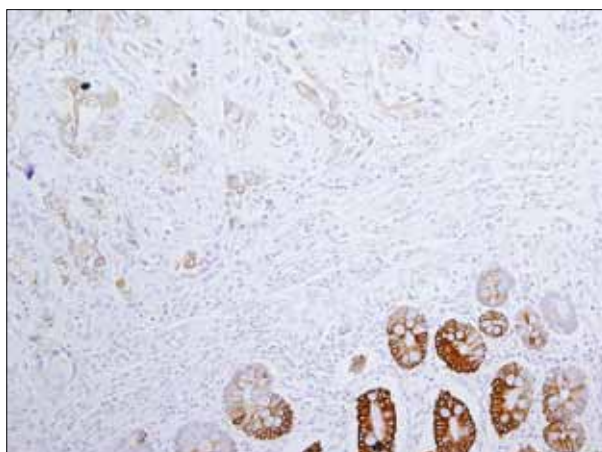


Figure 5. Weak and patchy immunoreactivity of CK 20 in tumor tissue (20x)

imaging procedures without prior suspicion of adrenal disease, today represent a frequent finding and common clinical problem which is still not completely defined [10]. Their prevalence is about 1-5%, depending on the study, and up to 10% in studies from autopsy. Today, CT and MRI as diagnostic tools have a very important role. The CT features, used to distinguish adenomas from nonadenomas, involve the lipid content of the adrenal mass, expressed in

Hounsfield units (HU) [11]. HU characterizes a relative density of substance. The dynamics of the washout of contrast medium is also important [11]. However, one-third of adenomas does not contain large amounts of lipid and may be indistinguishable from nonadenomas on both CT and MRI. Also, 4% of adrenal tumors confirmed by CT later become extrarenal, which happened in our patient. Due to CT findings and ultrasound on admission there was no dilemma, thus CT was not repeated before surgery.

Subclinical Cushing's syndrome can be seen in these patients secreting cortisol in an autonomous and unregulated way that is not fully restrained by pituitary feedback. The term subclinical Cushing's syndrome describes more accurately this condition, not implying any assumption on further development of clinically overt syndrome [12]. These patients meet two criteria defining subclinical Cushing's syndrome. First, the patients should not present as overt Cushing and, second, they should have an adrenal mass detected serendipitously [13]. Preoperatively, our patient met both of these criteria (endocrine testing and adrenal mass detected by ultrasound and CT scan). From this point, after operation, chronic stress caused by peritonitis due to malignancy, febrile state and serious condition of our patient could be a possible explanation for the subclinical hypercorticism.

Peritonitis is presented as an acute or chronic, localized or a diffuse inflammation of peritoneum. Etiology of

peritonitis can be bacterial, chemical, sterile or granulomatous as a reaction to starch in surgical gloves. Bacterial peritonitis occurs due to bacterial entry into the peritoneal cavity after gastrointestinal perforation or external penetrating wound. Our patient had secondary peritonitis due to malignant ulceration and bacterial entry into the peritoneal cavity. Due to poorly defined clinical signs (fever, mild hypotension, tachycardia), ultrasound and CT finding (showing a left adrenal tumor), the proper diagnosis and operation were delayed and excessive antibiotic therapy had no effect. Misdiagnosed adrenal tumor and endocrine testing showing signs of subclinical hypercorticism (probably due to chronic stress, peritonitis, febrile state, serious condition of the patient) steered the diagnoses into the wrong direction. According to the recent studies of small bowel adenocarcinoma patients, the most frequent symptoms are abdominal pain and peritonitis, which was the case in our patient. Poorly defined symptoms and low incidence make the diagnosis very difficult, in spite of new endoscopic techniques.

NOTE

This work was supported by the Ministry of Education, Science and Technological Development of the Republic of Serbia (grant number 175067).

REFERENCES

- Mayer RJ. Tumors of the large and small intestine. In: Harrison TR, Wilson JD, Braunwald E, Isselbacher KJ, Petersdorf RG, Martin JB, Fauci AS, Root RK, editors. Principles of Internal Medicine. 16th ed. New York: McGraw-Hill Inc. Health Professions Division; 2005. p.593-4.
- Silen W. Acute appendicitis and peritonitis. In: Harrison TR, Wilson JD, Braunwald E, Isselbacher KJ, Petersdorf RG, Martin JB, Fauci AS, Root RK, editors. Principles of Internal Medicine. 16th ed. New York: McGraw-Hill Inc. Health Professions Division; 2005. p.1807-8.
- Delaunoy T, Neczyporenko F, Limburg PJ, Erlichman C. Pathogenesis and risk factors of small bowel adenocarcinoma: a colorectal cancer sibling? *Am J Gastroenterol.* 2005; 100(3):703-10.
- Soeda J, Sekka T, Hasegawa S, Ishizu K, Ito E, Saguti T, et al. A case of primary small intestinal cancer diagnosed by laparoscopy. *Tokai J Exp Clin Med.* 2004; 29(4):159-62.
- Zhan J, Xia ZS, Zhong YQ, Zhang SN, Wang LY, Shu H, et al. Clinical analysis of primary small intestinal disease: a report of 309 cases. *World J Gastroenterol.* 2004; 10(17):2585-7.
- Dabaja BS, Suki D, Pro B, Bonnen M, Ajani J. Adenocarcinoma of the small bowel: presentation, prognostic factors, and outcome of 217 patients. *Cancer.* 2004; 101(3):518-26.
- Urbanczyk K, Limon J, Korobowicz E, Chosia M, Sygut J, Karcz D, et al. Gastrointestinal stromal tumors. A multicenter experience. *Pol J Pathol.* 2005; 56(2):51-61.
- Friedrich-Rust M, Ell C. Early-stage small-bowel adenocarcinoma: a review of local endoscopic therapy. *Endoscopy* 2005; 37(8):755-9.
- Caruso S, Marrelli D, Pedrazzani C, Neri A, Mazzei MA, Onorati M, et al. A rare case of primary small bowel adenocarcinoma with intussusception. *Tumori.* 2010; 96(2):355-7.
- Linos D. Adrenal incidentaloma (adrenaloma). *Hormones.* 2003; 2(1):12-21.
- Young WF Jr. The incidentally discovered adrenal mass. *N Engl J Med.* 2007; 356:601-10.
- Grumbach MM, Biller BMK, Braunstein GD, Campbell KK, Carney JA, Godley PA, et al. Management of the clinically unapparent adrenal mass (incidentaloma). *Ann Intern Med.* 2003; 138:424-9.
- Terzolo M, Bovio S, Reimondo G, Pia A, Osella G, Borretta G, et al. Subclinical Cushing's syndrome in adrenal incidentalomas. *Endocrinol Metab Clin North Am.* 2005; 34:423-39.

Од инциденталом надбубрега до аденокарцинома танког црева

Миомира Ивовић^{1,2}, Владан Живаљевић^{1,2}, Светлана Вујовић^{1,2}, Љиљана Марина^{1,2}, Милина Танчић Гајић^{1,2}, Душан Дунђеровић³, Марија Бараћ^{1,2}, Драган Мицић^{1,2}

¹Клиника за ендокринологију, дијабетес и болести метаболизма, Клинички центар Србије, Београд, Србија;

²Медицински факултет, Универзитет у Београд, Београд, Србија;

³Институт за патологију, Медицински факултет, Универзитет у Београду, Београд, Србија

КРАТАК САДРЖАЈ

Увод Аденокарциноми танког црева су ретки гастроинтестинални малигни тумори (до 5%) ове локализације, а нејасна клиничка слика је често разлог што се откривају у одмаклом стадијуму.

Приказ болесника Жена стара 43 године примљена је у Клинику за ендокринологију, дијабетес и болести метаболизма КЦС ради ендокринолошког испитивања због тумора леве надбубрежне жлезде потврђеног ултразвуком и компјутеризованом томографијом. Тегобе су почеле три месеца пре пријема у болницу повраћањем и високом температуром (до 39°C) и трајале пет дана. Ендокринолошким испитивањем је искључен феохромоцитом и потврђена очувана минералнокортикоидна функција. Лабораторијски налази су говорили у прилог супклиничком хиперкортицизму: ниво поноћног кортизола био је 238,2 nmol/l, а АСТН 4,2 pg/ml, уз делимичну супресију кортизола после теста преконоћне супресије дексаметазоном (1 mg) од 95,5 nmol/l. Током

хируршког лечења уочени су знаци акутног гнојног перитонитиса, а на јејунуму перфорација пречника мањег од 5 mm, на 70 cm од почетка танког црева (од *Lig. Treitz*). Надбубрежне жлезде нису биле измењене. Патохистолошки и имунохистохемијски налаз је потврдио средње диференциран аденокарцином јејунума, без инфилтрације лимфних жлезда. Урађене су екстензивна ресекција јејунума и лаважа перитонеума, али услед компликација масивног акутног перитонитиса, болесница је умрла седмог дана од операције.

Закључак Сви досадашњи радови указују на тешкоће раног постављања дијагнозе примарног карцинома танког црева узимајући у обзир њихову инциденцију јављања, нарочито у пределу јејунума. Нејасни симптоми и нејасна клиничка слика значајно успоравају и одлажу време постављања дијагнозе упркос данашњим најновијим ендоскопским техникама.

Кључне речи: аденокарцином танког црева; инциденталом надбубрега; перитонитис

Примљен • Received: 13/04/2011

Ревизија • Revision: 02/04/2012

Прихваћен • Accepted: 11/03/2013