



Celiac disease diagnosed after uncomplicated pregnancy in a patient with history of bulimia nervosa

Celijačna bolest dijagnostikovana posle nekomplikovane trudnoće kod bolesnice sa anamnezom bulimije nerveze

Nemanja Milisavljević, Mirjana Cvetković, Goran Nikolić, Branka Filipović,
Nikola Milinić

Department of Gastroenterohepatology, Clinical and Hospital Center “Bežanijska kosa”, Belgrade, Serbia

Abstract

Introduction. The association between celiac disease and eating disorders has been very rarely reported. This is the first report on celiac disease associated with bulimia in this part of Europe. **Case report.** An adult female patient with history of bulimia and one uncomplicated pregnancy was admitted to the Gastroenterology Department, due to long lasting dyspeptic symptoms, constipation, major weight loss and fatigue. After positive serological screening, the diagnosis of celiac disease was confirmed with histopathology examination of duodenal biopsy specimen. **Conclusion.** Complicated interactions between celiac disease and bulimia can make them difficult to diagnose and treat. It is important to consider the presence of celiac disease in patients with bulimia and gastrointestinal symptoms.

Key words:
celiac disease; eating disorders; pregnancy; diagnosis.

Apstrakt

Uvod. Udruženost celijačne bolesti i poremećaja ishrane je retko opisivana u literaturi. Ovo je prvi prikaz bulimije udružene sa celijačnom bolešću u ovom delu Evrope. **Prikaz bolesnika.** Odrasla bolesnica sa bulimijom i jednom nekomplikovanom trudnoćom primljena je u Odeljenje za gastroenterologiju zbog tegoba kao što su dugotrajna dispepsija, konstipacija, gubitak telesne mase i malaksalost. Nakon pozitivnog serološkog skrininga, dijagnoza celijačne bolesti potvrđena je histopatološkim pregledom biopata mukoze duodenuma. **Zaključak.** Komplikovani odnosi između celijakije i bulimije mogu ih učiniti teškim za dijagnostikovanje i lečenje. Važno je razmotriti postojanje celijačne bolesti kod bolesnika sa bulimijom i gastrointestinalnim simptomima.

Ključne reči:
celijakija; apetit, poremećaji; trudnoća; dijagnoza.

Introduction

Celiac disease is an inflammatory condition of the small intestinal mucosa induced by gluten consumption in genetically susceptible individuals, leading to the spectrum of gastrointestinal manifestation. Previously, celiac disease was thought to be a disease of infancy, manifesting during the first years of life as the malabsorption syndrome with chronic diarrhea, abdominal distension, and failure to thrive. In the recent years it became increasingly evident that celiac disease can affect individuals of any age. Because of the variety of ways celiac disease can manifest itself in adults, it is often not still diagnosed. Psychiatric symptoms and disorders are commonly found in association with celiac disease^{1,2}. Most reports concern the association between celiac disease and anxiety, irrita-

bility and depression³. The association between celiac disease and eating disorders has been rarely reported in the literature⁴. Most of the case reports describe onset of anorexia nervosa in patients with already diagnosed celiac disease after the introduction of gluten free diet⁵.

We presented an adult patient with celiac disease and history of bulimia nervosa, in who celiac disease had been diagnosed after pregnancy.

Case report

A 27-year-old woman with a history of bulimia and one uncomplicated pregnancy was admitted to the Gastroenterology Department in 2010 due to long lasting dyspeptic symptoms, constipation, weight loss and fatigue. During

childhood the patient suffered from mild underweight, nocturnal enuresis, and occult spina bifida. The patient had a late onset of menarche at the age of 15, followed by irregular, painful periods. Also, the patient had never been treated for infertility. Family history was negative for celiac disease or eating disorders. The patient's eating difficulties started in 2002, when she started binge eating and gained 10 kg in body weight (Figure 1 a). Then the patient started to use diet products, trained excessively for a few months and vomited and binge eating 3 to 4 times a week for the next 7 years in order to lose weight (Figure 1 a), fulfilling all the criteria of the Diagnostic and Statistical Manual (DSM-IV) for bulimia. Also, in 2002 the patient complained on dyspeptic symptoms and received *Helicobacter pylori* eradication therapy. As her dyspeptic symptoms had persisted she underwent upper gastrointestinal endoscopy which was normal findings. Celiac disease was not suspected as her duodenal mucosa had normal macroscopic appearance. Because of a long-lasting constipation in 2006 underwent colonoscopy and small bowel barium follow through test, which were both normal. In 2009, the patient got pregnant for the first time in her life and in the first trimester of pregnancy stopped her bulimic behavior. Routine pregnancy laboratory tests were within normal range. Pregnancy and childbirth were uncomplicated. During the next 12 months, prior to admission to hospital, the patient lost nearly 21 kg in weight (Figure 1 b) and experienced severe dyspeptic symptoms. Both weight loss and dyspeptic symptoms had begun soon after childbirth. The patient had not bulimic symptoms after pregnancy. Both psychiatrist and psychologist suspected a hidden bulimia relapse. Family history was negative for celiac disease or eating disorder.

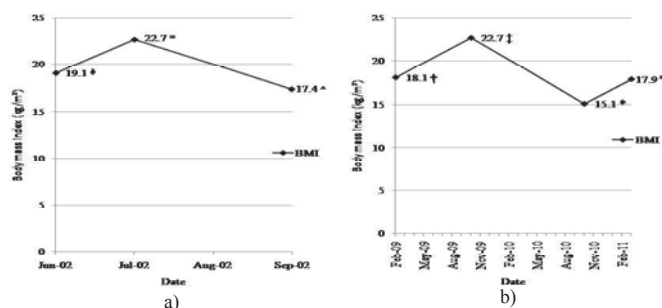


Fig. 1 – Body mass index (BMI) variations: a) before onset of bulimia^Φ, during binge phase^Ω, during purge phase[^]; b) at the beginning[†] and at the end of pregnancy[‡], at hospital admission^{*}, and six months after introduction of gluten free diet^{///}

Physical examination at admission revealed cachexia.

Routine laboratory tests were within normal range. According to the standardized rating scale for eating disorders – the Bulimic Investigatory Test Edinburgh (BITE)⁶, the patient was in remission from bulimia. Bioimpedance analysis revealed a low level of body mass index (BMI) (15.1 kg/m²) and total body fat (TBF) (8.6%). The screening serology test for celiac disease – IgA anti-transglutaminase antibodies was performed which were highly elevated – 425.61 RU/mL (< 20

RU/mL). Upper gastrointestinal endoscopy revealed atrophic macroscopic appearance in duodenum (Figure 2). Histopathology examination of duodenal biopsy specimen revealed type IIIb lesions according to the Marsh-Oberhuber classification. Osteodensitometry displayed a normal bone mineral density.

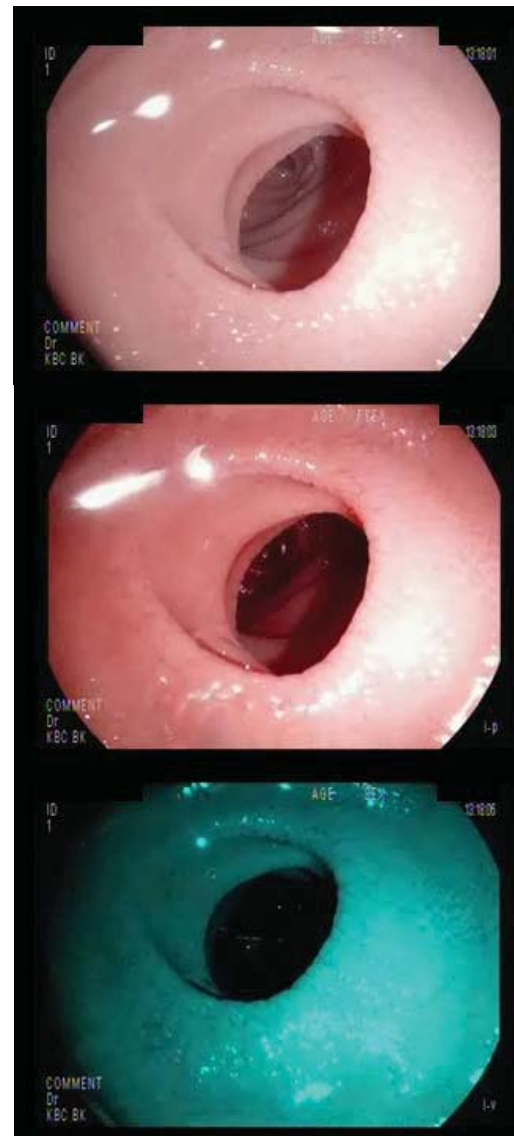

Fig. 2 – Endoscopic appearance of atrophic duodenal mucosa (with and without i-scan surface enhancement)

After diagnosing celiac disease, the patient was recommended to undergo strict life-long gluten free diet, and underwent cognitive behavioural psychotherapy performed by the psychologist for 20 weeks in order to prevent possible bulimia relapse. She was recommended to use paroxetine in combination with psychotherapy.

During 6-month follow-up the BMI of the patient improved (Figure 1 b) and IgA anti-transglutaminase antibodies were only slightly elevated (32.4 RU/mL). According to BITE, the patient had not relapsed into bulimia during the follow-up period.

Discussion

This paper presented an adult patient with celiac disease and previous history of bulimia nervosa and one uncomplicated pregnancy. To the best of our knowledge, this is the first case of celiac disease associated with an eating disorder in this part of Europe. According to the available sources, only 2 similar case reports,^{1,2} and one case series⁴ have been reported so far. There is a strong clinical evidence for suspecting celiac disease early in our patient.

Celiac disease is an inflammatory condition of the small intestinal mucosa that is induced by ingestion of gluten in genetically susceptible individuals, leading to spectrum of gastrointestinal manifestations. It is one of the most common genetically conferred disorders reaching the prevalence of 1% in overall population. Many patients remained undiagnosed, either because of misdiagnosed, asymptomatic, latent, silent or potential celiac disease. It is known that a high proportion of adults with celiac disease has a prior history of psychiatric disorder even for years^{3,7}. Also, it is known that undiagnosed celiac disease can lead to infertility in women. Bulimia nervosa is characterized by episodes of binge eating (uncontrolled consumption of a large amount of food in a relatively short period of time) followed by an inappropriate "compensation" such as forced vomiting, laxative or diuretic abuse, a subsequent fast or period of food restriction, or excessive exercising⁸.

The mechanisms involved in the pathogenesis of psychiatric disorders related to celiac disease are not well understood. Malabsorption of tryptophan, folic acid, and vitamin B6, known to occur in celiac disease, may lead to disturbances in brain serotonin function⁹. Decreased serotonin

activity in the brain is associated with enhanced appetite, and thus may be related to bulimia¹⁰. Adult celiac patients taking a gluten-free diet showed an increase in the concentrations of serotonin metabolites in cerebrospinal fluid¹¹. On the other hand, treatment-induced weight gain can act as a risk factor for altered eating behavior¹². Studies evaluating the course of bulimia during pregnancy have reported an improvement in bulimic symptoms and a return to prepregnancy symptom levels or even a worsening of symptoms in the postpartum period^{13,14}. A reason for improvement of bulimic symptoms during pregnancy may be found in the significant increase of serotonin concentration in the brain through pregnancy¹⁵. Pregnancy and delivery can trigger celiac disease in susceptible people for reasons that are not well-understood.

A long history of nonspecific gastrointestinal symptoms and low body weight, described in our patient, were neglected by physicians in the presence of bulimia and uncomplicated pregnancy. Furthermore, worsening of symptoms after pregnancy was mistakenly attributed to a hidden bulimia relapse.

Conclusion

Complicated interaction between celiac disease and bulimia can make the patient difficult both to diagnose and treat. It is important to consider the presence of celiac disease in patients with bulimia and gastrointestinal symptoms. Serological testing for celiac disease in patients with eating disorders may be useful. Further studies are needed to determine the true nature of the relationship between celiac disease and eating disorders, particularly bulimia.

R E F E R E N C E S

1. Yucel B, Ozbey N, Demir K, Polat A, Yager J. Eating disorders and celiac disease: a case report. *Int J Eat Disord* 2006; 39(6):530-2.
2. Jost PJ, Stengel SM, Huber W, Sarbia M, Peschel C, Duxyster J. Very severe iron-deficiency anemia in a patient with celiac disease and bulimia nervosa: a case report. *Int J Hematol* 2005; 82(4): 310-1.
3. Addolorato G, Leggio L, D'Angelo C, Mirijello A, Ferrulli A, Cardone S, et al. Affective and psychiatric disorders in celiac disease. *Dig Dis* 2008; 26(2): 140-8.
4. Leffler DA, Dennis M, Edwards George JB, Kelly CP. The interaction between eating disorders and celiac disease: an exploration of 10 cases. *Eur J Gastroenterol Hepatol* 2007; 19(3): 251-5.
5. Ricca V, Mannucci E, Calabro A, Bernardo MD, Cabras PL, Rotella CM. Anorexia nervosa and celiac disease: two case reports. *Int J Eat Disord* 2000; 27(1):119-22.
6. Henderson M, Freeman CP. A self-rating scale for bulimia. The 'BITE'. *Br J Psychiatry* 1987; 150: 18-24.
7. Pynnönen PA, Isometsä ET, Aronen ET, Verkasalo MA, Savilabti E, Aalberg VA. Mental disorders in adolescents with celiac disease. *Psychosomatics* 2004; 45(4): 325-35.
8. American Psychiatric Association. *Diagnostic and Statistical Manual of Mental Disorders. DSM-IV*. 4th ed. Washington, DC: Amazon; 1994.
9. Pynnönen PA, Isometsä ET, Verkasalo MA, Savilabti E, Aalberg VA. Untreated celiac disease and development of mental disorders in children and adolescents. *Psychosomatics* 2002; 43(4): 331-4.
10. Jimerson DC, Wolfe BE, Metzger ED, Finkelstein DM, Cooper TB, Levine JM. Decreased serotonin function in bulimia nervosa. *Arch Gen Psychiatry* 1997; 54(6): 529-34.
11. Hallert C, Sedvall G. Improvement in central monoamine metabolism in adult coeliac patients starting a gluten-free diet. *Psychol Med* 1983; 13(2): 267-71.
12. Karvautz A, Wagner G, Berger G, Sinnreich U, Grylls V, Huber WD. Eating pathology in adolescents with celiac disease. *Psychosomatics* 2008; 49(5): 399-406.
13. Crow SJ, Keel PK, Thuras P, Mitchell JE. Bulimia symptoms and other risk behaviors during pregnancy in women with bulimia nervosa. *Int J Eat Disord* 2004; 36(2): 220-3.
14. Morgan JF, Lacey JH, Sedgwick PM. Impact of pregnancy on bulimia nervosa. *Br J Psychiatry* 1999; 174: 135-40.
15. Uluitu M, Duşleag L, Constantinescu D, Petcu G, Catrinescu G, Pană S. Serotonin through pregnancy. Comparative researches in different species and in mankind. *Physiologie* 1975; 12(4): 275-80.

Received on June 6, 2011.

Revised on July 28, 2011.

Accepted on August 5, 2011.