

## PERCEPTION OF Er-YAG LASER DENTAL CARIES TREATMENT IN ADOLESCENTS - A CLINICAL EVALUATION

Galia G. Zhegova<sup>1</sup>, Maya R. Rashkova<sup>1</sup>, Bozhidar I. Yordanov<sup>2</sup>

1) Department of Pediatric Dentistry,

2) Department of Prosthetic Dentistry,

Faculty of Dental Medicine, Medical University- Sofia

### ABSTRACT

The **aim** of this study was to evaluate adolescents' acceptance and pain perception of Er-YAG laser preparation in comparison to conventional mechanical preparation.

**Material and methods:** Forty four adolescents between the age of 16 and 18 years with bilateral matched pairs of carious permanent molars participated in this study. In each patient one of the 2 cavities was prepared conventionally, the other with the Er-YAG laser. All cavities were restored with light-cured composite resin following the application of acid etch and a bonding agent. The patients were instructed to rate pain (sensitivity) during treatment according to visual analogue scale and to decide which method they would prefer for their future caries treatment.

**Results:** The patients rated lower pain perception during laser treatment. It was found that 86.36 % of the adolescents indicated that they would prefer the Er:YAG laser preparation for further caries treatment.

**Conclusion:** The application of the Er-YAG laser for carious tissue removal, compared to conventional mechanical preparation, is perceived as more comfortable and the adolescents prefer it for a future treatment.

**Key Words:** Er-YAG Laser, Cavity Preparation, Pain Perception, Adolescents

### INTRODUCTION:

Fear of pain is the main reason for many people not seeking dental care [1]. Conventional mechanical cutting and drilling systems for removal of decayed tooth tissue are efficient but uncomfortable because of the vibration and loud noises that make the patients anxious.

The potential of Er-YAG laser for the ablation of hard dental structures was demonstrated in 1989 [2]. Since its first introduction for dental use in 1992, Er-YAG lasers have been increasingly used in dental practice and are becoming quite a comfortable method for patients undergoing dental caries treatment [3].

Er-YAG laser radiation matches the absorption peak of water and its minimal penetration depth into enamel and dentine (5  $\mu\text{m}$  - 7  $\mu\text{m}$ ) leads to concentration of energy only to a superficial layer (4  $\mu\text{m}$  - 5  $\mu\text{m}$ ) of the exposed structures, as a large amount of this laser energy is consumed for the process of ablation, and only a minimum part re-

mains for the controlled heating of tissues [4, 5, 6, 7]. Thus, Er-YAG laser hard dental structures interaction can result in an efficient ablation of enamel and dentin with minimal changes on adjacent structures and without adverse effects on dental pulp [4, 7]. A maximum temperature in the pulp chamber during Er-YAG laser irradiation of enamel and dentin with suitable water-cooling does not exceed 3° - 4° C, therefore dental manipulations can be described as safe and secure [4, 8].

The Er-YAG laser application gives the opportunity of observing the rules for dental caries treatment with minimal intervention [9]. Non contact method for carious hard dental structure removal induces less vibration and assures a painless and more comfortable treatment.

All properties mentioned above, make the Er-YAG laser system completely suitable for pediatric dentistry [7, 10].

### AIM

The aim of this study was to evaluate adolescents' acceptance and pain perception of Er-YAG laser preparation in comparison to conventional mechanical preparation.

### MATERIAL AND METHODS

#### Selection of patients

Forty four adolescents (18 male and 26 female) between the age of 16 and 18 years with a total of 88 carious lesions participated in this study.

Informed written consent was obtained for the procedure of laser and conventional treatment from each patient's parents, as required by the institution's ethics board. All the procedures were conducted in accordance with the guidelines established by the Bulgarian Ministry of Health's Code of Bioethics for Dentists and the Helsinki Declaration.

The benefits and possible side effects, such as popping sounds and the smell associated with ablation, had been fully explained.

The children presented bilateral matched pairs of carious Class I and / or Class II permanent molars. The cavities were matched according to cavity type (occlusal or proximal) and cavity depth (less than or more than half way through dentine).

**Table 1.** Distribution of carious lesions according to the treatment method

Treatment method	Er-YAG Laser	Conventional techniques	Total
Localization	n <sub>1</sub>	n <sub>1</sub>	n
Occlusal	24	24	48
Proximal	20	20	40
Total	44	44	88

All teeth were clinically free of any pathological condition different from dental caries.

#### Clinical design

A split mouth design of cavity preparation with an Erbium-YAG laser was used, compared to conventional dental handpieces. Cavity preparation was performed by one and the same dentist on two first or second permanent molars in each patient. One of the 2 cavities was prepared conventionally, the other with the Er-YAG laser.

For laser preparation, an Er-YAG laser (Lite Touch™, Syneron, Israel), that is a solid-state crystal laser with the host crystal-yttrium aluminium garnet doped with erbium ions that replace the yttrium ions, was used. Parameters applied were as follows: energy ranging from 100 mJ to 400 mJ, pulse repetition rate: 20 Hz, sapphire tip diameter: 1.3 mm, 1.0 mm, pulse duration: 50 μsec, theoretical fluence: 15.05- 22.61 J/cm<sup>2</sup> for the dentin, 30.15- 22.61 J/cm<sup>2</sup> for the enamel and 12.74 J/cm<sup>2</sup> for preparing bevels on cavity margins, non-contact mode distance: 0.5 to 1.0 mm, air-water-spray cooling: 39 ml/min.

Cavities prepared by mechanical means involved the use of burs in high-speed and low-speed water-cooled handpieces.

The cavities were completed at two separate appointments, on different days.

No local anaesthetic was used either before or during the treatment.


The preparation was carried out under visual control according to Björndal with intermittent testing of the remaining hard structure hardness by means of a dental probe [11].

All cavities were restored with light-cured composite resin (Kalore GC) following acid etching and application of bonding agent (3M ESPE Scotchbond Multipurpose).

#### Evaluation of pain

Immediately after laser and mechanical treatment, each patient was instructed to rate pain (sensitivity) during treatment according to visual analogue scale (VAS) from 0 to 100 points (Figure 1).

**Fig. 1.** The visual analogue scale used for pain perception



Using this scale six degrees of pain can be described: code 0 - no pain, code 1 - slight discomfort to bearable pain (0-10 points), code 2- mild pain (20-40 point), code 3- moderate pain (40-60), code 4- severe pain (60-80), code 5- intolerable pain (80-100).

At the end of second visit (after second lesion's treatment) the patients were asked to decide which method they would prefer for their future caries treatment.

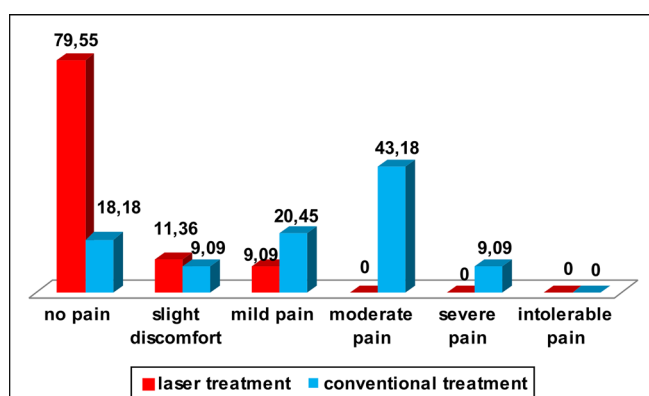
#### Data analysis

Data were collected and evaluated using statistical software SPSS (Statistical Package version 19.0).

## RESULTS

### Pain perception

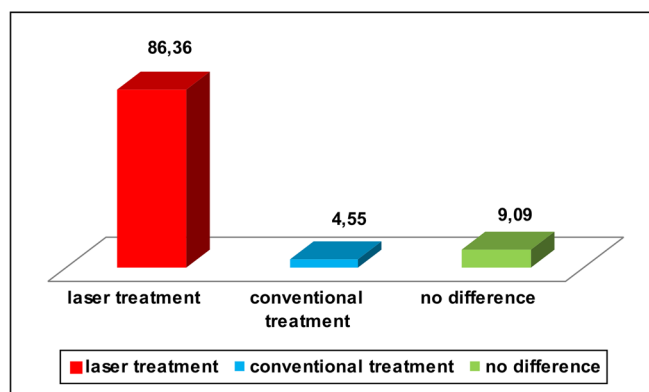
**Fig. 2.** Distribution of children according to the pain perception during caries treatment – in %



The pain perception of patients (fig. 2) during laser treatment is between no pain and mild pain. Thirty five (79.55%) of all 44 children reported no pain at all in contrast to 8 (18.18%) of children that did not feel any sensitivity during the conventional treatment ( $T=8.22$ ;  $p<0.05$ ). About half of the children 19 (43.18%) felt moderate pain and 4 (9.09%) reported severe pain during the conventional caries treatment although none of the children asked for local anesthesia during preparation.

### Patient perception

**Fig. 3.** Distribution of children according their preferences for a future treatment method- in %



For most children 38 (86.36 %) the preferred method for a further caries treatment was the laser technology. Four (9.09 %) of them reported no difference between the two methods and 2 (4.55 %) reported the conventional tools as the preferred method for a further caries treatment (fig. 3).

## DISCUSSION

Pain assessment by the children using the VAS scale indicated that the laser application resulted in absence of pain or less sensitivity than the mechanical treatment. In adolescents, 79.55 % reported no pain and 11.36 % felt only a slight discomfort.

The results in this study are similar to those from other studies [12, 13, 14]. According to Liu 82.5% of the children with carious lesions treated with Er-YAG laser, do not feel pain during treatment [13]. Boj evaluated the intensity of the pain by the Wong-Baker scale during Er, Cr-YSGG laser caries treatment of 33 children aged 8-16, and found that more than 33% of children did not report pain at all and 33% felt only a slight discomfort [12]. Genovese reported that during a Er, Cr-YSGG laser caries treatment in 6-12 years old children 42% of children did not indicate the presence of pain at all and 46% indicated only a slight discomfort during treatment [14].

The main factor that provokes pain and discomfort to the patient during conventional dental caries treatment is the contact between the treated surface and the used bur, leading to vibration [15]. During the Er-YAG laser dental caries treatment children do not feel vibration due to the

non-contact method used in laser cavity preparation. It has been found that high-speed drills induce 100 times higher vibration speed compared to the irradiation with Er-YAG laser. According to Takamori, this much higher frequency has its spectrum near the peak sensitivity of hearing, as a potential factor causing discomfort and pain [15].

The results of the present study clearly demonstrate that 86.36 % of children at the age of 16 - 18 years assume laser preparation as more comfortable compared to the mechanical caries removal and suggest laser technology as the preferred method for future dental caries treatment.

Our results are similar to those of another study, in which 82% of the patients indicated that they would prefer the laser preparation for further caries treatment [16]. Fornaini demonstrated that 89% of adult patients preferred the Er-YAG laser treatment as a means for future restorative treatment [17].

It is assumed that the noise of a conventional turbine is an important factor that causes dental phobia in clinical treatment [18].

In the present study, the most commonly reported reason for discomfort during the laser treatment is the sound of popcorn, still unfamiliar to children.

## CONCLUSION

The application of the Er-YAG laser for carious tissue removal, compared to conventional mechanical preparation, is perceived as more comfortable and the adolescents prefer it for a future treatment.

---

## REFERENCES:

1. Smith TA, Thompson JA, Lee WE. Assessing patient pain during dental laser treatment. *J Am Dent Assoc.* 1993 Feb;124 (2):90-95. [PubMed]
2. Hibst R, Keller U. Experimental studies of the application of the Er:YAG laser on dental hard substances: I. Measurement of the ablation rate. *Lasers Surg Med.* 1989; 9(4):338-344. [PubMed]
3. Bader C, Krejci I. Indications and limitations of Er:YAG laser applications in dentistry. *Am J Dent.* 2006 Jun;19(3):178-186. [PubMed]
4. Glockner K, Rumpler J, Ebeleseder K, Stadler P. Intrapulpal temperature during preparation with the Er:YAG laser compared to the conventional bur: An in vitro study. *J Clin Laser Med Surg.* 1998 Jun;16(3):153-157. [PubMed]
5. Hibst R, Keller U. Heat effect of pulsed Er:YAG laser radiation. *Laser Surg,* 1990 Jan;1200(2):379. [CrossRef]
6. Perhavec T, Diaci J. Comparison of Er-YAG and Er,Cr-YSGG dental lasers. *J Oral Dental Appl* 2008 Jun;8(2):87-94.
7. Visuri SR, Walsh JT, Wigdor HA. Erbium laser ablation of dental hard tissue: effect of water cooling. *Lasers in Surgery and Medicine.* 1996; 18(3): 294-300. [CrossRef]
8. Krmek SJ, Miletic I, Simeon P, Mehicic GP, Anic I, Radisic B. The temperature changes in the pulp chamber during cavity preparation with Er-YAG laser using a very short pulse. *Photomed Laser Surg.* 2009 Apr; 27(2):351-355. [PubMed] [CrossRef]
9. Kornblit R, Trapani D, Bossu M, Muller-Bolla M, Rocca JP, Polimeni A. The use of Er-YAG laser for caries removal in paediatric patients following minimally invasive Dentistry concepts. *Eur J Paediatr. Dent* 2008 Jun; 9(2): 81-87. [PubMed]
10. Bjorndal L, Thylstrup A. A structural analysis of approximal enamel caries lesions and subjacent dentin reactions. *Eur J Oral Sci.* 1995 Feb;103(1):25-31. [PubMed]
11. Martens LC. Laser physics and a review of laser applications in dentistry for children. *Eur Arch Paediatr Dent.* 2011 Apr;12(2):61-67. [PubMed]
12. Boj H, Galofre N, Espana A, Espasa E. Pain perception in Pediatric Patients Undergoing Laser Treatments. *J Oral Laser Applications* 2005 Feb; 5(2):85-89.
13. Liu JF, Lai YL, Shu WY, Lee SY. Acceptance and efficiency of Er:YAG laser for cavity preparation in children. *Photomed Laser Surg.* 2006 Aug;24(4):489-493. [PubMed] [CrossRef]
14. Genovese MD, Olivi G, Laser in paediatric dentistry: patient acceptance of hard and soft tissue therapy. *Eur J Paediatr Dent.* 2008 Mar;9(1):

- 13-17. [\[PubMed\]](#)
15. Takamori K, Furukawa H, Morikawa Y, Katayama T, Watanabe S. Basic study on vibrations during tooth preparations caused by high-speed drilling and Er:YAG laser irradiation. *Lasers Surg Med.* 2003 Jan;32(1):25-31. [\[PubMed\]](#) [\[CrossRef\]](#)
16. Keller U, Hibst R, Geurtsen W, Schilke R, Heidemann D, Klaiber B, et al. Erbium:YAG laser application in caries therapy. Evaluation of patient perception and acceptance. *J Dent.* 1998 Nov;26:649-656. [\[PubMed\]](#) [\[CrossRef\]](#)
17. Fornaini C, Riceputi D, Lupi-Pegurier L, Rocca JP. Patient responses to Er-YAG laser when used for conservative dentistry. *Lasers Med Sci* 2012 Nov;27(6):1205-1212. [\[PubMed\]](#) [\[CrossRef\]](#)
18. Matsumoto K, Wang X, Zhang C, Kinoshita J. Effect of a novel Er:YAG laser in caries removal and cavity preparation: a clinical observation. *Photomed Laser Surgery.* 2007 Mar;25:8-13. [\[PubMed\]](#) [\[CrossRef\]](#)

**Address for correspondence:**

Galia Zhegova, MD  
Department of Pediatric Dentistry, Faculty of Dental Medicine,  
Medical University - Sofia  
1, St. Georgi Sofiiski str., 1431 Sofia, Bulgaria.  
E-mail: [drjegova@abv.bg](mailto:drjegova@abv.bg)