

The association of bladder myeloid sarcoma and unclassified myelodysplastic/myeloproliferative disease

Mesane de myeloid sarkom ve sınıflandırılmayan myeloproliferatif/myelodisplastik hastalık birlikteliği

Mehmet Sönmez¹, Ümit Çobanoğlu², Sevdagül Mungan², Bircan Sönmez³, Rasin Özyavuz⁴

¹Department of Hematology, Karadeniz Technical University, School of Medicine, Trabzon, Turkey

²Department of Pathology, Karadeniz Technical University, School of Medicine, Trabzon, Turkey

³Department of Nuclear Medicine, Karadeniz Technical University, School of Medicine, Trabzon, Turkey

⁴Department of Urology, Karadeniz Technical University, School of Medicine, Trabzon, Turkey

Abstract

Myeloid sarcoma of the urinary bladder is a rare disorder. We report a 71-year-old man with hematuria who had a diffuse myeloid sarcoma of the bladder. He was also under follow-up for unclassified myeloproliferative/myelodysplastic disorder, diagnosed two months before. Abdominal ultrasonography and computed tomography findings were normal. Diagnostic cystoscopy revealed patchy areas of mucosal swelling with hyperemia. Histopathological examination of biopsies demonstrated a neoplasm composed of blasts showing myeloperoxidase positivity by immunohistochemistry. To our knowledge, the current case is the first case of myeloid sarcoma in the urinary bladder without evidence of a mass lesion, with a concurrent diagnosis of unclassifiable myelodysplastic/myeloproliferative disease. (*Turk J Hematol* 2009; 26: 90-2)

Key words: Myeloid sarcoma, urinary bladder, unclassified myelodysplastic/myeloproliferative disease

Received: April 3, 2008

Accepted: September 10, 2008

Özet

Myeloid sarkom mesanede nadir görülen bir hastalıktır. Bu vaka takdiminde hematüri ile başvuran ve 2 ay önce sınıflandırılmayan myeloproliferatif/myelodisplastik hastalık tanısı almış 71 yaşında erkek hastada mesanede diffüz tutulum ile seyreden myeloid sarkom tanımlandı. Hastanın batin ultrasonografisi ve tomografisi normal olup, tanısız amaçlı sistoskopiye hiperemik ve ödemli bir mukoza izlendi. Alınan mukozal örneklerin histopatolojik incelemesinde immünohistokimyasal olarak myeloperoksidaz ile boyanma gösteren blastik hücreler saptandı. Sınıflandırılmayan myeloproliferatif/myelodisplastik hastalık ile kitle olmaksızın mesanede granulositik sarkom izlenen ilk vaka olarak tanımlandı ve literatür eşliğinde tartışıldı. (*Turk J Hematol* 2009; 26: 90-2)

Anahtar kelimeler: Myeloid sarkom, mesane, sınıflandırılmayan myeloproliferatif/myelodisplastik hastalık

Geliş tarihi: 03 Nisan 2008

Kabul tarihi: 10 Eylül 2008

Introduction

Myeloid sarcoma (MS) is a collection of myeloblasts or immature myeloid cells in extramedullary sites. The lesion may precede or occur concurrently with acute or chronic myeloid leukemia or the other types of myeloproliferative or myelodysplastic syndromes. The most common sites of involvement are soft tissue, orbit, lymph nodes and skin [1].

We present a rare case with both MS of the urinary bladder with patchy areas of submucosal involvement and an unclassified myelodysplastic/myeloproliferative disease.

Case Report

A 71-year-old man was admitted to the hospital with fatigue and weakness. Physical examination was unremarkable except for pallor. Laboratory parameters were as follows: hemoglobin (Hb) 7 g/dl, platelets $130 \times 10^9/L$ and white blood cell (WBC) count $18 \times 10^9/L$ with 70% neutrophils, 20% lymphocytes, 4% myelocytes, 2% normoblasts, 2% blasts, and 1% monocytes in the blood smear. Other laboratory investigations including urea, electrolytes and liver function tests were all in normal limits. Bone marrow aspiration and biopsy demonstrated marked myeloid hyperplasia with maturation and poor granulation of granulocytes, and normal number of blast cells (Figures 1, 2). Bcr/abl fusion gene was negative. The patient was accepted as unclassified myelodysplastic/myeloproliferative disease. The diagnosis of myelodysplastic/myeloproliferative disease, unclassifiable was based on bone marrow aspiration and biopsy examination (hypercellularity and marked myeloid hyperplasia with maturation), molecular study (bcr/abl gene fusion negativity), and laboratory and clinical findings (refractory anemia, leukocytosis, absence of monocytosis and hepatosplenomegaly, and no history of recent cytotoxic or growth factor therapy). No specific treatment was planned except blood transfusion when necessary.

Approximately two months later while under routine follow-up, the patient suffered hematuria. Anemia (Hb <8 g/dl) and leukocytosis ($34 \times 10^9/L$) were still present. Abdominal ultrasonography and computed tomography (CT) of the abdomen were normal (Figure 3). Diagnostic cystoscopy revealed scattered ery-

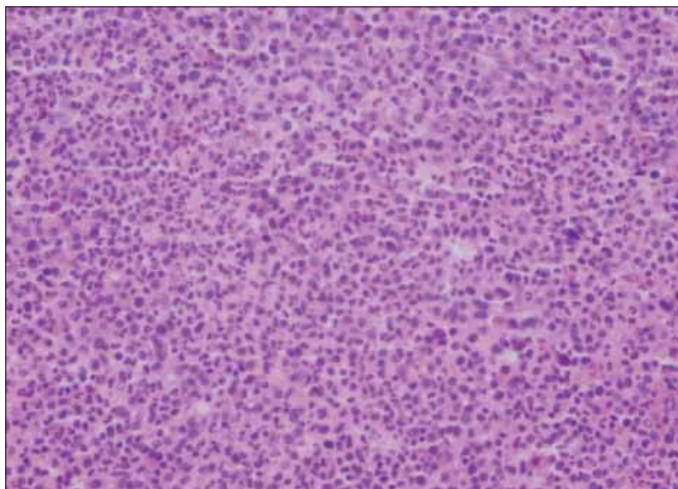


Figure 1. Hypercellular bone marrow biopsy with myeloid hyperplasia

thematous mucosal hyperemia and swelling without any mass lesion. Biopsies were performed. Histological examination demonstrated a dense cellular infiltrate composed of immature cells under normal mucosal epithelium (Figure 4). The neoplastic cells were mostly medium in size with vesicular, round nuclei. The tumor cells were stained positive for myeloperoxidase (Figures 5, 6) and negative for cytokeratin, CD20, CD3, vimentin, and S-100 protein. No other foci of infiltration were detectable at the time of diagnosis or during follow-up. During follow-up, no other specific treatment modality in relation to hematological disease was planned due to the patient's older age.

Discussion

Myeloid sarcoma is a collection of immature myeloid cells and was first described by Burns in 1811. MS was referred to as chloroma by King in 1853 due to its grossly green color when exposed to the air. This term was replaced with MS by Rappaport in 1966. In the new World Health Organization (WHO) classification, the term MS is used to define a tumor of myeloblasts or immature myeloid cells occurring in an extramedullary site [1].

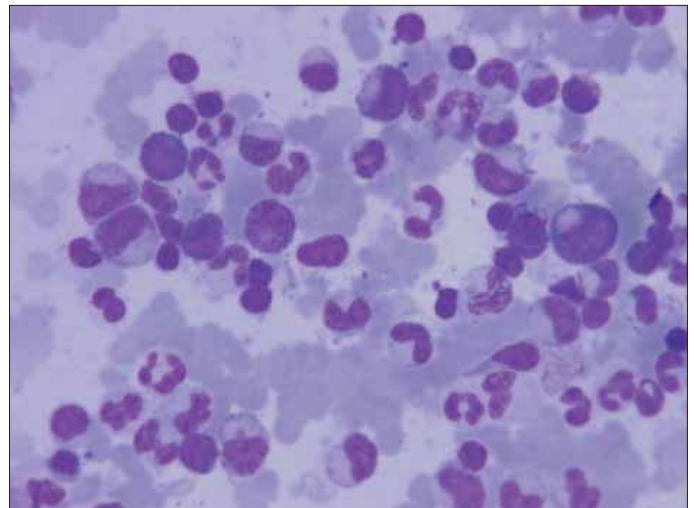


Figure 2. Bone marrow aspiration with poor granulation of granulocyte

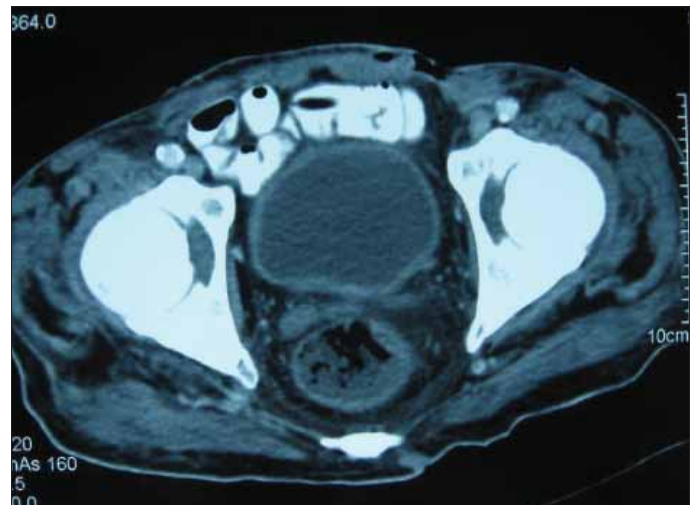


Figure 3. Computed tomography of the urinary bladder demonstrates normal thickness

Most MS cases occur in patients with a history of acute myeloid leukemia (AML), myeloproliferative disorder, or a myelodysplastic syndrome; however, it is rarely seen prior to the onset of bone marrow disease. The most common sites of involvement are soft

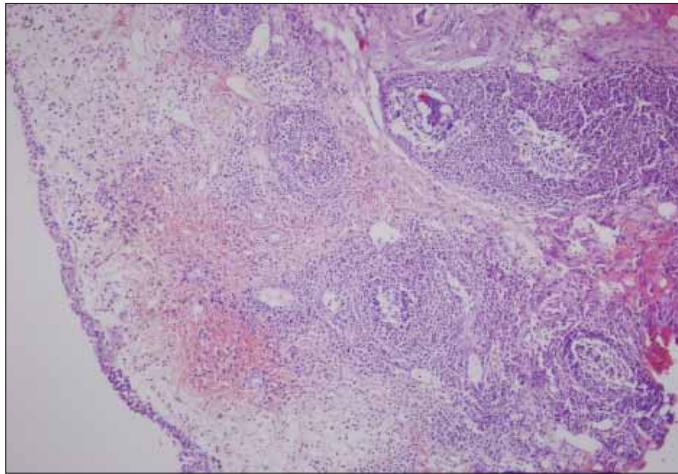


Figure 4. Immature myeloid cell infiltration in submucosa of urinary bladder

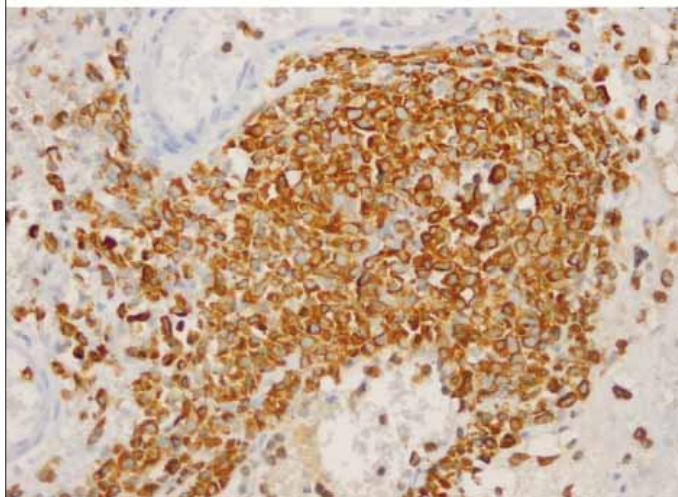
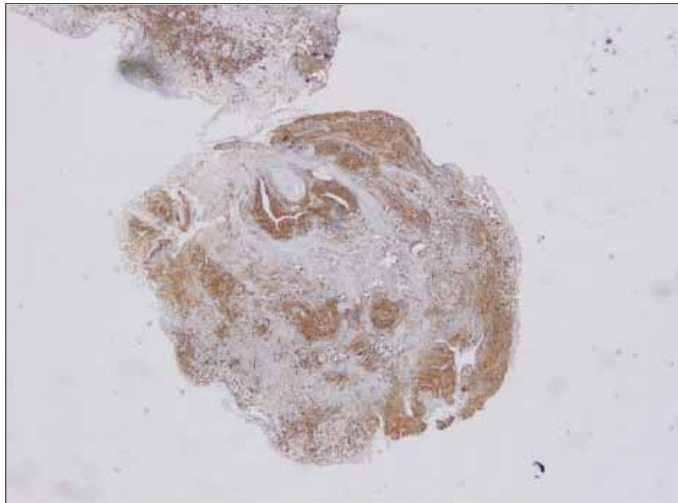


Figure 5-6. Positive staining of neoplastic cells with myeloperoxi-

zyme, lymph nodes, skin, periosteum and bone. Infrequently, it has been reported in other sites, such as the mediastinum, breast, orbit, uterus, epididymis, and gallbladder [2-4].

MS involving the urinary bladder is rare. In our review of the medical literature in English, we identified eight cases of MS involving the urinary bladder [2,3,5-9]. No cases were reported to have patchy submucosal involvement without any mass lesion, and there has been no reported association with myelodysplastic/myeloproliferative disease, unclassifiable. In the current case, abdominal CT demonstrated normal thickness of the urinary bladder wall and no mass lesion. Diagnostic cystoscopy demonstrated areas of patchy mucosal hyperemia.

MS is generally composed of poorly differentiated blasts and immature cells. The major differential diagnoses are large cell lymphoma, Burkitt lymphoma, lymphoblastic lymphoma and undifferentiated round cell tumor. Immunophenotyping by immunohistochemistry for expression of myeloid markers such as myeloperoxidase is essential for diagnosis of MS [10].

To our knowledge, this is the first report of a case with MS with diffuse infiltration of the urinary bladder and unclassified myelodysplastic/myeloproliferative disease. MS of the urinary bladder should be suspected in patients presenting with hematuria having myeloid leukemia and myeloproliferative or myelodysplastic syndromes, and even when associated with unclassified myelodysplastic/myeloproliferative disease, as in our case. Cystoscopic examination and biopsy of any suspicious mucosal lesion should be performed in the absence of any mass lesion in the urinary bladder in patients under follow-up for this diagnosis.

References

1. Jaffe EHN, Stein H, Vardiman JW. World Health Organisation classification of tumours, pathology and genetics of tumours of haematopoietic and lymphoid tissues. In: Jaffe EHN, Stein H, Vardiman JW, editors. Lyon, France: IARC Press, 2001:105-6.
2. Al-Quran SZ, Olivares A, Lin P, Stephens TW, Medeiros LJ, Abruzzo LV. Granulocytic sarcoma of the urinary bladder and epididymis as a primary manifestation of acute granulocytic leukemia with inv(16). *Arch Pathol Lab Med* 2006;130:862-6.
3. Aki H, Baslar Z, Uygun N, Ozguroglu M, Tuzuner N. Primary granulocytic sarcoma of the urinary bladder: case report and review of the literature. *Urology* 2002;60:345.
4. Ramasamy K, Lim Z, Pagliuca A, Devereux S, Ho AY, Mufti GJ. Acute myeloid leukaemia presenting with mediastinal myeloid sarcoma: report of three cases and review of literature. *Leuk Lymphoma* 2007;48:290-4.
5. Hasegeli Uner A, Altundag K, Saglam A, Tekuzman G. Granulocytic sarcoma of the urinary bladder. *Am J Hematol* 2004;75:262-3.
6. Kerr P, Evely R, Pawade J. Bladder chloroma complicating refractory anaemia with excess of blasts. *Br J Haematol* 2002;118:688.
7. Cartwright PC, Faye-Petersen O, Bybee B, Snow BW. Leukemic relapse presenting with ureteral obstruction caused by granulocytic sarcoma. *J Urol* 1991;146:1354-5.
8. Merino Moreno J, Núñez Olarte JM, Picó Sambucety JM, Pastor Gómez-Cornejo L, Ortega Núñez A. Granulocytic sarcoma (chloroma) with bladder and breast localizations preceding acute myeloblastic leukemia. *Rev Clin Esp* 1987;180:260-3.
9. Chaitin BA, Manning JT, Ordóñez NG. Hematologic neoplasms with initial manifestations in lower urinary tract. *Urology* 1984;23:35-42.
10. Paydas S, Zorludemir S, Ergin M. Paydas S, Zorludemir S, Ergin M. Granulocytic sarcoma: 32 cases and review of the literature. *Leuk Lymphoma* 2006;47:2527-41.