

7-1-2002

# On the Prevalence of External Auditory Exostoses Among the Proto-Neolithic Homo Sapiens Population of Shanidar Cave, Iraq

Anagnostis P. Agelarakis  
*Adelphi University*

Yula C. Serpanos  
*Adelphi University*

Follow this and additional works at: [https://digitalcommons.adelphi.edu/ant\\_pubs](https://digitalcommons.adelphi.edu/ant_pubs)



Part of the [Anthropology Commons](#), and the [Communication Sciences and Disorders Commons](#)

---

## Repository Citation


Agelarakis, Anagnostis P. and Serpanos, Yula C., "On the Prevalence of External Auditory Exostoses Among the Proto-Neolithic Homo Sapiens Population of Shanidar Cave, Iraq" (2002). *Anthropology Faculty Publications*. 18.  
[https://digitalcommons.adelphi.edu/ant\\_pubs/18](https://digitalcommons.adelphi.edu/ant_pubs/18)

This Journal Article is brought to you for free and open access by the Anthropology at Adelphi Digital Commons. It has been accepted for inclusion in Anthropology Faculty Publications by an authorized administrator of Adelphi Digital Commons. For more information, please contact [kherold@adelphi.edu](mailto:kherold@adelphi.edu).

# HUMAN EVOLUTION

VOLUME 17

JULY - DECEMBER 2002 - N.3-4



ANGELO PONTECORBOLI EDITORE  
FIRENZE

Agelerakis A.

Adelphi University  
Department of Anthropology and  
Sociology  
Blodgett Hall  
South Avenue  
Garden City, New York  
Agelerak@adlibv.Adelphi.edu

Serpanos Y.C.

Adelphi University  
Department of Communication  
Sciences & Disorders  
Hy Weinberg Center  
Cambridge Avenue  
Garden City, NY 11530  
Serpanos@adlibv.Adelphi.edu

## On the Prevalence of External Auditory Exostoses Among the Proto-Neolithic *Homo sapiens* Population of Shanidar Cave, Iraq

The purpose of this paper is to report on the incidence of external auditory exostoses among the Proto-Neolithic *Homo sapiens* population from Shanidar Cave, in northern Iraq. Out of 31 individuals comprising the skeletal collection, seven individuals preserved pertinent temporal bone loci. Of these, four of five adult individuals presented exostoses, yielding an 80% observation ratio of this manifestation. Based on the association of external auditory exostoses with cold aquatic exposures, the observed presence of these growths among cranial remains may provide further insight as to aspects of life conditions among this population.

*Key words:* Auditory Exostoses, *H. Sapiens*, Shanidar Cave, Iraq.

---

### Background of Site

The Shanidar valley of the Baradost Mountains is located in the rugged topography of the Zagros highland complex of the northeastern Iraqi Kurdistan. In the valley, and near to the bank of the Greater Zab river, is the location of the Proto-Neolithic village site of Zawi Chemi Daraw Shanidar, situated in the immediate vicinity of the contemporary small Kurdish village of Shanidar. The large cave of Shanidar is located approximately 5 km from the village, toward the rugged highland terrain in the Baradost Mountains.

The cave has been the scene of extensive archeological investigations. Indeed, archeological research enabled the documentation of the Middle Paleolithic Zagros Mousterian, the Upper Paleolithic Baradostian, and the EpiPaleolithic Zarzian cultures of the region. Subsequent to the Zarzian horizon of the cave site was the discovery of a Proto-Neolithic component radiocarbon-dated to 10,600 +/-300 BP (Solecki, R.S., 1955, 1961, 1963; Solecki, R.L., 1964, 1981).

The Proto-Neolithic component of the cave site yielded 26 human burial locations (Solecki, 1961). Through a 1985 study of the human skeletal collection in Baghdad, coupled by subsequent analyses, it was possible to document the presence of 31 skeletal individuals. The majority of individuals is, anatomically speaking, incomplete given the gamut of contributing factors such as burial customs and practices, taphonomic circumstances, and post excavation handling. Nevertheless, skeletal individuals represented either by cranial, and postcranial remains, revealed adequately preserved surfaces and osseous components for anthropolo-

gical and paleopathological studies, including archaeometric analyses. Underlining the significance of this rare collection is the fact that it consists of individuals from both biological sexes (Figure 1), and a range of sub-age groups (Figure 2), from Perinatal to Maturus.

### Sample

Adult individuals comprised 44% of the collection, indicating the highest representation of the combined Adult age sub-groups, and the highest prevalence of mortality in the demographic profile of the skeletal collection. High prevalence of mortality, with decreasing values, was also observed with the Perinatal to Infancy I age sub-groups, which combined comprised 32% of the skeletal collection. The lowest ratios were observed within the late Infancy II to early Juvenile, and Maturus sub-age groups, respectively.

Examinations of the morphological characteristics of the skeletal remains revealed well-built skeletal bodies. Sexual dimorphism was apparent, with males manifesting increased attributes of robustness with emphasized muscular imprints specifically on their lower extremities. The crania were lightly built, showing features and morphocharacteristics that resemble more modern aspects than these of the roughly coeval Natufian populations (Ferembach, 1970), and the Mesolithic skeletal populations from Nubia (11,950-6,400 BC) (Armelagos, 1988; personal communication).

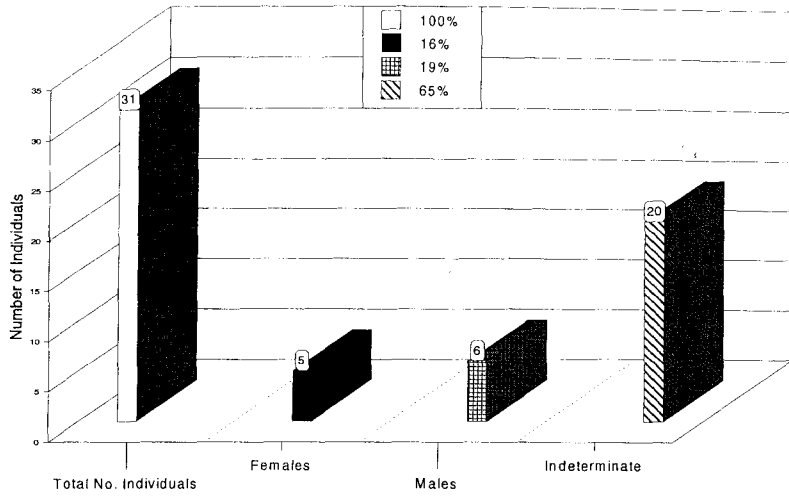
### Data

Paleopathological laboratory analyses of the entire collection at the macroscopic and microscopic levels aided by archeometric studies for isotopic fractionation have shown important information relative to the demographic profile, the paleopathological record, and aspects of the cultural conditions of this Proto-Neolithic population (Agelarakis, 1989, 1993).

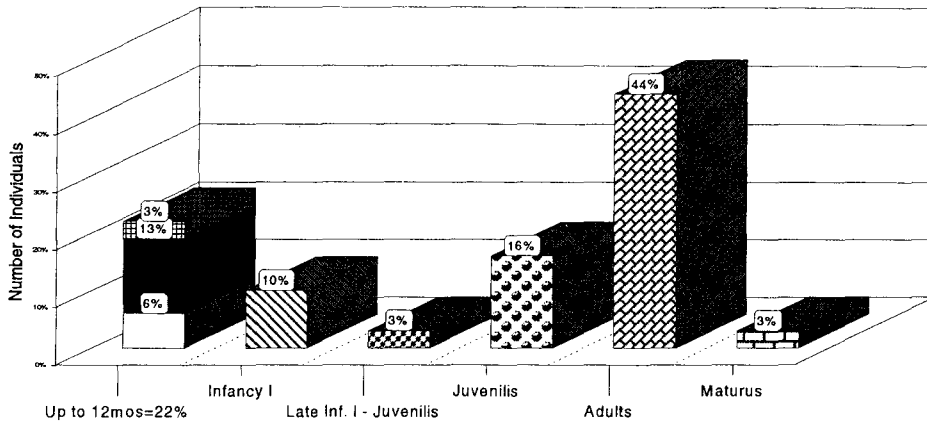
For the purposes of this paper, specific studies focused on the cranial structures of both adult and immature individuals. This focus was chosen considering a high prevalence of external ear manifestations observed among both adult males and females, coupled by a high prevalence (33%) of both male and female ecto-, and endocranial periosteal reactions of inflammatory nature due to traumatic and infectious causative agents. In addition, 33% of adult females showed similar reactions just on their ectocranial surfaces because of similar causative agents.

Seven individuals (assigned the following field catalog numbers: 295A, 337B, 371-298A, 382A, 382B, 383A, and 384A) from the collection preserved osseous components of temporal bones (Table 1). Of these, two immature individuals (337B and 382B) with pertinent preservation were lacking such manifestations. Of the remaining five individuals, all of which were adults of both sexes, four showed external ear manifestations of bony growths (295A, 382A, 383A, and 384A). Morphological and paleopathological assessment implicating differential diagnosis of these bony growths identified them as external ear exostoses. Hence, an 80% observation ratio of exostoses was revealed from this sample.

**Shanidar Cave: Aspects of Demography**  
**Biological Sex Assessments**



**Shanidar Cave: Aspects of Demography**  
**Lumped Age Groups**



2 x Perinatal	6%				
4 x Perinatal - 6mos	13%				
1 x 9-12mos	3%				
3 x Infancy I		10%			
1 X Late Inf. I - Juv.			3%		
5 x Juvenilis				16%	
14 x Adults					44%
1 X Maturus					3%

Table 1. Shanidar Proto-Neolithic Individuals Preserving Temporal Bones with Meatus Acusticus Externus and Pars Petrosa

Field Catalog Numbers	Age Sub-groups	Biological Sex
295 A	Sub-Adult	possible Female
337 B	Infancy I	Indeterminate
371-298 A	Young Adult	Female
382 A	Young Adult	Male
382 B	Perinatal	Indeterminate
383 A	Young Adult - initial Middle Adult	Male
384 A	Late Adult - Maturus	Female

## Discussion

The Shanidar Proto-Neolithic human skeletal collection revealed a considerably high incidence (80%) of external auditory exostoses identified among adult individuals. External auditory exostoses are benign osseous growths that originate from the tympanic portion of the temporal bone and extend into the external auditory meatus. In appearance, the exostoses are broad-based growths of bone covered with the squamous epithelium of the external auditory meatus. Though the growths may vary in form and size, they are typically multiple and occur bilaterally, mainly in adults (Cunningham and Myers, 1988; Graham, 1979; Morrison, 1948; Sheehy, 1958; Van den Broek, 1945).

The growths are considered an acquired auditory disorder associated with prolonged or repeated exposure to cold aquatic activities such as diving (Fabiani, Barbara, and Filipo, 1984; Karegeannes, 1995), surfing (Deleyiannis, Cockcroft, and Pinczower, 1996; DiBartolomeo, 1979; Seftel, 1977) or swimming (Harrison, 1951). The temperature and duration of exposure to water appear to be the causative factors for exostoses formation. Several studies suggest that the development of exostoses is associated with exposure of the ear to water temperatures below 19 C (Kennedy, 1986; Sakalinskas and Jankauskas, 1993; Van Gilse, 1938). In addition, a higher incidence of exostoses has been noted with more frequent exposures to cold water temperatures (DiBartolomeo, 1979; Fabiani and Filipo, 1984; Fowler and Osmun, 1942; Harrison, 1951; Seftel, 1977).

Though the initiation process of exostoses formation is not clearly understood, it is postulated that the increased tension on the periosteum of the ear canal resulting from periods of vasodilation from cold water exposures could be responsible for the osteogenesis leading eventually to the production of the growths (Fowler and Osmun, 1942; Hrdlicka, 1935; Hutchinson, Denise, Daniel and Kalmus, 1997; Van Gilse, 1938). Although exostoses are benign, continued growth can lead to complete or partial ear canal occlusion, resulting in conductive hearing loss. The obstruction may further cerumen impaction or infection from trapped water or debris, leading to otorrhea and otalgia. In advanced cases, cholesteotoma can result, extending into the middle ear cavity, fossa or mastoid regions (Tran, Grundfast, and Selesnick, 1996).

Due to the etiologic link with cold water exposure, the presence of exostoses in specific populations has been considered as evidence for a maritime activity, providing insight as to

such life conditions as diet or allocation/ distribution of labor activities between biological sexes. Indeed, the presence of auditory exostoses has been reported in other ancient populations that lived near coastal regions. Such samples have been found in regions of Chile (Arriaza, 1995; Standen, Arriaza, and Stantoro, 1997), Lithuania (Sakalinskas and Jankauskas, 1993), and in the south Florida, USA region (Hutchinson et al, 1997).

Regarding the high prevalence of ear exostotic manifestations observed indiscriminately among both adult males and females within the Shanidar Proto-Neolithic human population, it is suggested that the growths may be an osseous marker of habitual and/or occupational stress (MHOS). Considering the rest of the archeo-anthropological record discerning aspects of the specialization, cultural adaptations, and innovations of this population as reflected through the domestication processes of plants (cereals) (Leroi-Gourhan, 1969, 1976) and animals (sheep) (Perkins, 1964, 1974), their artifactual assemblages and tool technologies, as well as their skeletal manifestations of kinetics, load impact and trauma (Agelerakis, 1993), it could be easily assessed that they were quite mobile within the rugged and precipitous topography of the geomorphologic region of the Shanidar valley. Similar information is gathered from current ethnohistoric studies of Kurdish populations which on their combined agriculture/transhumance endeavors cross multiple times, every year, the cold and turbulent waters of the Zab river and its tributaries before reaching Shanidar valley and its large cave into which they reside with their animals (R. Solecki, 1989; personal communication).

Further, it is suggested that the Proto-Neolithic people of Shanidar would have very well exposed themselves in cold aquatic environments while exploring the rich protein resource of bivalve and gastropod shells, as reflected through the archeological ecofactual record of the Shanidar valley. While it is realized that other habitual and/or cultural activities, as of yet not incompletely understood and/or unexplained archeo-anthropologically, could have triggered and/or caused such ear exostotic manifestations, the fact that such manifestations are observable between both males and females strongly suggests underlying physical activities non indicative of biological sex related division of cultural habits or labor diversity.

## References

- Agelerakis, A., 1989. The paleopathological evidence, indicators of stress of the Shanidar Proto- Neolithic and the Ganj Dareh early Neolithic human skeletal collections. Ph.D. thesis. Columbia University. Published under the University Microfilms International, Bell and Howell Co., Michigan.
- Agelerakis, A., 1993. The Shanidar cave Proto-Neolithic human population: aspects of demography and paleopathology. *Human Evolution* 8(4): 235-253.
- Arriaza, B., 1995. Beyond death. The Chinchorro mummies of ancient Chile. Washington, D.C.: Smithsonian Institution Press.
- Cunningham, M.J. and Myers, E.N., 1988. Tumors and tumorlike lesions of the ear and temporal bone in children. *Ear, Nose, and Throat Journal* 67: 736-749.
- Deleyiannis, F.W.B, Cockcroft, B.D., and Pinczower, E.F., 1996. *American Journal of Otolaryngology* 17: 303-307.
- DiBartolomeo, J., 1979. Exostoses of the external auditory canal. *Annals of Otology, Rhinology, Laryngology [Suppl 6]* 88: 1-17.
- Fabiani, M., Barbara, M., and Filipo, R., 1984. External ear canal exostosis and aquatic sports. *ORL J. Otorhinolaryngol. Relat. Spec.* 46: 159-164.
- Ferembach, D., 1970. Etude anthropologique des ossements humains Proto-Neolithique

- Zawi-Chemi Shanidar (Iraq). *Sumer* 26: 21-64.
- Fowler E., Jr., and Osmun, P., 1942. New bone growth due to cold water in the ear. *Archives Otolaryngology* 36: 455-466.
- Graham, M.D., 1979. Osteomas and exostoses of the external auditory canal: A clinical, histopathologic and scanning electron microscope study. *Annals of Otology* 88: 566-572.
- Harrison, D.F.N., 1951. Exostosis of the external auditory meatus. *Journal of Laryngology and Otology* 65: 704-714.
- Hrdlicka, A., 1935. Ear exostoses. *Smithsonian Miscellaneous Collection* 93(6): 1-100.
- Hutchinson, D.L., Denise, C.B., Daniel, H.J., and Kalmus, G.W., 1997. A reevaluation of the cold water etiology of external auditory exostoses. *American Journal of Physical Anthropology* 103: 417-422.
- Karegeannes, J.C., 1995. Incidence of bony outgrowths of the external ear canal in U.S. navy divers. *Undersea & Hyperbaric Medicine* 22: 301-306.
- Kennedy, G.E., 1986. The relationship between auditory exostoses and cold water: A latitudinal analysis. *American Journal of Physical Anthropology* 71: 401-415.
- Morrison, W., 1948. *Disease of the Ear, Nose and Throat*. New York: Appleton-Century Crofts.
- Sakalinskas, V. and Jankauskas, R., 1993. Clinical otosclerosis and auditory exostoses in ancient Europeans (investigation of Lithuanian paleosteological samples). *The Journal of Laryngology and Otology* 107: 489-491.
- Sefel, D., 1977. Ear canal hyperostosis- surfer's ear. *Archives of Otolaryngology* 103: 58-60.
- Sheehy, J.L., 1958. Osteoma of the external auditory canal. *Laryngoscope* 68: 1667-1673.
- Solecki, R.L., 1964. Zawi Chemi Shanidar, a Post Pleistocen village in Northern Iraq. VI International Congress on Quarternary, Warsaw, 1961, 402-412.
- Solecki, R.L., 1981. Zawi Chemi Shanidar. *Undena Publications*.
- Solecki, R.S., 1955. Shanidar cave, a Paleolithic site in Northern Iraq. *Smithsonian Annual Report*, 1954, 389-425.
- Solecki, R. S., 1961. Zawi Chemi Shanidar, a Post Pleistocen village site in Northern Iraq. Vth International Congress on Quarternary, Warsaw.
- Solecki, R.S., 1963. Prehistory in Shanidar Valley, Northern Iraq. *Science* 139: 179-193.
- Standen, V. G., Arriaza, B.T., and Santoro, C.M., 1997. External auditory exostosis in prehistoric Chilean populations: A test of the cold water hypothesis. *American Journal of Physical Anthropology* 103: 119-129.
- Tran, L.P., Grundfast, K.M., and Selesnick, S.H., 1996. Benign lesions of the external auditory canal. *Otolaryngology Clinics of North America* 29: 807-825.
- Van Den Broek, A.J.P., 1945. On exostosis in the human skull. *Acta Nederlandica Morphologiae* 5: 95-118.

Received September 30, 1999

Accepted February 20, 2000