

CASE REPORT

Concomitant Case of Primary Biliary Cirrhosis and Autoimmune Hemolytic Anemia Responding to Corticosteroid and Ursodeoxycholic Acid in Young Woman

*Susanto H Kusuma, **Fardah Akil, **Amelia Rifai, **Rini R Bachtiar,
**Numan AS Daud, **AM Luthfi Parewangi

*Department of Internal Medicine, Faculty of Medicine
Hasanuddin University, Makassar

**Division of Gastroentero-hepatology, Department of Internal Medicine
Faculty of Medicine, Hasanuddin University, Makassar

Corresponding author:

Fardah Akil. Division of Gastroentero-hepatology, Department of Internal Medicine, Dr. Wahidin Sudirohusodo. Jl. Perintis Kemerdekaan Makasar Indonesia. Phone/facsimile: +62-411-585281. E-mail: fardah.akil@gmail.com

ABSTRACT

Primary biliary cirrhosis (PBC) is an autoimmune liver disease of unknown etiology and is characterized by chronic progressive cholestasis with destruction of the small intrahepatic bile ducts and associated most commonly with antimitochondrial antibodies. PBC is most common in women and is often associated with other autoimmune disease such as autoimmune hemolytic anemia (AIHA), rheumatoid arthritis, thyroiditis, and systemic lupus eritomatosus.

We report one case, a 20 years old woman with AIHA have been treated by corticosteroid since last year and she came to the outpatient department (OPD) with fatigue and jaundice. The result of laboratory were haemoglobin 8.7 mg/dL, white blood cell 8700 mg/dL, coomb test +2, total bilirubin 33.2 mg/dL, direct bilirubin 29.3 mg/dL, γ GT: 297 mg/dL and alkalyphospatase: 158 mg/dL. The result of Abdominal CT scan showed the size of liver and spleen increased and normal common bile duct (CBD). The result of ANA test, anti-nuclear (ANA) and antimitochondrial M2 (AMA M2) antibodies were positive. From the physical examination, laboratory and CT scan Abdomen; the diagnose of this patient was AIHA with PBC.

After treatment with corticosteroid (prednison 1mg/kg/day) and ursodeoxycholic acid (UDCA) for several weeks, the clinical manifestation of PBC such as jaundice getting better (the laboratory result: total bilirubin 2.7 mg/dL, direct bilirubin 1.5 mg/dL, gamma GT 80 mg/dL).

Keywords: primary biliary cirrhotic, autoimmune hemolytic anemia, corticosteroid, ursodeoxycholic acid

ABSTRAK

Primary biliary cirrhosis (PBC) adalah suatu penyakit hati autoimun yang etiologinya belum diketahui dan ditandai oleh kolestasis progresif yang kronik dengan kerusakan duktus bilier intra-hepatik dan umumnya dihubungkan dengan antibodi antimitokondrial. Pada umumnya PBC terjadi pada wanita dan biasanya berhubungan dengan penyakit autoimun lainnya, seperti anemia hemolitik autoimun (AIHA), artritis reumatik, tiroiditis dan eritema lupus sistemik.

Kami melaporkan sebuah kasus, wanita berumur 20 tahun dengan penyakit AIHA yang telah mendapat terapi kortikosteroid sejak 1 tahun lalu dan datang berobat di poli rawat jalan dengan lemah dan kuning seluruh badan. Hasil pemeriksaan laboratorium adalah hemoglobin 8.7 mg/dL, lekosit 8700 mg/dL, coomb test +2,

bilirubin total 33.2 mg/dL, bilirubin direk 29.3 mg/dL, γ GT: 297 mg/dL dan alkaliphospatase: 158 mg/dL. Hasil pemeriksaan CT scan Abdomen menunjukkan adanya hepatosplenomegali dan duktus bilier dalam batas normal. Hasil pemeriksaan ANA tes didapatkan positif antibodi anti-nuclear (ANA) dan antibodi antimitokondrial M2 (AMA M2). Dari hasil pemeriksaan fisis, laboratorium dan CT scan abdomen, maka kami mendiagnosis pasien ini dengan AIHA yang disertai dengan PBC.

Setelah diberikan terapi kortikosteroid (prednison 1 mg/kg/hari) dan ursodeoxycholic acid (UDCA) selama beberapa minggu, manifestasi klinik dari PBC seperti kuning, menjadi berkurang (hasil laboratorium: bilirubin total 2.7 mg/dL, bilirubin direk 1.5 mg/dL, γ GT 80mg/dL).

Kata kunci: primary biliary cirrhotic, anemia hemolitik autoimun, kortikosteroid, ursodeoxycholic acid

INTRODUCTION

Primary biliary cirrhosis (PBC) is an autoimmune liver disease of unknown etiology and is characterized by chronic progressive cholestasis with destruction of the small intrahepatic bile ducts and associated most commonly with antimitochondrial antibodies.^{1,2,3} The disease is uncommon, with a reported prevalence between 19 and 402 cases per million. The vast majority (90%) of patients affected are women, with the usual time of diagnosis between 30 and 60 years. The diagnosis of PBC is based on three criteria: elevation of liver enzymes (most commonly ALP and γ -GT), presence of detectable AMA in the serum, and liver histologic findings that are compatible with the presence of the disease.⁴

PBC is most common in women and is often associated with other autoimmune disease such as autoimmune hemolytic anemia (AIHA), rheumatoid arthritis, thyroiditis, and systemic lupus eritomatosis. Autoimmune hemolytic anemia involves an autoimmune process and is caused by a hemolysis induced by the reaction of autoantibodies with red blood cells (RBCs) and it's characterized by a positive direct Coombs' test. It is idiopathic (primary) in approximately 50% cases or secondary to medication, hematological malignancies and autoimmune disorders.⁵⁻⁹ AIHA is also a rare disease with incidences reported in the range of 1 per 75,000 to 2 per 100,000. Primary or idiopathic AIHA accounts for less than half of the cases and most patients will be found to have underlying associated conditions including tumors, autoimmune diseases, or an acquired immunodeficiency syndrome.⁹

The association between primary biliary cirrhosis (PBC) and autoimmune hemolytic anemia (AIHA) is uncommon. Despite the autoimmune basis of PBC, there have been few reports of PBC in association with AIHA.¹⁰ The recommended treatment for PBC-related AIHA includes sufficient doses of corticosteroids to control the hemolysis at the acute phase, and immunosuppressant (for example CTX and CsA) or

adequate dose of UDCA to maintain therapy.¹¹ We describe a case of AIHA in association with PBC, which responded to ursodeoxycholic acid (UDCA) used as sole treatment.

CASE ILLUSTRATION

We report a 20 years old woman with AIHA have been treated by corticosteroid since last year and she came to the outpatient department (OPD) with fatigue and jaundice. From the physical examination, we found palor, hepatosplenomegaly, no lymphadenopathy. The result of laboratory were haemoglobin 8.7 mg/dL, white blood cell 8,700 mg/dL, coomb test +2, total bilirubin 33.2 mg/dL, direct bilirubin 29.3 mg/dL, γ GT: 297 mg/dL and alkalyphospatase: 158 mg/dL. Cause of jaundice, we did the Abdominal CT Scan.

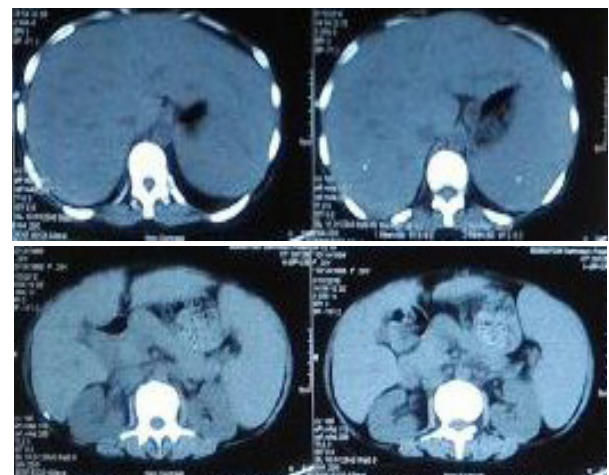


Figure 1. The abdominal CT scan's results showed size of the liver and spleen increased with normal parenchyma, gallbladder within normal limited, no stone in CBD.

The result from ANA profile: anti-nuclear (ANA) and antimitochondrial M2 (AMA M2) antibodies were positive (Figure 2). Strong Positive in: SS-A native (60 kDa): (+++); Ro-52 recombinant: (++) ; SS-B: (+++); Nucleosomes: (++) ; Control: (+++).

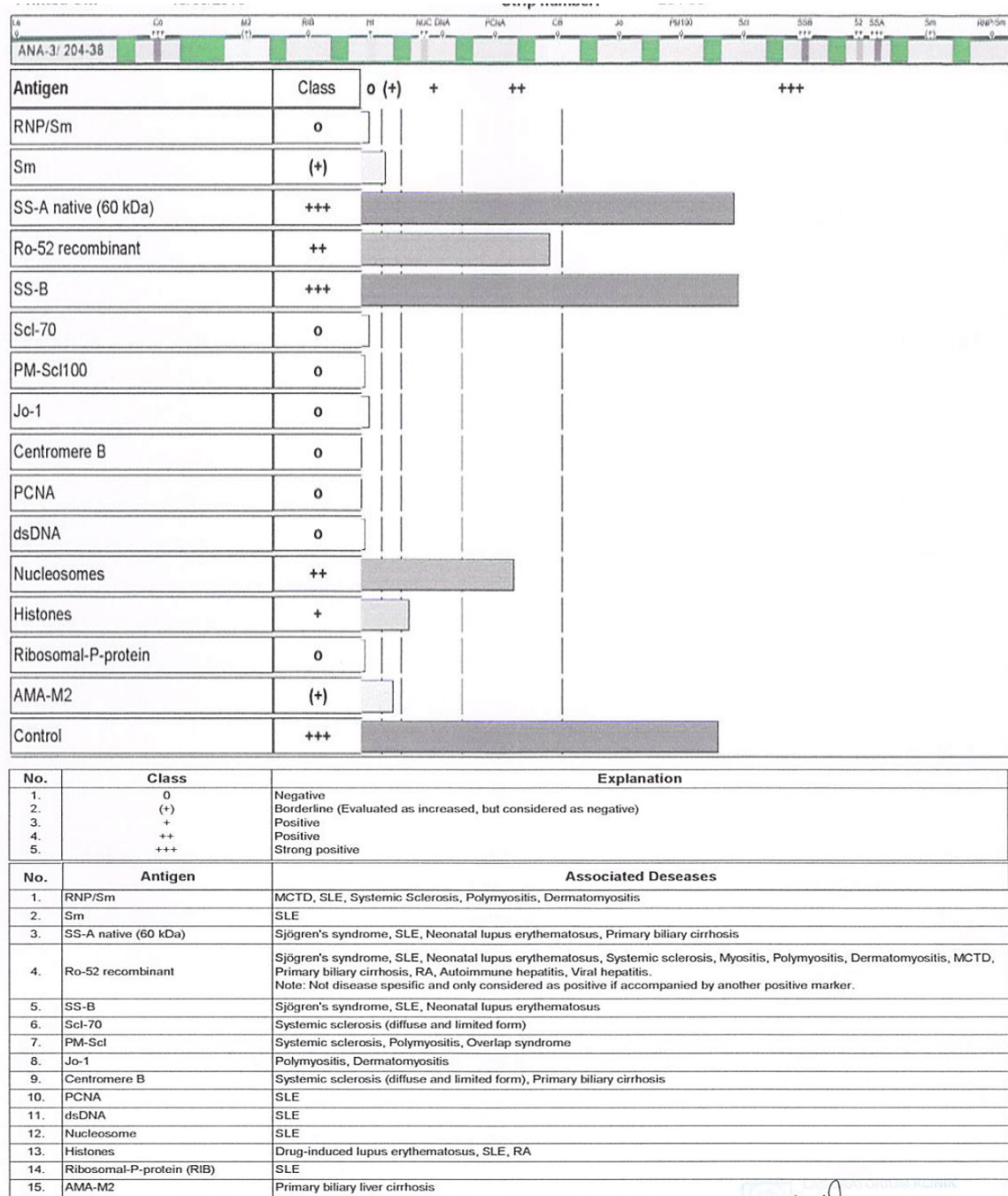


Figure 2. The anti-nuclear (ANA) profile

After treatment with corticosteroid (prednison 1mg/kg/day) and ursodeoxicholic acid (UDCA) for several weeks, the clinical manifestation of PBC such as jaundice getting better (the laboratory result: total bilirubin 2.7 mg/dL, direct bilirubin 1.5 mg/dL, gamma GT 80mg/dL).

DISCUSSION

Primary biliary cirrhotic is a slowly progressive autoimmune disease. The diagnosis of PBC is based on three criteria: elevation of liver enzymes (most

commonly ALP and γ -GT), presence of detectable AMA in the serum, and liver histologic findings that are compatible with the presence of the disease.⁹ While AIHA is also an immune disease which is caused by antibodies directed against autologous red cells, the diagnosis is based on the presence of anemia, signs of hemolysis with reticulocytosis, increased lactate dehydrogenase, elevated indirect bilirubin, and a positive Coombs' test.² Not all patients with PBC received the diagnosis when it was at an early stage because of their asymptomatic status, and it is supposed that PBC occurred after AIHA development

in these patients.⁹ The occurrence suggests a possible relationship between the two diseases. PBC patients are likely to have some conditions which can induce generation of anti-erythrocyte antibodies.⁸

Corticosteroid treatment is not only a preferred therapy for AIHA, but an adjuvant therapy that benefits PBC patients.¹¹ According to the criteria of secondary AIHA: (1) AIHA would occur on the basis of PBC; (2) Reversal of AIHA and liver function improvement of PBC happened simultaneously with the intake of immunosuppressive agents; (3) Both PBC and AIHA are known to be immune-mediated diseases. Thus, we could call them PBC-related AIHA. Serum bilirubin levels have long been known to be important in assessing the prognosis of PBC, but confounding hemolysis may lead to erroneous conclusions about the severity of PBC.² At the same time, compared with primary AIHA, this PBC-related AIHA is life-threatening but can be controlled. If no attention is paid to this condition, primary PBC will be ignored, as 50–60% of PBC patients are asymptomatic at diagnosis.¹² Therefore patients with PBC whose serum bilirubin levels rise suddenly should undergo screening for associated hemolysis.

The recommended treatment for PBC-related AIHA includes sufficient doses of corticosteroids to control the hemolysis at the acute phase, and immunosuppressant (for example CTX and CsA) or adequate dose of UDCA to maintain therapy. To deal with the severe, life-threatening hemolysis, intravenous immunoglobulin and large dosage of corticosteroids impact therapy may be considered. Only UDCA therapy for PBC patients with mild AIHA had a successful report, so in mild cases this method could be considered with regular blood cell counts to monitor response. Although Kaibori et al provided a successful case that could confirm liver transplantation and splenectomy is a curative therapy to PBC-related AIHA.^{5,8}

REFERENCES

1. Harada K, Nakanuma Y. Prevalence and risk factors of hepatocellular carcinoma in Japanese patients with primary biliary cirrhosis. *Hepatol Res* 2014;44:133-40.
2. Shizuma T, Kuroda H. A case of primary biliary cirrhosis which developed eight years after diagnosis of systemic lupus erythematosus. *Intern Med* 2011;50:321-4.
3. Matsumoto T, Kobayashi S, Shimizu H, Nakajima M, Watanabe S, Kitami N, et al. The liver in collagen disease: pathologic study of 160 cases with particular reference to hepatic arteritis, primary biliary cirrhosis, autoimmune hepatitis and nodular regenerative hyperplasia of the liver. *Liver* 2000;20:366-73.
4. Barros MM, Blajchman MA, Bordin JO. Warm autoimmune hemolytic anemia: recent progress in understanding the immunobiology and the treatment. *Transfus Med Rev* 2010;24:195-210.
5. Gehrs BC, Friedberg RC. Autoimmune hemolytic anemia. *Am J Hematol* 2002;69:258-71.
6. Valent P, Lechner K. Diagnosis and treatment of autoimmune haemolytic anaemias in adults: a clinical review. *Wien Klin Wochenschr* 2008;120:136-51.
7. Michel M. Classification and therapeutic approaches in autoimmune hemolytic anemia: an update. *Expert Rev Hematol* 2011;4:607-18.
8. Chaudhary RK, Das SS. Autoimmune hemolytic anemia: From lab to bedside. *Asian J Transfus Sci* 2014;8:5-12.
9. Shlamovitz GZ, Johar S. A case of Evans' syndrome following influenza vaccine. *J Emerg Med* 2013;44:e149-151.
10. Packman CH, Leddy JP: Acquired hemolytic anemia due to warm-reacting autoantibodies (chapter 64); in Bentler E, Lichtman MA, Collier BS, Kipps TJ (eds): *Williams Hematology*, ed 5. McGraw-Hill Health Professions Division, New York, 1995, pp 677–85.
11. Nakasone H, Sakugawa H, Fukuchi J, Miyagi T, Sugama R. A patient with primary biliary cirrhosis associated with autoimmune hemolytic anemia. *J Gastroenterol* 2000;35:245-9.
12. Lazaridis KN, Talwalkar JA: Clinical epidemiology of primary biliary cirrhosis: incidence, prevalence, and impact of therapy. *J Clin Gastroenterol* 2007;41:494–500.