



## Congenital cholesteatoma of the middle ear – uncommon clinical presentation

### Neobična klinička prezentacija kongenitalnog holesteatoma srednjeg uva

Bojana Bukurov, Borivoj Babić, Milovan Dimitrijević, Miljan Folić,  
Nenad Arsović

Clinic for Otorhinolaryngology and Maxillofacial Surgery, Clinical Center of Serbia,  
Faculty of Medicine, University of Belgrade, Belgrade, Serbia

#### Abstract

**Introduction.** Congenital cholesteatoma of the middle ear is an uncommon and yet not well-defined disease. Only few cases of cholesteatoma in the *fossa ovalis* with unusual clinical presentation have been reported in medical literature. **Case report.** We reported a 16-year-old girl with congenital cholesteatoma in the *fossa ovalis* with minimal clinical presentation. A small mass was found occluding the *fossa ovalis* and mimicking otosclerotic process within tympanic cavity. The operation started as stapedotomy, and when the process was confirmed it converted to mastoidectomy *via* the retroauricular approach. **Conclusion.** The diagnosis of congenital cholesteatoma in children should always be considered, even if the clinical symptoms imitate other ear disorders, in our case otosclerosis.

#### Key words:

cholesteatoma; congenital abnormalities; ear, middle; diagnosis; otorhinolaryngologic surgical procedures.

#### Apstrakt

**Uvod.** Kongenitalni holesteatom lokalizovan u kavumu timpani retko je oboljenje, još uvek nerazjašnjene etiologije. Do sada je objavljeno samo nekoliko radova u medicinskoj literaturi o kongenitalnom holestatomu u ovalnom prozoru sa minimalnom kliničkom prezentacijom. **Prikaz bolesnika.** Prikazana je 16-godišnja devojčica sa kongenitalnim holesteatomom lokalizovanim u ovalnom prozoru sa minimalnim kliničkim simptomima. Pronađen je mali holesteatom koji je u potpunosti ispunjavao fosu ovalis i imitirao otosklerotični proces u kavumu timpani. Operacija je započeta kao stapedotomija, a kada je proces konstatovan, nastavljena je kao mastoidektomija kroz retroaurikularni pristup. **Zaključak.** Trebalo bi uvek razmotriti dijagnozu kongenitalnog holesteatoma kod dece, čak i kada simptomi imitiraju neko drugo oboljenje srednjeg uva, u našem slučaju otoskleroza.

#### Ključne reči:

holesteatom; anomalije; uvo, srednje; dijagnoza; hirurgija, otorinolaringološka, procedure.

#### Introduction

Congenital cholesteatoma is relatively uncommon condition. It is defined as the whitish mass behind an intact eardrum, in a patient with no history of ear trauma or previous surgery and with no retraction pocket, perforation or granulation tissue that can be detected on the surface of an eardrum<sup>1</sup>. The term “congenital” has been used rather conventionally because the pathogenesis of congenital cholesteatoma remains unclear. Various hypotheses suggest anything from development during the fetal period to a condition acquired during infancy<sup>2</sup>. Almost any recently published paper emphasizes the importance of early diagnosis and intervention, as late diagnosis may be associated with extensiveness of the disease.

In spite of reports suggesting the age at the time of surgery being an important factor that affects treatment outcome, and widely accepted fact that congenital cholesteatoma increases over the time, there is no firm evidence in the literature confirming such relationship.

Usual age at the time of diagnosis is 4–5 years, and 70% of patients are asymptomatic at that point<sup>3</sup>.

We reported a patient with congenital cholesteatoma in the *fossa ovalis* with minimal clinical symptoms, presenting as an otosclerotic process within tympanic cavity.

#### Case report

A 16-year-old female patient was referred to the Clinic for Otolaryngology due to the right-sided hearing loss that

was diagnosed two years before. The patient had no previous history of *otitis media*, middle ear trauma, or any previous ear surgery.

Otoscopic examination showed intact tympanic membranes on both sides, although the right membrane had tympanosclerotic plaque in its anterior-inferior quadrant. There were no symptoms related to the vestibular system, nose or throat. Audiometric evaluation revealed mild conductive hearing loss of about 40 dB on the right side with a dip of bone conduction at 4 kHz (Figure 1). Stapedius reflex was absent on the same side. The results of general physical examination and routine laboratory and blood chemistry tests were within normal range.

temporalis fascia and TTP™ (Tuebingen Titanium Prosthesis, AERIAL) was implanted between the malleus and stapes footplate.

Four years after the surgery, there were no signs of relapse and liminar tonal audiometry of the right ear showed closure of air bone gap within the 10 dB.

### Discussion

Generally, the initial otologic symptom in a patient with open type of cholesteatoma is hearing loss, and in some cases, a white mass can be seen through tympanic membrane<sup>3</sup>. Many of these patients are unaware of their hearing loss, especially

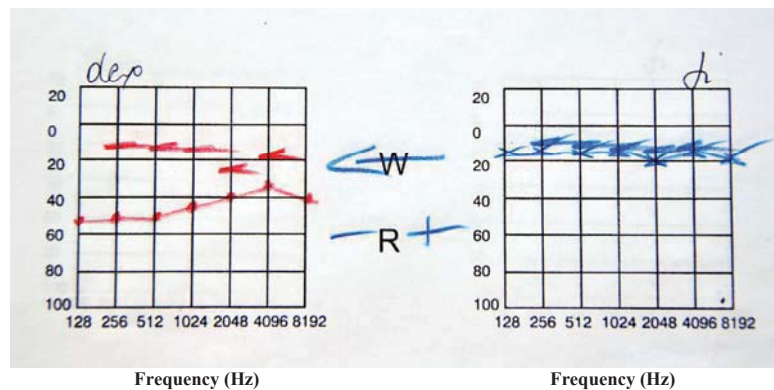


Fig. 1 – Preoperative liminar tonal audiogram.

Computed tomography (CT) of the temporal bone was performed and the findings in the middle ear appeared normal, with normally aerated and pneumatized mastoid cells.

Based on these findings, explorative surgery was performed on the right ear with the presumptive diagnosis of otosclerosis. Open type cholesteatoma was found obliterating oval window (Figure 2). The long process of incus and head

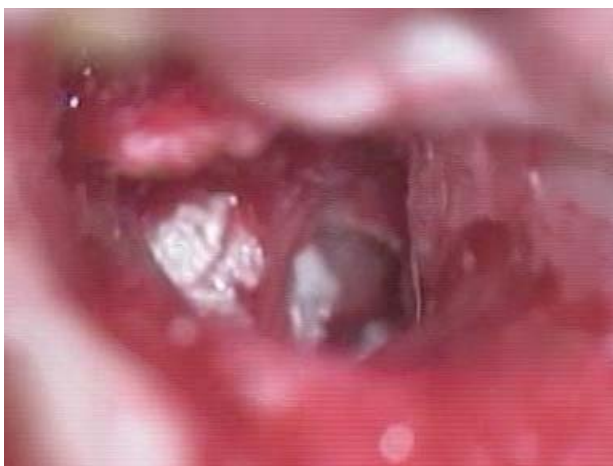

Fig. 2 – Intraoperative findings showing a cholesteatoma in the fossa ovalis.

of stapes was missing. Due to the findings, operation was continued as mastoidectomy and posterior tympanotomy in order to completely remove the process. After removal of cholesteatoma, mobile stapes footplate was covered with

because it is manifested in childhood. Most of congenital cholesteatoma in the middle ear are detected early in life, but our patient was 16-years-old when first referred to our Clinic, and had no previous history of any ear, nose or throat condition.

The primary localization of open type cholesteatoma, as suggested by many authors, is around the oval window, the same as in the presented patient. From there, it may spread to epitympanic recess, mastoid antrum, or to mesotympanum<sup>4,5</sup>.

Congenital cholesteatoma commonly develops in the isthmus of the tympanic cavity and the most frequent ossicular malformations are involvements of a long process of the incus and suprastructures of stapes in more than 60% of patients<sup>3,6,7</sup> corresponding to the junction of the first and second branchial arches. As congenital cholesteatoma tends to spread into the posterior-superior part of tympanic cavity, the fact that the suprastructure of stapes was affected in the presented patient suggested congenital origin of cholesteatoma.

Mastoid pneumatization in our patient was normal and these findings are in accordance with Iino et al.<sup>8</sup> and other authors<sup>9,10</sup> who reported better pneumatization in patients with congenital, compared to acquired cholesteatoma.

The initial symptom, intact tympanic membrane, audiological findings, and normal CT scans suggested an otosclerotic process in the middle ear, the diagnosis being supported by the age of the patient at the time of detection of hearing loss. However, these findings were proved to be misleading in the presented patient. There are few other cases in the lit-

erature describing congenital cholesteatomas that have been silent for many years or have been accompanied with minimal clinical presentation<sup>4,11</sup>.

### Conclusion

The diagnosis of congenital cholesteatoma should always be considered, even if the clinical symptoms mimic other ear disorders, in our case otosclerosis. In some cases, such as this one, even CT findings are not able to detect

cholesteatoma. Therefore, clinicians should always keep high level of cautiousness when dealing with young patients who present with hearing loss as the only symptom in order to deliver early treatment and improve final outcome.

### Acknowledgements

The study was supported within project from Ministry of Education, Science and Technological Development of the Republic of Serbia "Cochlear implantation impact on education of deaf and hearing-impaired" (No. 179055).

### R E F E R E N C E S

1. *Levine JL, Wright CG, Pawlowski KS, Meyerhoff WL.* Postnatal persistence of epidermoid rests in the human middle ear. *Laryngoscope* 1998; 108(1 Pt 1): 70–3.
2. *Persaud R, Hajiouf D, Trinidale A, Kbemani S, Battacharya MN, Papadimitriou N, et al.* Evidence-based review of etiopathogenic theories of congenital and acquired cholesteatoma. *J Laryngol Otol* 2007; 121(11): 1013–9.
3. *Lim HW, Yoon TH, Kang WS.* Congenital cholesteatoma: clinical features and growth patterns. *Am J Otolaryngol* 2012; 33(5): 538–42.
4. *Kojima H, Tanaka Y, Shiwa M, Sukurai Y, Moriyama H.* Congenital cholesteatoma clinical features and surgical results. *Am J Otolaryngol* 2006; 27(5): 299–305.
5. *McGill TJ, Merchant S, Healy GB, Friedman EM.* Congenital cholesteatoma of the middle ear in children: a clinical and histopathological report. *Laryngoscope* 1991; 101(6 Pt 1): 606–13.
6. *Wang R, Zubick HH, Vernick DM, Strome M.* Bilateral congenital middle ear cholesteatomas. *Laryngoscope* 1984; 94(11 Pt 1): 1461–3.
7. *Levenson MJ, Michaels L, Parisier SC, Juarbe C.* Congenital cholesteatomas in children: an embryologic correlation. *Laryngoscope* 1988; 98(9): 949–55.
8. *Iino Y, Imamura Y, Hiraishi M, Yabe T, Suzuki J.* Mastoid pneumatization in children with congenital cholesteatoma: an aspect of the formation of open-type and closed-type cholesteatoma. *Laryngoscope* 1998; 108(7): 1071–6.
9. *Warren FM, Bennett ML, Wiggins RH 3rd, Saltzman KL, Blevins KS, Shelton C, et al.* Congenital cholesteatoma of the mastoid temporal bone. *Laryngoscope* 2007; 117(8): 1389–94.
10. *Mevio E, Gorini E, Sbrocca M, Artesi L, Lenzi A, Lecce S, et al.* Congenital cholesteatoma of mastoid origin. *Otolaryngol Head Neck Surg* 2002; 127(4): 346–8.
11. *Lee JH, Hong SJ, Park CH, Jung SH.* Congenital cholesteatoma of mastoid origin. *J Laryngol Otol* 2007; 121(11): e20.

Received on April 29, 2012.

Revised on February 13, 2013.

Accepted on February 27, 2013.