



Acute bacterial meningitis and stroke

Jason L. Siegel

Department of Neurology, Department of Critical Care Medicine, Department of Neurosurgery, Mayo Clinic, Jacksonville, Florida, USA

ABSTRACT

Introduction. Acute bacterial meningitis remains a common disease, especially in developing countries. Although advances over the last century have improved mortality and morbidity, the neurological adverse effects remain high. Specifically, acute ischaemic stroke is a serious comorbidity that represents both disease severity and poor prognosis. This review presents the clinical connection between meningitis and stroke, and discusses the neuroinflammatory components that have direct ties between these diseases.

State of the art. Ischaemic stroke is the direct result of the inflammatory response produced to eradicate infectious pathogens. Bacterial virulence factors and pathogen-associated molecular patterns cause direct damage to the blood-brain barrier and trigger leukocytes to react to the infection. Cytokines are released that cause further destruction of the blood-brain barrier, lead to neuronal death, and recruit the prothrombotic effects of the coagulation cascade through the complement system. Unfortunately, this inflammatory response causes vasculopathy and hypercoagulation of the cerebral blood vessels, leading to cerebral ischaemia.

Clinical implications. Pharmacological attempts to mitigate this inflammatory response have produced both positive and negative results. On the one hand, corticosteroids have been shown to improve mortality if given early in patients with bacterial meningitis, particularly pneumococcal meningitis. On the other hand, corticosteroids have been linked to delayed cerebral infarction and other adverse effects.

Future directions. New targets for specific inflammatory markers have shown success in rodent models, but have not yet been proven beneficial in humans. Genetic markers are on the horizon, and may serve as individualised targets for diagnosis and therapy.

Key words: bacterial meningitis, neuroinflammation, pneumococcal meningitis, stroke

(*Neurol Neurochir Pol* 2019; 53 (4): 242–250)

Introduction

Acute bacterial meningitis (ABM) has an incidence in developed countries of between 0.7 and 0.9 per 100,000, but its incidence remains as high as 40 per 100,000 in developing countries [1]. Risk factors for ABM are those which cause an immunocompromised state, and include age (infants and > 65 years), splenectomy or hyposplenia, HIV/AIDS, cancer, organ transplant, and nutritional states such as diabetes mellitus and alcoholism [2]. Environmental factors, specifically warmer climates, also increase the risk of some causes of ABM [3]. Before the introduction of antibiotics in the 1930s, ABM was nearly universally fatal [4]. In subsequent decades,

pathogen-specific antimicrobials, vaccinations toward encapsulated pathogens, and the addition of corticosteroids into treatment management have all contributed to improving rates of mortality and morbidity [1]. Prior to incorporating corticosteroids into acute treatment regimens, mortality was from 19% to 24%, and serious morbidity 34% to 52% [5–7]. Even with contemporary treatment plans, mortality remains as high as 20% in some reports [8–10]. One particular adverse effect of ABM is cerebral ischaemia (CI), which is both an indicator of ABM disease severity, and an independent predictor of a poor clinical outcome.

In this review, we will discuss the association and causes of CI in ABM, describe the clinical consequences of the

Address for correspondence: Jason L. Siegel, MD, Department of Neurology, Mayo Clinic, 4500 San Pablo Rd, Jacksonville, FL 32224, USA,
e-mail: Siegel.Jason@mayo.edu

inflammatory response to ABM, and analyse how current treatment modalities, particularly corticosteroids, may have both positive and negative consequences on ABM. We will limit ABM to encapsulated pathogens (*Streptococcus pneumoniae*, *Neisseria meningitidis*, and *Haemophilus influenzae*) because these are the most common causes of meningitis, and the best-studied in regards to CI.

CI and ABM

Before contemporary treatment regimens, between 50% and 75% of patients with ABM had a neurological or systemic adverse event [5, 6]. Among the most common acute neurological adverse effects were cerebrovascular disease (10–29%), cerebral oedema (14–29%), hydrocephalus (12–16%), and intracerebral haemorrhage (1–9%) [5, 6, 11, 12].

Patients with ABM-associated CI have high mortality (46%) and morbidity (38–62%) [12, 13]. Risk factors for CI include otitis or sinusitis, and being immunocompromised [12, 14]. Patients who present with a lower Glasgow Coma Scale (GCS) score, lower levels of cerebrospinal fluid (CSF) leukocytes, and higher serum erythrocyte sedimentation rates, also have a higher risk of CI [12, 14]. There are conflicting reports regarding the risk of age and developing CI [12, 14]. Treatment with dexamethasone has been reported as not being a risk factor [14].

Early angiographic studies revealed several potential pathologies for CI, including arterial narrowing, vessel wall irregularities, focal dilatations, arterial occlusions, and thrombosis of the venous sinuses and cortical veins [13]. Interestingly, whether these findings correlate directly with any clinical neurological symptoms has not been reported, and it is not known if these findings could represent acute or chronic vasculopathy, or if any patients had infective endocarditis (IE).

Increased cerebral blood flow velocity, another marker of cerebral vasculopathy and arterial narrowing, is related to ABM-associated CI and poor outcomes [15]. In a retrospective study, an increase in transcranial Doppler cerebral blood flow velocity of greater than 150 cm/s correlated with a poor clinical grade on presentation, an increased risk of CI [odds ratio (OR), 9.15; $P < 0.001$], and an unfavourable outcome (Glasgow Outcome Score, < 4 ; OR, 2.93; $P = 0.018$). Timing of the transcranial Doppler in the disease course was not standardised, and there were limitations to the conclusions. Of the 41 patients studied, 20 underwent either computed tomography angiography, magnetic resonance angiography, or digital subtraction angiography to characterise the vasculopathy, but only nine had evidence of vascular narrowing revealed by these methods [15].

Vasospasm and vasculitis are not the sole causes of CI. ABM, especially severe ABM, affects the coagulation cascade, causing intravascular thrombus formation [16]. Cerebral thrombosis commonly occurs in pneumococcal meningitis (PM), even without CI or vasculitis. In a case series of

16 patients who died of ABM, nine had CI, but five of these did not have pathological evidence of vasculitis, and none had evidence of large vessel vasculitis [11]. Of the four patients with vasculitis, all had intra-arterial thrombosis [11].

ABM can cause CI by other, less common, mechanisms. Though a rare occurrence in meningitis (~ 2% [17]), IE is a potential source of cerebral infarction. Conversely, ABM occurs in 1–20% of patients with IE [18]. In the co-occurrence of IE and ABM, the ischaemic stroke rate has been reported to be 38%, higher than in either IE or ABM alone [17]. Swift treatment is vital because the risk of stroke decreases by 65% after one week of antibiotic therapy [19]. In addition, either ABM or IE can be the primary source of infection. It has been reported that acute IE (usually caused by *Staphylococcus aureus*) compared to subacute IE (usually caused by viridans streptococci) is more associated with strokes and CSF profiles with neutrophilic pleocytosis, decreased glucose, and positive culture (bacterial meningitis) [20]. Alternatively, ABM, especially PM, can spread systemically, causing acute IE.

Regardless of the primary source, if either ABM or IE is suspected, a thorough clinical examination is necessary, including trending fever curves, and looking for cardiac murmur, Janeway lesions, Roth spots, Osler nodes, nuchal rigidity, and Kernig and Brudzinski signs. All patients with ABM should have blood cultures and a transthoracic echocardiogram to screen for IE.

Finally, CI can be caused by systemic inflammatory responses to ABM, including septic shock (11.6%), acute respiratory distress syndrome (3.5%), and disseminated intravascular coagulation (8.1%) [5]. Studies in rabbits have shown that, like many acute brain injuries, cerebrovascular autoregulation is lost during sepsis [21]. Patients, therefore, can develop watershed strokes during this period of poor cerebral autoregulation and hypoperfusion.

For the purposes of this review, we will focus on the two primary mechanisms by which ABM causes CI: firstly inflammatory vasculopathy (including vasculitis and vasospasm), and secondly intravascular thrombus formation. Radiographic and pathological studies have differed in the predominance of these mechanisms and how these vascular changes cause clinical changes.

Delayed CI

In between 1% and 4% of cases of ABM, patients will have good clinical recoveries initially, but after the first week will develop acute changes in their level of consciousness or develop new focal neurological signs [17, 22, 23]. These abrupt changes are commonly due to delayed CI (DCI). One report described a series of six patients with posterior circulation predominant DCI which occurred more than a week after the initial presentation [22]. After initial treatment, the CSF of these patients became less inflammatory, but developed increased white blood cell count and protein at the time of deterioration. Repeat CSF analyses had negative cultures

and gram stains, suggesting a noninfectious aetiology to the relapsing meningitis. Prognosis was poor as four of these six patients died and two remained disabled. Autopsies on two of these patients showed normal macroscopic vessels without evidence of vasculitis, but with focal thrombi in perforating arteries [22].

In another postmortem study of patients who died from ABM, there was extensive inflammation in the meninges and blood vessels with thrombosis, infarction, and deposition of immunoglobulins M and G in the meninges [24]. There were no differences in these findings between DCI and non-DCI deaths. They also found pneumococci capsules in the meninges as much as 35 days after onset, suggesting that the stimulus for inflammation can remain in the meninges even weeks after treatment [24].

Another study reported that nearly 60% of ABM-related cerebrovascular events occurred more than six days after onset [25], with all patients having an initial improvement of CSF parameters. Pathological studies were not completed, but in these patients there was radiographic evidence of vasculopathy. The most common ischaemic mechanisms were vasospasm and vasculitis, with a larger proportion in the frontal lobe and middle cerebral artery [25].

As with CI, the causes of ABM-associated DCI vary. Inflammatory vasculopathy, including vasospasm and vasculitis, has been seen angiographically, but not always pathologically. Conversely, pathology can reveal thrombosis and signs of hypercoagulation in vessels not identified on angiography. Most likely, both vasculopathy and hypercoagulation are important causes of CI and DCI.

Thus the question is: Why does ABM cause inflammatory vasculopathy and hypercoagulation leading to CI and DCI? The answer lies in the inflammatory cascade initiated by ABM.

Inflammatory response to bacterial invasion of the meninges

What follows the inoculation of an infectious microbial into the subarachnoid space is a reactive inflammatory response designed to destroy and eliminate the infectious pathogen. Bacteria use a variety of virulence factors to invade the subarachnoid space. Initially, bacteremia induces an inflammatory response of the cerebrovascular epithelial cells. Highly vascular areas, such as the leptomeninges, or areas with blood-CSF barriers such as the choroid plexus, are the most likely points of entry from haematogenous spread [26–28]. After bacterial invasion, leukocytes (predominantly neutrophils) quickly migrate into the subarachnoid space. Both bacteria and neutrophils undergo reactions that rapidly increase the inflammatory response, resulting in vasodilatation, breakdown of the blood-brain and blood-CSF barriers, and further migration and activation of inflammatory cells (Fig. 1).

Based on the specific stimulating factor, leukocytes will produce a variety of noncellular inflammatory molecules,

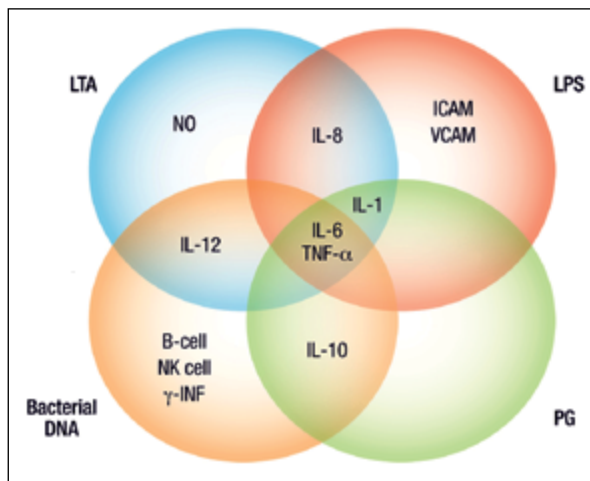


Figure 1. Basic mechanisms of bacterial chemotaxis, drivers of inflammation, and vascular consequences. A, Virulence factors and adhesive proteins, such as CbpA and PilC1, interact with endothelial cells to promote bacterial adhesion and endocytosis. Endothelial cells react by expressing ICAM-1 which binds to LFA-1 (integrin) on leukocytes to promote migration. These leukocytes also produce TNF- α and NO synthetase. Leukocytes are then able to permeate into the CSF relatively soon after infiltration of the bacteria and result in NO and MMPs, further damaging the BBB and BCB. Pneumolysin, haemolysin/cytolysin, and H₂O₂ are bacterial toxins that stimulate apoptosis, inducing factor caspases, ultimately causing mitochondrial and neuronal death. Bacteria also produce PAMPs of PG, LP, and LPS, which induce indirect neurotoxicity by activation of PRRs on microglia, and promote TLR2 and TLR4 on leukocytes, resulting in neural death. B, The ultimate cerebrovascular consequences of these reactions are: contraction of perivascular smooth muscle, causing vasospasm and vasculitis; activation of the coagulation cascade, causing intravascular thrombi; and breakdown of the vascular basement membrane, causing diffusion of protein and water resulting in cerebral oedema
BBB — blood-brain barrier; BCB — blood-cerebrospinal fluid barrier; Cbp — curved DNA-binding protein; CSF — cerebrospinal fluid; ICAM — intercellular adhesion molecule; LFA — lymphocyte function-associated antigen; LP — lipoprotein; LPS — lipopolysaccharide; LTA — lipoteichoic acid; MMP — matrix metalloproteinases; NO — nitric oxide; PAF — platelet-activating factor; PAMPs — pathogen-associated molecular patterns; PG — peptidoglycan; PilC — pilin biogenesis protein; PRRs — pattern recognition receptors; TLR — toll-like receptor. Used with permission of Mayo Foundation for Medical Education and Research. All rights reserved

such as cytokines and chemokines [29] (Fig. 2). Of these, the most commonly expressed include interleukin (IL)-6 and tumour necrosis factor (TNF)- α , followed by IL-1, IL-8, and IL-10 (Tab. 1). Importantly, the liver synthesises the components of the complement cascade, which connect the inflammatory process to the coagulation cascade. The end products of the complement cascade are C5a, C3a, and C5b (which combines with C9 to create the C5a–C9 membrane-attack complex). C5a stimulates tissue factor, which is the pivotal initiator of

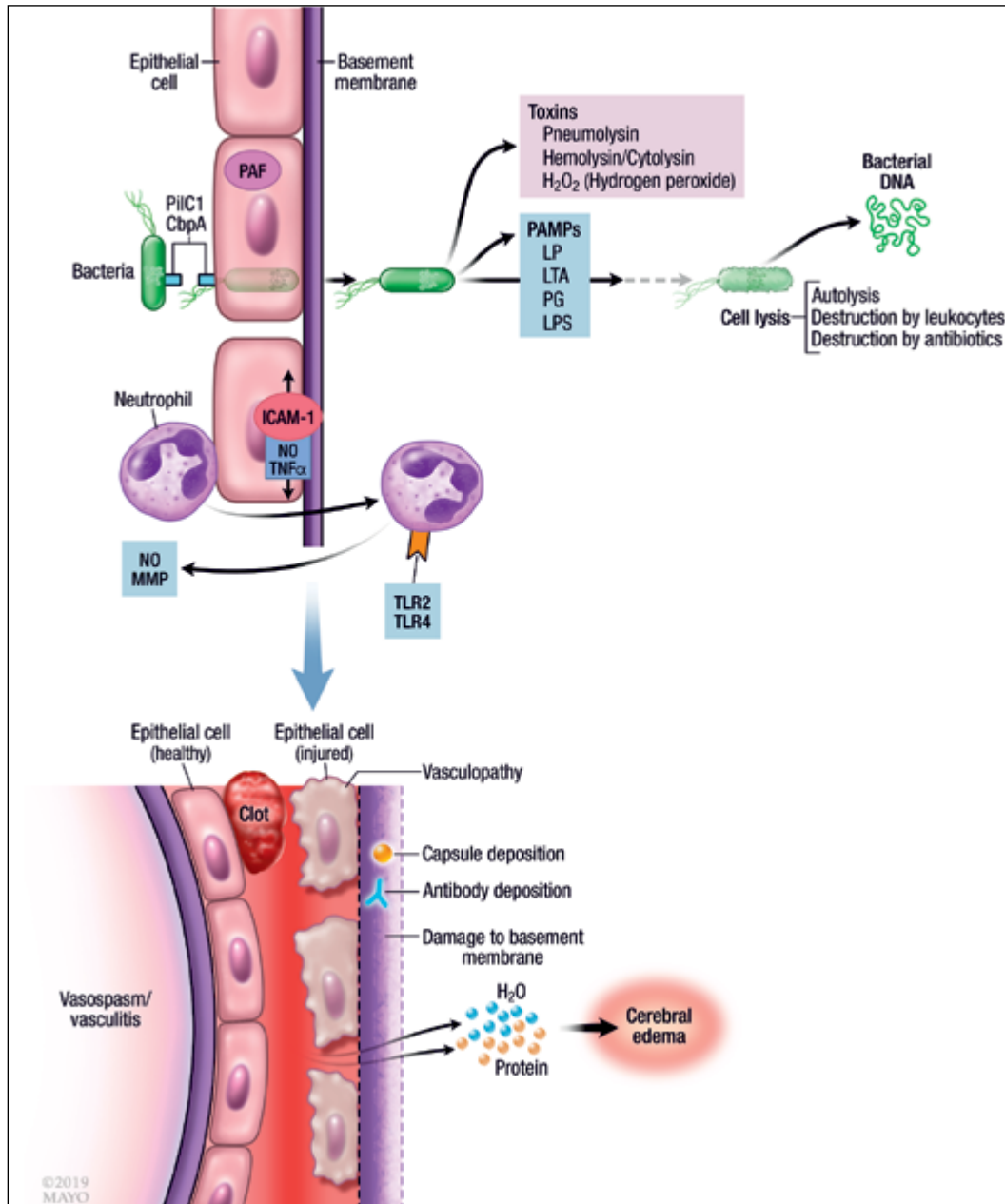


Figure 2. Cytokines and pathogen-associated molecular patterns (PAMPs). Four common PAMPs (LTA, LPS, PG, and bacterial DNA) stimulate the production of various cytokines, with overlap between the PAMPs. IL-6 and TNF- α are stimulated by all four PAMPs. ICAM — intercellular adhesion molecule; IL — interleukin; INF — interferon; LPS — lipopolysaccharide; LTA — lipoteichoic acid; NK — natural killer; NO — nitric oxide; PG — peptidoglycan; VCAM — vascular cell adhesion molecule. Used with permission of Mayo Foundation for Medical Education and Research. All rights reserved.

inflammation-induced thrombin generation [30] and stimulates factor Xa of the coagulation cascade. Factor Xa continues to cleave prothrombin into thrombin, which then converts fibrinogen to soluble fibrin. Another role of C5a is to stimulate plasminogen activator inhibitor-1, with the end result of decreased plasmin, and thus decreased thrombolysis. In turn, the coagulation cascade affects the complement cascade in that factor XIIa stimulates the classical complement pathway and thrombin stimulates C5 convertase [31]. The downstream

results of this inflammatory response include cerebral oedema, coagulopathy, and direct damage to the neurons, vasculature, basement membranes of the blood-brain and blood-CSF barriers, and ependymal layer of the ventricles [32].

Clinical effects of inflammatory cytokines

Cytokines serve as potential biomarkers for associating the inflammatory response during meningitis with diagnosis,

Table 1. Roles of cytokines

Cytokine	Source	Function
IL-1, TNF	Macrophages, monocytes, dendritic cells, endothelial cells	<ul style="list-style-type: none"> — Initiate PGE2 in anterior hypothalamus → fever — Alter endothelial cell adhesion molecules — Increase liver synthesis of: <ul style="list-style-type: none"> • Ferritin • Fibrinogen • C-reactive protein — Increase release of neutrophils from bone marrow and transendothelial neutrophil passage [27] — IL-1 may be more potent in BBB destruction [28] — TNF promotes apoptosis
IL-6		— Increase liver synthesis of acute phase reactants
IL-8		— Chemotaxis
C3a, C5a (anaphylatoxins)	Liver	— Mast cell release of histamine
C3b		— C5a → activation of neutrophil adhesion molecules
C5a-C9 (MAC)		— Opsonisation (antibody-mediated phagocytosis)
Histamine	Mast cells, platelets, enterochromaffin cells	— Cell lysis
Nitric oxide	Macrophages, endothelial cells; free radical gas released during conversion of arginine to citrulline by nitric oxide synthase	— Vasodilation
Serotonin	Platelets	— Increased venular permeability
		— Vasodilation
		— Bactericidal
		— Increased venular permeability
		— Increased collagen synthesis

BBB — blood-brain barrier; IL — interleukin; MAC — membrane-attack complex; PGE2 — prostaglandin E2; TNF — tumour necrosis factor

disease severity, adverse effects (including stroke), prognosis, and treatment.

ABM is traditionally diagnosed by CSF analysis, specifically by measuring cell counts, leukocyte differential, protein, and glucose, and is ultimately confirmed using gram stain and bacterial culture. However, sometimes these metrics can be inconsistent or inconclusive, especially if antibiotics were administered hours before CSF collection. Inflammatory biomarkers have been shown to be associated with both a positive diagnosis and differentiation of ABM.

In infants younger than six months, IL-6 and IL-10 have been shown to have a strong association with the diagnosis of ABM, even after antibiotics have been administered (area under the receiver operating characteristic curve 0.91 and 0.91, respectively). TNF- α had an area under the curve of 0.88 [33].

In an example of ABM differentiation, CSF levels of IL-1 β , IL-2, IL-6, TNF- α , interferon- γ , IL-10, IL-1Ra, IL-8 (CXC chemokine ligand 8), CC chemokine ligand 2 (monocyte chemoattractant protein 1), CC chemokine ligand 3 (macrophage inflammatory protein 1 α), CC chemokine ligand 4 (macrophage inflammatory protein 1 γ), and granulocyte-colony

stimulating factor were investigated in patients with either PM or meningococcal meningitis. Interferon- γ was significantly higher in PM compared to meningococcal meningitis. When the study of CSF was limited to the 48 hours following symptom onset, TNF- α was higher in meningococcal meningitis than PM [34].

CSF cytokines are also correlated with disease severity and prognosis. In 1995, CSF from patients with meningitis was tested for IL-1 β , TNF- α , and IL-6. The presence of these CSF cytokines correlated with higher levels of CSF protein and lower CSF glucose, as well as prolonged fever, “fits and spasticity”, and death [35]. Although unable to fully illuminate the mechanisms and so delineate why only some patients had these cytokines, these early studies began to build a connection between meningitis and specific inflammatory markers in the cascade.

These results were more recently supported when it was found that in patients with non-meningitis related sepsis, not only were cytokine levels higher in the CSF than in plasma, but also levels of CSF IL-6, IL-8, IL-10, IL-1 β , and TNF- α , and plasma IL-10 and IL-12p70 were significantly higher in patients with severe sepsis than in those with sepsis [36].

Additionally, higher CSF levels of IL-6 and IL-12p70 were correlated with worse long-term outcomes [36].

The complement cascade is also associated with disease severity. In normal mice with induced PM, C5a and terminal complement complex (TCC) levels increase from 24 to 48 hours. However, mice deficient of C5a receptor (*C5ar1*^{-/-}) had a less robust inflammatory response and better clinical outcomes. When anti-C5-Abs were administered intrathecally, mice had lower meningitis-related adverse effects and better clinical status compared to systemic administration. In fact, there was no mortality in these mice, and the anti-C5 antibodies outperformed dexamethasone administration [37].

Likewise, higher CSF levels of C5a and TCC in human patients with PM correlated with poor GCS on presentation, high CSF protein and white blood cell count, death, and overall unfavourable outcomes [37]. Median CSF levels of C5a and C5b-9 were higher in patients with ABM-associated DCI than in patients without DCI, although complement levels in patients without DCI were heavily skewed, with several levels higher than observed DCI levels [17]. Therefore, a threshold cannot be established for prediction of DCI.

The increased complement activation also affects the coagulation cascade. Compared to normal patients or those with viral encephalitis, CSF in patients with ABM has higher levels of soluble tissue factor, prothrombin, and plasminogen activator inhibitor-1 [16]. The net effect of these markers is enhanced coagulation and attenuation of fibrinolysis [11].

Clinical implications

The inflammatory response associated with ABM prompted investigation into the use of anti-inflammatory medications to prevent comorbidity. In a landmark trial, dexamethasone was given to patients in conjunction with their initial antibiotics, and when compared to a placebo, showed a lower risk of unfavourable outcome [15% vs. 25%; $P = 0.03$; number needed to treat (NNT), 10], death (7% vs. 15%; $P = 0.04$; NNT, 12.5), impairment of consciousness (11% vs. 25%; $P = 0.002$), seizures (5% vs. 12%; $P = 0.04$), and cardiorespiratory failure (10% vs. 20%; $P = 0.02$) [38]. However, these results were heavily skewed by *Streptococcus pneumoniae*, which was the only pathogen that showed a decreased risk of an unfavourable outcome (26% vs. 52%; $P = 0.006$; NNT, 3.8) or death (14% vs. 34%; $P = 0.02$; NNT, 5) with dexamethasone when compared to a placebo. Patients with PM who received dexamethasone still did poorly compared to the other individual pathogens, highlighting the severe nature of this disease, but suggesting that a large part of its danger is a potentially treatable inflammatory response [38].

Importantly, stroke was not an outcome measure, and its incidence between treatment and control arms was not reported. Because of this study, corticosteroids became part of the standard of care in undifferentiated ABM, though again the effects were perhaps only helpful on PM [39].

After the routine use of dexamethasone in ABM, conflicting reviews and meta-analyses were reported on its usefulness [8–10, 15, 17, 22, 25, 40]. After the implementation of dexamethasone as the standard treatment in ABM throughout the Dutch healthcare system, they observed a 15% decrease in neurological adverse effects, a 10% decrease in deaths, an 11% increase in rate of no or minor disability, an 11% decrease in cranial nerve palsy, and a 10% decrease in hearing impairments [10]. A single centre study found that after initiation of corticosteroids, mortality fell from 24.1% to 5.5% [8]. In a 2015 Cochrane review, corticosteroids were found to reduce hearing loss in children with *Haemophilus influenzae* and mortality in those with PM [9].

However, a meta-analysis of five trials and more than 2,000 patients showed that dexamethasone administration was not associated with a decreased risk of death, disability, or poor functional outcome in all patients, or in any specified subgroup [40]. In fact, the results did not even support the use of dexamethasone in PM [40].

Some studies have suggested that not only might adjunct corticosteroids have a limited role in improving outcome or preventing adverse effects or stroke, but that they might even cause harm. In one case series, corticosteroid use was found in most patients who developed DCI; although most patients who received corticosteroids did not experience DCI, and DCI developed in some patients who did not receive steroids [17]. Furthermore, the study did not report ORs or relative risks of corticosteroids and DCI [17]. Another study reported that all five patients with DCI received corticosteroids, whereas 43 of 115 patients who did not experience DCI received corticosteroids (OR, 13.29) [25]. In this study, the use of corticosteroids appeared to increase the risk of DCI, but it should be pointed out that most patients (90%) who received corticosteroids did not experience DCI. All patients had an initial improvement of CSF parameters, but were severely affected clinically. Only 30% of all ABM patients even received corticosteroids, far less than typically seen as the standard of care [25]. Another series of six patients reported posterior circulation-predominant DCI occurring more than a week after the initial presentation [22]. All patients received corticosteroids and had a good initial recovery before acute deterioration [22]. It has also been reported that patients who received corticosteroids were more likely to have an increase in cerebral blood flow velocity by transcranial Doppler than those who did not (OR, 2.86; $P = 0.026$), suggesting corticosteroids to be a potential cause of vasculopathy [15]. The authors recognised that in this retrospective study (which included patients prior to the corticosteroid era), many patients probably received corticosteroids because they were not recovering with antibiotics, and so they could not determine whether the severe disease or the corticosteroids directly caused cerebrovasoconstriction [15].

The mechanism of corticosteroid-induced DCI has not yet been fully explained, and reports that describe this association have not been validated by large prospective trials.

Nonetheless, there is a strong relationship between the inflammatory response to ABM and outcomes.

Future directions

Despite the inconsistent results of corticosteroids in reducing comorbidity and stroke, there is still a clear link between the neuroinflammatory response during ABM and the risk of CI. Beyond corticosteroids, our knowledge of cytokines and complement markers has not been incorporated into standard treatment plans. Future work will examine novel anti-inflammatory drugs and genetic targets.

Targeting specific components of the inflammatory cascade has shown promise in animal models. In rats with PM, C1-inhibition reduced clinical illness, produced a less pronounced inflammatory infiltrate around the meninges, produced lower levels of proinflammatory cytokines, and increased bacterial clearance [41]. Intrathecal recombinant TNF-related apoptosis-inducing ligand decreased inflammation and neuronal apoptosis [42]. In an attempt to reduce the inflammatory response of bacteriolysis, the nonbacteriolytic antibiotic, daptomycin, was shown to clear the bacteria faster, reduce matrix metalloproteinase-9 levels, and prevent the development of cortical injury when compared to ceftriaxone [43]. However it must be stressed that these experiments were conducted in rodents, without suitable human trials.

There is hope, however, in trialling specific immunotherapies to reduce central nervous system inflammation from ABM, in much the same way the IL-6 receptor inhibitor, tocilizumab, has been shown to reduce seizure burden in new onset refractory status epilepticus [44].

There are also strong associations between genetics and mortality and disease severity. Polymorphisms in *SERPINE1* and IL-1 β are associated with mortality [45]. The single nucleotide polymorphism, rs17611, plays a role in C5 production (GG genotype) and is associated with an unfavourable outcome (OR, 2.25; $P = 0.002$) [37]. In multivariate regression analysis, including age, CSF white blood cell count, GCS score, blood thrombocyte count, immunocompromised state, otitis media, and sinusitis, rs17611 remained a strong predictor of an unfavourable outcome (OR, 1.91; $P = 0.032$). It is worth noting that there was no significant association between CSF C5a or TCC levels and rs17611 genotype [37].

Conclusion

ABM remains a serious disease with high rates of morbidity and mortality. Although great strides over the past century have dramatically improved its survivability and the functional outcomes of patients, current therapies do not appropriately target the components of the inflammatory response that occur with this disease. Acute CI, as a common and devastating comorbidity to ABM, is a direct result of this inflammatory reaction, by inflammatory vasculopathy and

hypercoagulability. Targeted drugs to reduce the inflammatory response to ABM may also decrease the incidence of CI. This, in turn, will improve survivability and functional outcomes.

Conflict of interest None.

Funding This publication was prepared without any external sources of funding.

References

1. Brouwer MC, van de Beek D. Epidemiology of community-acquired bacterial meningitis. *Curr Opin Infect Dis*. 2018; 31(1): 78–84, doi: [10.1097/QCO.0000000000000417](https://doi.org/10.1097/QCO.0000000000000417), indexed in Pubmed: [29176349](https://pubmed.ncbi.nlm.nih.gov/29176349/).
2. Adriani KS, Brouwer MC, van de Beek D. Risk factors for community-acquired bacterial meningitis in adults. *Neth J Med*. 2015; 73(2): 53–60.
3. Palmgren H. Meningococcal disease and climate. *Glob Health Action*. 2009; 2, doi: [10.3402/gha.v2i0.2061](https://doi.org/10.3402/gha.v2i0.2061), indexed in Pubmed: [20052424](https://pubmed.ncbi.nlm.nih.gov/20052424/).
4. Schwentker FF, Gelman S, Long PH. Landmark article April 24, 1937. The treatment of meningococcal meningitis with sulfanilamide. Preliminary report. By Francis F. Schwentker, Sidney Gelman, and Perrin H. Long. *JAMA*. 1984; 251(6): 788–790, doi: [10.1001/jama.251.6.788](https://doi.org/10.1001/jama.251.6.788), indexed in Pubmed: [6363729](https://pubmed.ncbi.nlm.nih.gov/6363729/).
5. Pfister HW, Feiden W, Einhäupl KM. Spectrum of complications during bacterial meningitis in adults. Results of a prospective clinical study. *Arch Neurol*. 1993; 50(6): 575–581, doi: [10.1001/archneur.1993.00540060015010](https://doi.org/10.1001/archneur.1993.00540060015010), indexed in Pubmed: [8503793](https://pubmed.ncbi.nlm.nih.gov/8503793/).
6. Kastenbauer S, Pfister HW. Pneumococcal meningitis in adults: spectrum of complications and prognostic factors in a series of 87 cases. *Brain*. 2003; 126(Pt 5): 1015–1025, doi: [10.1093/brain/awg113](https://doi.org/10.1093/brain/awg113), indexed in Pubmed: [12690042](https://pubmed.ncbi.nlm.nih.gov/12690042/).
7. van de Beek D, de Gans J, Spanjaard L, et al. Clinical features and prognostic factors in adults with bacterial meningitis. *N Engl J Med*. 2004; 351(18): 1849–1859, doi: [10.1056/NEJMoa040845](https://doi.org/10.1056/NEJMoa040845), indexed in Pubmed: [15509818](https://pubmed.ncbi.nlm.nih.gov/15509818/).
8. Buchholz G, Koedel U, Pfister HW, et al. Dramatic reduction of mortality in pneumococcal meningitis. *Crit Care*. 2016; 20(1): 312, doi: [10.1186/s13054-016-1498-8](https://doi.org/10.1186/s13054-016-1498-8), indexed in Pubmed: [27716447](https://pubmed.ncbi.nlm.nih.gov/27716447/).
9. Brouwer MC, McIntyre P, Prasad K, et al. Corticosteroids for acute bacterial meningitis. *Cochrane Database Syst Rev*. 2015(9): CD004405, doi: [10.1002/14651858.CD004405.pub5](https://doi.org/10.1002/14651858.CD004405.pub5), indexed in Pubmed: [26362566](https://pubmed.ncbi.nlm.nih.gov/26362566/).
10. Brouwer MC, Heckenberg SGB, de Gans J, et al. Nationwide implementation of adjunctive dexamethasone therapy for pneumococcal meningitis. *Neurology*. 2010; 75(17): 1533–1539, doi: [10.1212/WNL.0b013e3181f96297](https://doi.org/10.1212/WNL.0b013e3181f96297), indexed in Pubmed: [20881273](https://pubmed.ncbi.nlm.nih.gov/20881273/).
11. Vergouwen MDI, Schut ES, Troost D, et al. Diffuse cerebral intravascular coagulation and cerebral infarction in pneumococcal meningitis. *Neurocrit Care*. 2010; 13(2): 217–227, doi: [10.1007/s12028-010-9387-5](https://doi.org/10.1007/s12028-010-9387-5), indexed in Pubmed: [20526697](https://pubmed.ncbi.nlm.nih.gov/20526697/).
12. Schut ES, Lucas MJ, Brouwer MC, et al. Cerebral infarction in adults with bacterial meningitis. *Neurocrit Care*. 2012; 16(3): 421–427, doi: [10.1007/s12028-011-9634-4](https://doi.org/10.1007/s12028-011-9634-4), indexed in Pubmed: [21989842](https://pubmed.ncbi.nlm.nih.gov/21989842/).
13. Pfister HW, Borasio GD, Dirnagl U, et al. Cerebrovascular complications of bacterial meningitis in adults. *Neurology*. 1992; 42(8):

- 1497–1504, doi: [10.1212/wnl.42.8.1497](https://doi.org/10.1212/wnl.42.8.1497), indexed in Pubmed: [1641143](https://pubmed.ncbi.nlm.nih.gov/1641143/).
14. Katchanov J, Heuschmann PU, Endres M, et al. Cerebral infarction in bacterial meningitis: predictive factors and outcome. *J Neurol*. 2010; 257(5): 716–720, doi: [10.1007/s00415-009-5395-9](https://doi.org/10.1007/s00415-009-5395-9), indexed in Pubmed: [19946782](https://pubmed.ncbi.nlm.nih.gov/19946782/).
 15. Klein M, Koedel U, Pfefferkorn T, et al. Arterial cerebrovascular complications in 94 adults with acute bacterial meningitis. *Crit Care*. 2011; 15(6): R281, doi: [10.1186/cc10565](https://doi.org/10.1186/cc10565), indexed in Pubmed: [22112693](https://pubmed.ncbi.nlm.nih.gov/22112693/).
 16. Weisfelt M, Determann RM, de Gans J, et al. Procoagulant and fibrinolytic activity in cerebrospinal fluid from adults with bacterial meningitis. *J Infect*. 2007; 54(6): 545–550, doi: [10.1016/j.jinf.2006.11.016](https://doi.org/10.1016/j.jinf.2006.11.016), indexed in Pubmed: [17207860](https://pubmed.ncbi.nlm.nih.gov/17207860/).
 17. Lucas MJ, Brouwer MC, van de Beek D. Delayed cerebral thrombosis in bacterial meningitis: a prospective cohort study. *Intensive Care Med*. 2013; 39(5): 866–871, doi: [10.1007/s00134-012-2792-9](https://doi.org/10.1007/s00134-012-2792-9), indexed in Pubmed: [23248040](https://pubmed.ncbi.nlm.nih.gov/23248040/).
 18. Morris NA, Matiello M, Lyons JL, et al. Neurologic complications in infective endocarditis: identification, management, and impact on cardiac surgery. *Neurohospitalist*. 2014; 4(4): 213–222, doi: [10.1177/1941874414537077](https://doi.org/10.1177/1941874414537077), indexed in Pubmed: [25360207](https://pubmed.ncbi.nlm.nih.gov/25360207/).
 19. Dickerman SA, Abrutyn E, Barsic B, et al. ICE Investigators. The relationship between the initiation of antimicrobial therapy and the incidence of stroke in infective endocarditis: an analysis from the ICE Prospective Cohort Study (ICE-PCS). *Am Heart J*. 2007; 154(6): 1086–1094, doi: [10.1016/j.ahj.2007.07.023](https://doi.org/10.1016/j.ahj.2007.07.023), indexed in Pubmed: [18035080](https://pubmed.ncbi.nlm.nih.gov/18035080/).
 20. Cunha BA, Jimada I, Chawla K. Intracranial complications of acute bacterial endocarditis. *Surg Neurol Int*. 2018; 9: 107, doi: [10.4103/sni.sni_67_18](https://doi.org/10.4103/sni.sni_67_18), indexed in Pubmed: [29930873](https://pubmed.ncbi.nlm.nih.gov/29930873/).
 21. Tureen JH, Dworkin RJ, Kennedy SL, et al. Loss of cerebrovascular autoregulation in experimental meningitis in rabbits. *J Clin Invest*. 1990; 85(2): 577–581, doi: [10.1172/JCI114475](https://doi.org/10.1172/JCI114475), indexed in Pubmed: [2105342](https://pubmed.ncbi.nlm.nih.gov/2105342/).
 22. Schut ES, Brouwer MC, de Gans J, et al. Delayed cerebral thrombosis after initial good recovery from pneumococcal meningitis. *Neurology*. 2009; 73(23): 1988–1995, doi: [10.1212/WNL.0b013e3181c55d2e](https://doi.org/10.1212/WNL.0b013e3181c55d2e), indexed in Pubmed: [19890068](https://pubmed.ncbi.nlm.nih.gov/19890068/).
 23. Gallegos C, Tobolowsky F, Nigo M, et al. Delayed Cerebral Injury in Adults With Bacterial Meningitis: A Novel Complication of Adjunctive Steroids? *Crit Care Med*. 2018; 46(8): e811–e814, doi: [10.1097/CCM.0000000000003220](https://doi.org/10.1097/CCM.0000000000003220), indexed in Pubmed: [29746358](https://pubmed.ncbi.nlm.nih.gov/29746358/).
 24. Engelen-Lee JY, Brouwer MC, Aronica E, et al. Delayed cerebral thrombosis complicating pneumococcal meningitis: an autopsy study. *Ann Intensive Care*. 2018; 8(1): 20, doi: [10.1186/s13613-018-0368-8](https://doi.org/10.1186/s13613-018-0368-8), indexed in Pubmed: [29427117](https://pubmed.ncbi.nlm.nih.gov/29427117/).
 25. Klein M, Koedel U, Kastenbauer S, et al. Delayed cerebral thrombosis after initial good recovery from pneumococcal meningitis: past as prologue: delayed stroke as a parainfectious process of bacterial meningitis? *Neurology*. 2010; 75(2): 193; author reply 193–4, doi: [10.1212/WNL.0b013e3181e00e8e](https://doi.org/10.1212/WNL.0b013e3181e00e8e), indexed in Pubmed: [20625175](https://pubmed.ncbi.nlm.nih.gov/20625175/).
 26. Hoffman O, Weber RJ. Pathophysiology and treatment of bacterial meningitis. *Ther Adv Neurol Disord*. 2009; 2(6): 1–7, doi: [10.1177/1756285609337975](https://doi.org/10.1177/1756285609337975), indexed in Pubmed: [21180625](https://pubmed.ncbi.nlm.nih.gov/21180625/).
 27. Johanson CE, Stopa EG, McMillan PN. The blood-cerebrospinal fluid barrier: structure and functional significance. *Methods Mol Biol*. 2011; 686: 101–131, doi: [10.1007/978-1-60761-938-3_4](https://doi.org/10.1007/978-1-60761-938-3_4), indexed in Pubmed: [21082368](https://pubmed.ncbi.nlm.nih.gov/21082368/).
 28. Larterra J. Blood–Brain–Cerebrospinal Fluid Barriers. In: Siegel GJ, Bernard WA, Alberts RW, et al. ed. *Basic Neurochemistry*. Vol 6. Lippincott-Raven, Philadelphia 1999.
 29. Nau R, Eiffert H. Modulation of release of proinflammatory bacterial compounds by antibacterials: potential impact on course of inflammation and outcome in sepsis and meningitis. *Clin Microbiol Rev*. 2002; 15(1): 95–110, doi: [10.1128/cmr.15.1.95-110.2002](https://doi.org/10.1128/cmr.15.1.95-110.2002), indexed in Pubmed: [11781269](https://pubmed.ncbi.nlm.nih.gov/11781269/).
 30. Levi M, van der Poll T, Büller HR. Bidirectional relation between inflammation and coagulation. *Circulation*. 2004; 109(22): 2698–2704, doi: [10.1161/01.CIR.0000131660.51520.9A](https://doi.org/10.1161/01.CIR.0000131660.51520.9A), indexed in Pubmed: [15184294](https://pubmed.ncbi.nlm.nih.gov/15184294/).
 31. Rittirsch D, Flierl MA, Ward PA. Harmful molecular mechanisms in sepsis. *Nat Rev Immunol*. 2008; 8(10): 776–787, doi: [10.1038/nri2402](https://doi.org/10.1038/nri2402), indexed in Pubmed: [18802444](https://pubmed.ncbi.nlm.nih.gov/18802444/).
 32. Wall EC, Gordon SB, Hussain S, et al. Persistence of pneumolysin in the cerebrospinal fluid of patients with pneumococcal meningitis is associated with mortality. *Clin Infect Dis*. 2012; 54(5): 701–705, doi: [10.1093/cid/cir926](https://doi.org/10.1093/cid/cir926), indexed in Pubmed: [22238165](https://pubmed.ncbi.nlm.nih.gov/22238165/).
 33. Srinivasan L, Kilpatrick L, Shah SS, et al. Cerebrospinal fluid cytokines in the diagnosis of bacterial meningitis in infants. *Pediatr Res*. 2016; 80(4): 566–572, doi: [10.1038/pr.2016.117](https://doi.org/10.1038/pr.2016.117), indexed in Pubmed: [27486702](https://pubmed.ncbi.nlm.nih.gov/27486702/).
 34. Coutinho LG, Grandgirard D, Leib SL, et al. Cerebrospinal-fluid cytokine and chemokine profile in patients with pneumococcal and meningococcal meningitis. *BMC Infect Dis*. 2013; 13: 326, doi: [10.1186/1471-2334-13-326](https://doi.org/10.1186/1471-2334-13-326), indexed in Pubmed: [23865742](https://pubmed.ncbi.nlm.nih.gov/23865742/).
 35. Low PS, Lee BW, Yap HK, et al. Inflammatory response in bacterial meningitis: cytokine levels in the cerebrospinal fluid. *Ann Trop Paediatr*. 1995; 15(1): 55–59, indexed in Pubmed: [7598438](https://pubmed.ncbi.nlm.nih.gov/7598438/).
 36. Perdomo-Celis F, Torres MA, Ostos H, et al. Patterns of Local and Systemic Cytokines in Bacterial Meningitis and its Relation with Severity and Long-Term Sequelae. *Biomark Insights*. 2015; 10: 125–131, doi: [10.4137/BMI.S35005](https://doi.org/10.4137/BMI.S35005), indexed in Pubmed: [26715831](https://pubmed.ncbi.nlm.nih.gov/26715831/).
 37. Woehrl B, Brouwer MC, Murr C, et al. Complement component 5 contributes to poor disease outcome in humans and mice with pneumococcal meningitis. *J Clin Invest*. 2011; 121(10): 3943–3953, doi: [10.1172/JCI57522](https://doi.org/10.1172/JCI57522), indexed in Pubmed: [21926466](https://pubmed.ncbi.nlm.nih.gov/21926466/).
 38. de Gans J, van de Beek D. European Dexamethasone in Adulthood Bacterial Meningitis Study Investigators. Dexamethasone in adults with bacterial meningitis. *N Engl J Med*. 2002; 347(20): 1549–1556, doi: [10.1056/NEJMoa021334](https://doi.org/10.1056/NEJMoa021334), indexed in Pubmed: [12432041](https://pubmed.ncbi.nlm.nih.gov/12432041/).
 39. Korshin A, Køster-Rasmussen R, Meyer CN, et al. Danish Bacterial Meningitis Group. Adjunctive steroid treatment: local guidelines and patient outcome in adult bacterial meningitis. *Scand J Infect Dis*. 2007; 39(11-12): 963–968, doi: [10.1080/00365540701449393](https://doi.org/10.1080/00365540701449393), indexed in Pubmed: [17852945](https://pubmed.ncbi.nlm.nih.gov/17852945/).
 40. van de Beek D, Farrar JJ, de Gans J, et al. Adjunctive dexamethasone in bacterial meningitis: a meta-analysis of individual patient data. *Lancet Neurol*. 2010; 9(3): 254–263, doi: [10.1016/S1474-4422\(10\)70023-5](https://doi.org/10.1016/S1474-4422(10)70023-5), indexed in Pubmed: [20138011](https://pubmed.ncbi.nlm.nih.gov/20138011/).
 41. Zwijnenburg PJG, van der Poll T, Florquin S, et al. C1 inhibitor treatment improves host defense in pneumococcal meningitis in rats and mice. *J Infect Dis*. 2007; 196(1): 115–123, doi: [10.1086/518609](https://doi.org/10.1086/518609), indexed in Pubmed: [17538891](https://pubmed.ncbi.nlm.nih.gov/17538891/).
 42. Hoffmann O, Priller J, Prozorovski T, et al. TRAIL limits excessive host immune responses in bacterial meningitis. *J Clin Invest*. 2007;

- 117(7): 2004–2013, doi: [10.1172/JCI30356](https://doi.org/10.1172/JCI30356), indexed in Pubmed: [17571163](https://pubmed.ncbi.nlm.nih.gov/17571163/).
43. Grandgirard D, Schürch C, Cottagnoud P, et al. Prevention of brain injury by the nonbacteriolytic antibiotic daptomycin in experimental pneumococcal meningitis. *Antimicrob Agents Chemother.* 2007; 51(6): 2173–2178, doi: [10.1128/AAC.01014-06](https://doi.org/10.1128/AAC.01014-06), indexed in Pubmed: [17371820](https://pubmed.ncbi.nlm.nih.gov/17371820/).
44. Jun JS, Lee ST, Kim R, et al. Tocilizumab treatment for new onset refractory status epilepticus. *Ann Neurol.* 2018; 84(6): 940–945, doi: [10.1002/ana.25374](https://doi.org/10.1002/ana.25374), indexed in Pubmed: [30408233](https://pubmed.ncbi.nlm.nih.gov/30408233/).
45. Brouwer M, Read R, Beek Dv. Host genetics and outcome in meningococcal disease: a systematic review and meta-analysis. *The Lancet Infectious Diseases.* 2010; 10(4): 262–274, doi: [10.1016/s1473-3099\(10\)70045-1](https://doi.org/10.1016/s1473-3099(10)70045-1).