



Metastatic choriocarcinoma of the testis mimicking ocular melanoma

Arch Oncol 2008;17(3-4):88. Vanja Karadinović, Duško Kozić, Jelena Ostojić

UDC: 617.7-006:616-006.8:616.683-006
DOI: 10.2298/A000904088K

Key words: Choriocarcinoma, Non-gestational; Testicular Neoplasms; Eye Neoplasms; Melanoma

Oncology Institute of Vojvodina,
Sremska Kamenica, Serbia

Correspondence to:
Duško Kozić, Oncology Institute
of Vojvodina, Institutski put 4,
21204 Sremska Kamenica, Serbia

Received: 12.08.2009
Provisionally accepted: 17.08.2009
Accepted: 21.08.2009

© 2009, Oncology Institute of
Vojvodina, Sremska Kamenica

MR examination revealed the presence of metastatic lesion in the right occipital lobe (Figure 1A) in a 23-year-old man with headaches, severe visual problems and right exophthalmus, associated with soft tissue choroidal mass of the right eyeball (Figure 1A and 1B) and T1W hyperintensity within the corpus vitreum, compatible with hemorrhage due to retinal ablatia (Figure 1B). Melanomas are the most frequent malignant ocular neoplasms. Melanoma, renal carcinoma, thyroid carcinoma, and choriocarcinoma are however the most frequent hemorrhagic metastases within the brain parenchyma (1). Histologic evaluation revealed metastatic choriocarcinoma. Primary neoplasm of the testis was confirmed after additional examinations.

Conflict of interest

We declare no conflicts of interest.

REFERENCE

- 1 Takahashi M, Takekawa SD, Suzuki K, Fukaya T, Ushioda T, et al. Hemorrhagic brain metastases. Analysis of computed tomography, predisposing factors and prognosis. *Nippon Igaku Hoshasen Gakkai Zasshi*. 1986;46(3):458-68.

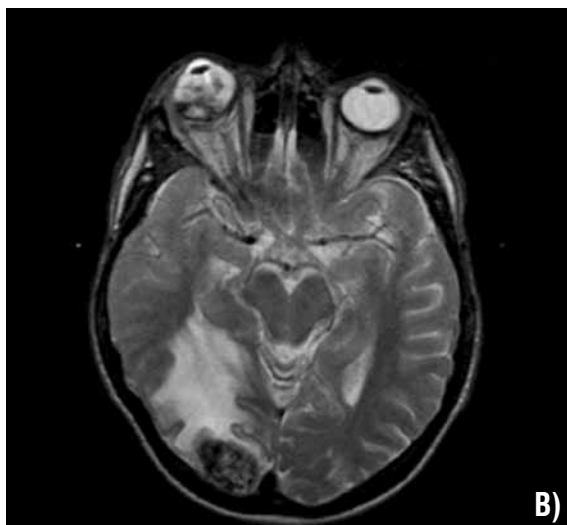
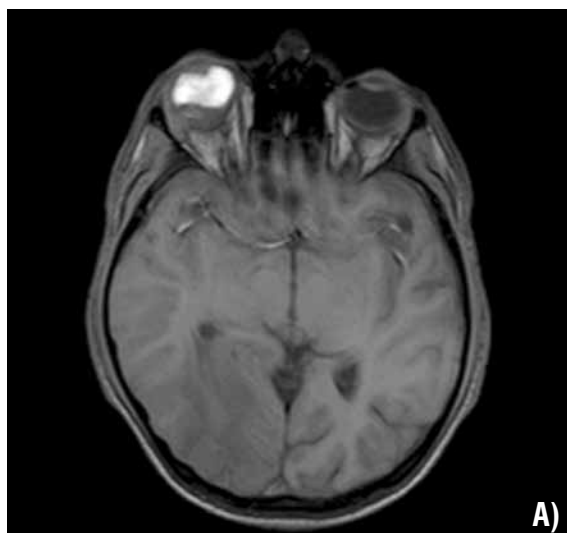

Figure 1. A) T2W sequence showing exophthalmus of the right eyeball associated with choroidal mass and right occipital metastatic focus with surrounding edema; B) T1W sequence showing corpus vitreum hemorrhage of the right eyeball.