

## SUPRACONDYLAR FRACTURE OF THE HUMERUS IN CHILDREN

*Nikola Bojović, Zoran Marjanović, Dragoljub Živanović, Nina Đorđević, Miroslav Stojanović, Goran Janković and Nikola Vacić*

Humeral supracondylar fractures are the second most common fractures seen in children and young teenagers (16.6%). They represent 60-70% of all the elbow fractures. The maximum incidence is found between the fifth and seventh year of age, slightly more often in boys and on non-dominant hand.

We performed a retrospective study in our clinic which included 105 patients admitted to our facility during the period from January, 2008 to April, 2012. The included patients had humeral supracondylar fracture either type 2 or type 3 (Gartland classification). At the moment of admission the median age was 7.26 years. All the patients were treated during the first 12 hours, with no more than two attempts of closed reposition. Sixteen patients with type 2 fracture were treated by analgosedation, closed reduction followed by cast immobilization. All other patients were treated after induction of general anesthesia. Sixteen patients were treated by percutaneous fixation of the fragments after closed reduction and 73 were treated with open reduction and pinning with different number and positions of „K“ wires.

None of the patients had deep tissue infection; four patients had pin site infection. Three patients had cubitus varus deformity, two patients had elbow contracture, five patients had temporary limitation in extension, and one patient had iatrogenic lesion of the ulnar nerve. This makes 14.2% complication rate in our series. All the fractures healed in the expected period (3–4 weeks). Bauman's angle, carrying angle and functional factor were measured postoperatively.

Closed reposition with pinning, using radiographic control, for the dislocated supracondylar humeral fractures is the safest, as well as the least time consuming and cost-effective method. We also suggest treating these fractures within 12 hours and conversion of closed into open reposition in case of lacking crepitations (possibility of interposition of soft tissues between fragments). *Acta Medica Medianae 2012;51(3):5-12.*

**Key words:** supracondylar fracture, elbow, reposition, fixation

Clinic of Pediatric Surgery and Orthopedics, Clinical Center Niš,  
Niš, Serbia

Contact: Nikola Bojović  
Clinic of Pediatric Surgery and Orthopedics, Clinical Center Niš  
Bul. Zorana Đinđića 48, 18000 Niš, Serbia  
E-mail: niboj@sbb.rs

belong to the flexion type occurring with direct trauma to the elbow (7).

### Introduction

Humeral supracondylar fractures (Figure 1) are the second most common fractures seen in children and young teenagers (16.6%) (1). They account for 60-70% of all the elbow fractures (2, 3). The maximum incidence is found between the fifth and seventh year, slightly more often in boys and on non-dominant hand (4,5). In 2-5% of cases, an associated fracture on the same side occurs - radial, ulnar or both (6).

By evaluating 4.520 cases of supracondylar fractures of humerus found in 31 series in the literature, Wilkins established the classification regarding the mechanism of trauma and displacement course: 90-98% of all fractures belong to the so-called extension type occurring by falling on the extended arm, and less than 5%

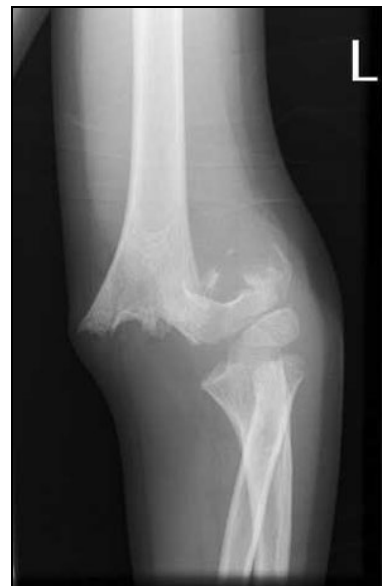

Figure 1. Supracondylar fracture of humerus

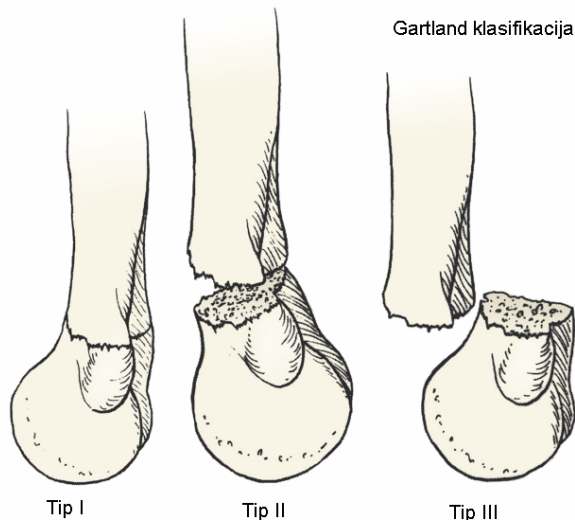


Figure 2. Gartland classification

Gartland established the classification based on the level of dislocation of fragments (Figure 2): type 1 – undislocated fragments, type 2 – dislocated fragments, but with preserved integrity of posterior cortex, and type 3 – complete dislocation without any contact between fragments (the classification determines the surgical approach) (8). The modified Gartland classification is frequently used, consisting of one more type – type 4 – complete dislocation of multidirectional fragments (Leitch et al.) (9).

The goal of the treatment of humeral supracondylar fractures in children still remains a great challenge for the pediatric orthopedic surgeons. A possible association between neurovascular trauma and non-negligible percentage of residual functional deformities categorizes these types of fractures as one of the most difficult entities found in pediatric bone trauma (10,11). Possible modalities for treating these kinds of fractures are: skeletal traction, closed reposition followed by cast immobilization, percutaneous pinning following open/closed reposition, and open reposition followed by inner fixation (12-15).

The treatment of Gartland type 3 fractures has different approaches, but all type 3 fractures have uniform complications including neurovascular injury, cubitus varus, Volkmann's ischemic contracture and contracture of the elbow (16).

Supracondylar fracture of the humerus (if it is not an open fracture, and if it does not jeopardize the neurovascular structures) should be treated during the same day, with the team of trained surgeons using radioscopic imaging. In some cases, during the night, the fracture cannot be treated in the aforesaid manner; therefore, it is wiser to wait for the next day, since postponing the operation for the next 12 hours does not affect the final result (17,18).

## Aim

The aim of this study was to emphasize the importance of treating supracondylar humeral fractures in children at the optimum time, in the right place, under the right conditions (e.g. equipment: a mobile C-shaped X-ray image Intensifier and TV chain) and by specialized team, thus preventing and minimizing possible complications that could lead to permanent functional and cosmetic deficits.

## Materials and methods

We performed a retrospective study in the Clinic for Pediatric Surgery in Niš, Serbia. The study included 105 patients admitted to our facility during the period from January, 2008 to April, 2012. The included patients had humeral supracondylar fracture either type 2 or type 3 (Gartland classification). The most common causes of injury include a simple fall, fall from a bicycle, injury during sports activities, and fall from a height. At the time of admission, the median age of patients was 7.26 years (2 to 14-year-old children) and 67.6% of the patients were boys. All the fractures were closed and belonged to the extension type (98%); only one patient had flexion type fracture. Forty three patients (41%) had injury occurring on their left elbow, and 62 patients (59%) had the right elbow injury. The aforesaid ratio (41:59) is also seen in type 2 and type 3 fractures, respectively. Only two patients presented with an associated injury of the same arm; one of them had radial and ulnar fractures, and the other one had distal ulnar fracture. Five patients (4.7%) were presented with neurological deficits on the admission; three patients had median nerve injury, and two patients had radial nerve injury. There were no patients with any vascular injury. All the patients were treated during the first 12 hours, with no more than two attempts of closed reposition.

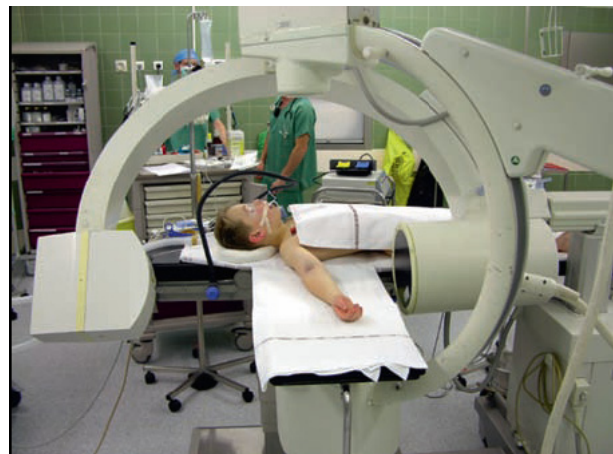

Figure 3. Mobile C-shaped X-ray used in the operating room

Sixteen patients (15.2%) with type 2 fracture received sedatives (Amp. Flormidal® - midazolam) enhanced with analgesic (metamizol); these patients were treated only by closed reposition followed by cast immobilization. All the other patients were treated after induction of general anesthesia. In 30 patients (28.8%), we tried to perform a closed reposition initially. This involved hand traction with elbow in extension, followed by fracture correction in the frontal and sagittal areas. Afterwards, we placed the elbow in flexion to keep the corrected position in order to perform the radiographic verification of the fracture site. Adequate position of the fragments was achieved in 16 cases (15%), allowing us to perform percutaneous fixation of the fragments - 7 patients (6.6%) had two parallel "K" wires placed laterally, 5 patients (4.7%) had two crossed „K" wires, and 4 patients (3.8%) had three wires (two placed laterally and one medially). The other 14 cases were treated with open reposition after two attempts of closed reposition. Fifty-nine patients (56%) were initially treated with open reposition followed by pinning with two, three or four „K" wires. In 50%, we used the posterior approach, and in 20% the lateral approach.

Table 1. Demographic data

Variables	n=105 (%)
Age	7.26 ± 3.1
Sex	
Female	34(32.3)
Male	71(67.6)
Side	
Right	43 (40.9)
Left	62 (59.1)
Dominant arm	39 (37.9)
Non-dominant arm	66( 62.8)
Technique	
Closed	16(15.2)
Closed + pinning	16(15.2)
Open	73 (70)
Posterior approach	52(50)
Lateral approach	21 (19)

The average postoperative follow-up was 6.2 months. The follow-up included the first, second, third and sixth postoperative week control examination, and at months 3, 6 and 12 post-operatively. The "K" wires were extracted 3-4 weeks after surgery, and in most cases the upper arm plaster splint was worn for 3-6 weeks post-operatively. After removing the plaster immobilization the patients were recommended active physical therapy. During postoperative follow-up, all the patient's results of treatment were estimated according to Flynn criteria (19), which is a proved clinical criterion for follow-up of the patients with supracondylar humeral fractures.

Besides the clinical grading, we also evaluated the carrying angle (20) and functional factor, as well as Bauman's angle on post-operative radiographs and radiographs made during the last clinical examination.

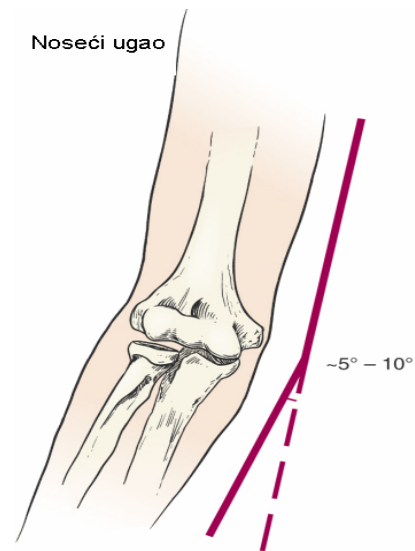


Figure 4. Carryng angle

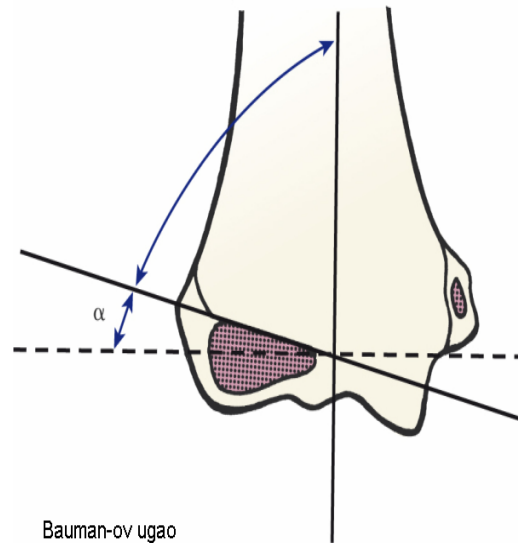


Figure 5. Bauman's angle

According to the Flynn criteria, based on measuring both factors (carrying angle and functional factor) in the same patient, the worse result was considered as the relevant one.

The limiting factor in our study was the inability to follow patients for a longer period of time, because some studies mention the possibility of cubitus varus development up to one year after the fracture. Yet, most studies included a follow-up period of six months.

Table 2. "Flynn criteria"

Results	Cosmetic factor - loss of carrying angle (grades)	Functional factor - loss of flexion / extension (grades)
Excellent	0 - 5	0 - 5
Good	6 - 10	6 - 10
Fair	11 - 15	11 - 15
Poor	> 15	> 15

## Results

None of the patients had a deep tissue infection. Four patients (3 open and 1 closed reposition) had a superficial infection around the "K" wires, which was resolved by prescribing the oral antibiotics. Three patients (open reposition) had cubitus varus deformity, 2 patients (open reposition) had elbow contracture, 5 patients (4 open and 1 closed reposition) had temporary limitation in extension, and 1 patient (open reposition of a comminutive fracture) had iatrogenic lesion of the ulnar nerve; this makes 14.2% complication rate in our series. All the fractures healed in the expected period (3–4 weeks). There were no residual vascular deficits. Primarily presented neurological deficit was seen in 5 patients; all the symptoms disappeared during the follow-up period (average: 4.5 months). There were no requests for scar excision.

Postoperative average of Bauman's angle was  $77.2^{\circ} \pm 1.1^{\circ}$  and  $74.5^{\circ} \pm 0.7^{\circ}$  for the injured and healthy elbow, respectively. There was no statistically significant difference in comparing Bauman's angle after the intervention and on the last control examination ( $p > 0.05$ ).

We also measured the carrying angle of both elbows (the injured and the healthy one) on the last clinical examination. Seventy-five patients (71.4%) had reduction between  $0^{\circ}$  and  $5^{\circ}$ , 18 patients (17.1%) had reduction between  $6^{\circ}$  and  $10^{\circ}$ , 7 patients (6.6%) had reduction between  $11^{\circ}$  and  $15^{\circ}$ , and 5 patients (4.7%) had reduction of carrying angle above  $15^{\circ}$ .

We also measured the functional factor (flexion and extension in the elbow); 65 patients (62%) had less than  $5^{\circ}$  loss, 27 patients (25.75%) had loss between  $6^{\circ}$  and  $10^{\circ}$ , 10 patients (9.5%) had loss between  $11^{\circ}$  and  $15^{\circ}$ , and 3 patients (2.85%) had loss of flexion/extension above  $16^{\circ}$  (Table 3).

Table 3. Results of reduction of fracture based on Flynn criteria

Results	Rating	Number of patients	Percentage
Satisfactory	Excellent	65	62%
	Good	25	23,8 %
	Fair	10	9,5 %
Unsatisfactory	Poor	5	4,7 %

The final results obtained by evaluation of Flynn criteria showed satisfactory results in 97% of all the patients (100 patients), and in only five cases (4.7%), the outcome was unsatisfactory. Among treated patients with closed reduction and pinning and treated with open reduction, regardless of the method of approach and the number of wires used to stabilize the fracture, there was no significant statistical difference ( $p > 0.05$ ).

Table 4. Comparison of injured and uninjured elbow on the last clinical examination (Student t-test)

n = 105	Injured side ( $^{\circ}$ )	Uninjured side ( $^{\circ}$ )	p-value *
Carrying angle	$7.3 \pm 1.6$	$7.1 \pm 1.9$	0.718
Total angle of movement	$129 \pm 3.2$	$130 \pm 2.1$	0.320

Table 5. Our specimen in treating supracondylar humeral fractures

Treatment modality	n=105	%
Closed reposition, cast immobilization	16	15%
Closed reposition, pinning	16	15%
Open reposition, posterior approach	52	50%
Open reposition, lateral approach	21	20%




Figure 6. Control recording of the fixed fracture, with two "K" wires on the TV chain in the operating room

## Discussion

The aim of the treatment of dislocated supracondylar humeral fractures is to achieve satisfactory functional and cosmetic results and avoid complications (decreasing complication rate). Lately, many people arouse the issue of the cost-benefit effect of the treatment (method of treatment and days of the in-patient care).

Traction is still one of the electoral methods for the treatment, but the length of treatment and high incidence of cubitus varus are certainly pushing this method in the background (22).

Closed reposition followed by percutaneous pinning is considered to be the golden standard for the type 2 and 3 fractures (Gartland classification) (23). There is a smaller probability for compartment syndrome development and the risk for secondary fragment dislocation is also lower compared to closed reposition followed only by cast immobilization (24).

Compared to open surgery, it reduces the chances of elbow contracture, infection, myositis ossificans costs decrease (no suture materials, no

prolonged antibiotic prophylaxis and prolonged hospitalization).

Several questions still remain unanswered, even though many authors tried to give the proper guidelines. Is it safe to place the "K" wire medially (25)? Some have proven the injury rate of the ulnar nerve 4-15%, and the rate goes even higher if the surgeon tries to place the pin when elbow maximally flexed (26,27). Therefore, Khurram B et al. suggest obligatory incision above the medial epicondyle and visualizing the ulnar nerve with possible placing the elbow in extension before placing the "K" wire (28), while others believe that all this can be avoided by parallel positioning of the "K" wire, only from the lateral side.

Lateral pinning has many followers (29, 30); there are many articles concerning very good results if one applies this manner of pinning. However, biomechanical studies have shown a better elbow stability if "K" wires are placed in a crossed manner, compared to parallel placing of the "K" wires (31). There is a greater re-dislocation rate and inability to measure full extension of the injured elbow during the operation; therefore, one cannot measure the carrying angle.

The open method of treatment (32) regardless of the approach (which is left to their interests and experience of the surgeon) in the literature is primarily reserved for multidirectional fractures (Type IV by Leitch-in - modified Gartland classification), fractures with neurovascular injury, open fractures, fractures with signs of Volkmann's ischemia, fractures with a huge edema with no modality for closed reduction, and after unsuccessful attempts of closed reposition.

A number of authors report a lack of mobile C-shaped X-ray image Intensifier as an important detail in an attempt to solve this fracture by closed method.

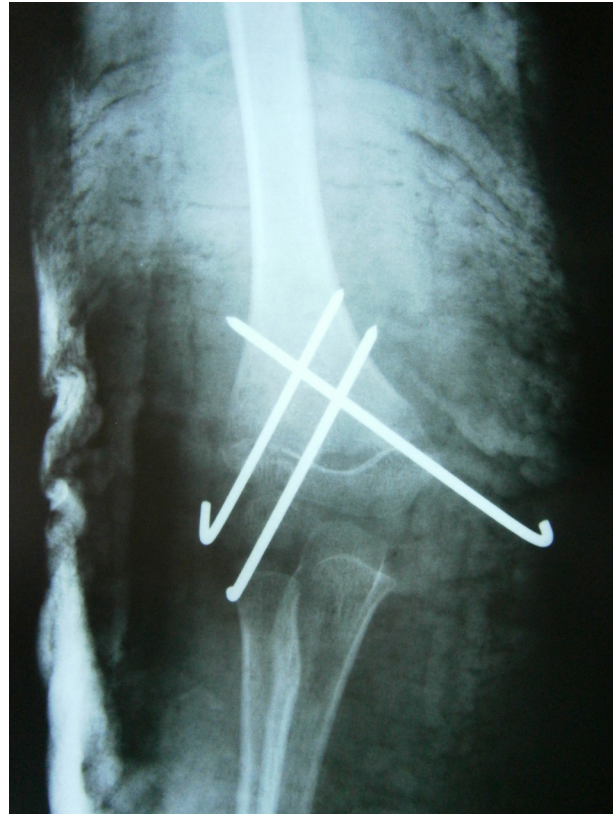

Figure 7. Open reduced and fixed fracture with two laterally and one medially placed "K" wires

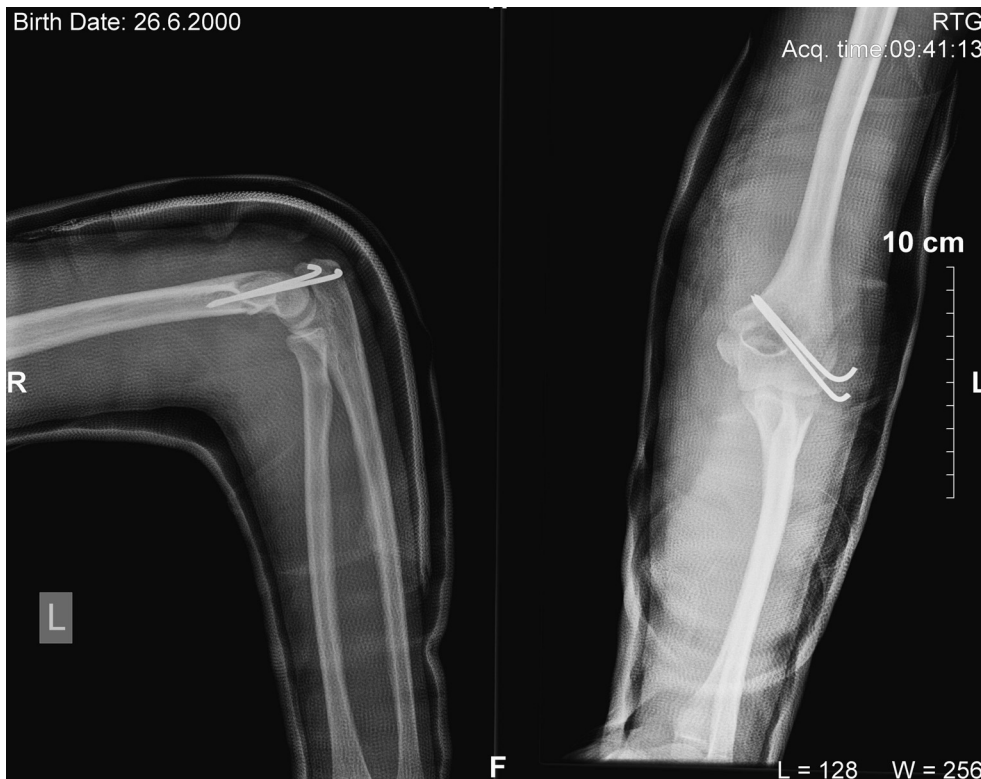

Figure 8. Closed reduced and percutaneously fixed fracture laterally by two placed "K" wires

Our specimen included all the treating modalities, except for traction. Apart from five unsatisfactory results, all the other results were satisfactory judging by the world-wide accepted standards.

Equally good results were achieved by treating patients both with open and closed reposition, both of which were followed by pinning, which correlates to accepted standards. The decision of positioning pins in a crossed way or parallel placement of them depends only on the decision of a surgeon and his/her affinity. Besides one case of comminutive fracture, we had no cases of ulnar nerve injury, even in cases with very swollen elbow, with having subsequent difficulties to identify the medial epicondyle. Percentage of related complications (14.2%) completely corresponds to the percentage in the literature, up to 16% (33, 34). The complications are classified as a local pin site infection, ulnar nerve injury, temporary elbow contracture, non-union, and permanent functional disorders. It is also of great importance that there are no significant changes between injured and healthy side at the end of the follow-up.

Unfortunately, for the inability to use C-shaped X-ray image intensifier in the operation room all the time (period: 2008-2010), one group of fractures that could have been successfully treated by closed reposition was treated by the

open one. Almost all the closed fractures in these situations were accessed by posterior approach, with no postoperative complications.

### Conclusion

Closed reposition with pinning, under radiographic control, for dislocated supracondylar fractures of the elbow is the safest, as well as the least time consuming and cost-effective method, that provides stable fixation and excellent results. The alternative manner is small incision above the medial epicondyle and identification of the ulnar nerve. Trying to avoid damage of the zone of growth, further comminution and elbow contracture, we recommend maximum two attempts of closed reduction. We also suggest treating these fractures within twelve hours and conversion of closed into open reposition in case of lacking crepitations (possibility of interposition of soft tissues between fragments).

Open reposition should be reserved for complicated cases, and cases where more than 12 hours after sustaining the injury have elapsed.

Length of exposure to ionizing radiation, the patient and the whole operating staff, the definitive effect of the chosen operative treatment directly depends on the surgeon's experience and knowledge (35,36).

### References

1. Kazimoglu C, Cetin M, Sener M, Agus H, Kalanderer O. Operative management of type III extension supracondylar fractures in children. *Int Orthop*. 2009; 33(4): 1089-94. [[CrossRef](#)] [[PubMed](#)]
2. Bachman D, Santora S. Orthopedic trauma. In: Fleisher GR, Ludwig S et al, editors. *Textbook of Pediatric Emergency Medicine*. Philadelphia: Lippincott Williams and Wilkins; 2006. 1538 p.
3. Omid R, Choi PD, Skaggs DL. Supracondylar humeral fractures in children. *J Bone Joint Surg Am*. 2008 May; 90(5):1121-32. [[CrossRef](#)] [[PubMed](#)]
4. Carson S, Woolridge DP, Colletti J, Kilgore K. Pediatric upper extremity injuries. *Pediatr Clin North Am*. 2006 Feb; 53(1): 41-67, v. [[CrossRef](#)] [[PubMed](#)]
5. Houshian S, Mehdi B, Larsen MS. The epidemiology of elbow fracture in children: analysis of 355 fractures, with special reference to supracondylar humerus fractures. *J Orthop Sci*. 2001; 6(4): 312-5. [[CrossRef](#)] [[PubMed](#)]
6. Roposch A, Reis M, Molina M, et al. Supracondylar fractures of the humerus associated with ipsilateral forearm fractures in children: a report of forty-seven cases. *J Pediatr Orthop*. 2001 May-Jun; 21(3): 307-12. [[CrossRef](#)] [[PubMed](#)]
7. Wilkins KE. Fractures and dislocations of the elbow region. *Fractures in children*, 3rd ed. Vol.3. Philadelphia: JB Lippincot; 1991. 509-828p.
8. Gartland JJ. Management of supracondylar humerus fractures of the humerus in children. *Surg Gynecol Obstet*. 1959; 109: 145-54. [[PubMed](#)]
9. Leitch KK, Kay RM, Femino JD, Tolo VT, Storer SK, Skaggs DL. Treatment of multidirectionally unstable supracondylar humeral fractures in children. A modified Gartland type-IV fracture. *J Bone Joint Surg Am*. 2006 May; 88(5): 980-5. [[CrossRef](#)] [[PubMed](#)]
10. Mangat KS, Martin AG, Bache CE. The 'pulseless pink' hand after supracondylar fracture of the humerus in children: the predictive value of nerve palsy. *J Bone Joint Surg Br*. 2009 Nov; 91(11): 1521-5. [[CrossRef](#)] [[PubMed](#)]
11. Blakey CM, Biant LC, Birch R. Ischaemia and the pink, pulseless hand complicating supracondylar fractures of the humerus in childhood: long-term follow-up. *J Bone Joint Surg Br*. 2009 Nov; 91(11): 1487-92. [[CrossRef](#)] [[PubMed](#)]
12. Oakley E, Barnett P, Babl FE. Backslab versus nonbackslab for immobilization of undisplaced supracondylar fractures: a randomized trial. *Pediatr Emerg Care*. 2009 Jul; 25(7): 452-6. [[CrossRef](#)] [[PubMed](#)]
13. Kaiser MM, Kamphaus A, Massalme E, Wessel LM. [Percutaneous closed pin fixation of supracondylar fractures of the distal humerus in children]. *Oper*

- Orthop Traumatol. 2008 Oct-Nov;20(4-5):297-309. In German [[CrossRef](#)] [[PubMed](#)]
14. Aktekin CN, Toprak A, Ozturk AM, Altay M, Ozkurt B, Tabak AY. Open reduction via posterior triceps sparing approach in comparison with closed treatment of posteromedial displaced Gartland type III supracondylar humerus fractures. J Pediatr Orthop B. 2008 Jul; 17(4): 171-8. [[CrossRef](#)] [[PubMed](#)]
  15. Fu D, Xiao B, Yang S, Li J. Open reduction and bioabsorbable pin fixation for late presenting irreducible supracondylar humeral fracture in children. Int Orthop. 2011 May; 35(5): 725-30. [[PubMed](#)]
  16. Eren A, Güven M, Erol B, Akman B, Ozkan K. Correlation between posteromedial or posterolateral displacement and cubitus varus deformity in supra condylar humerus fractures in children. J Child Orthop. 2008 Mar; 2(2): 85-9. [[CrossRef](#)] [[PubMed](#)]
  17. Yildirim AO, Unal VS, Oken OF, Gulcek M, Ozsular M, Ucaner A. Timing of surgical treatment for type III supracondylar humerus fractures in pediatric patients. J Child Orthop. 2009 Aug; 3(4): 265-9. [[CrossRef](#)] [[PubMed](#)]
  18. Cashman JP, Guerin SM, Hemsing M, McCormack D. Effect of deferred treatment of supracondylar humeral fractures. Surgeon. 2010 Apr; 8(2): 71-3. [[CrossRef](#)] [[PubMed](#)]
  19. Flynn JC, Matthews JG, Benoit RL. Blind pinning of displaced supracondylar fractures of the humerus in children. Sixteen years' experience with long-term follow-up. J Bone Joint Surg Am. 1974 Mar; 56(2): 263-72. [[PubMed](#)]
  20. Zampagni ML, Casino D, Martelli S, Visani A, Marcacci M. A protocol for clinical evaluation of the carrying angle of the elbow by anatomic landmarks. J Shoulder Elbow Surg. 2008 Jan-Feb; 17(1): 106-12. [[CrossRef](#)] [[PubMed](#)]
  21. Wind WM, Schwend RM, Armstrong DG. Predicting ulnar nerve location in pinning of supracondylar humerus fractures. J Pediatr Orthop. 2002 Jul-Aug; 22(4):444-7. [[CrossRef](#)] [[PubMed](#)]
  22. Ağuş H, Kalenderer O, Kayalı C, Eryanılmaz G. Skeletal traction and delayed percutaneous fixation of complicated supracondylar humerus fractures due to delayed or unsuccessful reductions and extensive swelling in children. J Pediatr Orthop B. 2002 Apr; 11(2): 150-4. [[CrossRef](#)] [[PubMed](#)]
  23. Jiang X, Tang X, Wang D, Peng M, Cheng X, Liu L. [Operative treatment of Gartland type III humeral supracondylar fractures in children with minimally invasive incision and percutaneous pinning]. Zhongguo Xiu Fu Chong Jian Wai Ke Za Zhi. 2010 Jun; 24(6): 677-9. In Chinese [[PubMed](#)]
  24. de Gheldere A, Bellan D. Outcome of Gartland type II and type III supracondylar fractures treated by Blount's technique. Indian J Orthop. 2010 Jan; 44(1): 89-94. [[CrossRef](#)] [[PubMed](#)]
  25. Eidelman M, Hos N, Katzman A, Bialik V. Prevention of ulnar nerve injury during fixation of supracondylar fractures in children by 'flexion-extension cross-pinning' technique. J Pediatr Orthop B. 2007 May; 16(3): 221-4. [[CrossRef](#)] [[PubMed](#)]
  26. Slobogean BL, Jackman H, Tennant S, Slobogean GP, Mulpuri K. Iatrogenic ulnar nerve injury after the surgical treatment of displaced supracondylar fractures of the humerus: number needed to harm, a systematic review. J Pediatr Orthop. 2010 Jul-Aug; 30(5): 430-6. [[CrossRef](#)] [[PubMed](#)]
  27. Brauer CA, Lee BM, Bae DS, Waters PM, Kocher MS. A systematic review of medial and lateral entry pinning versus lateral entry pinning for supra condylar fractures of the humerus. J Pediatr Orthop. 2007 Mar; 27(2): 181-6. [[CrossRef](#)] [[PubMed](#)]
  28. Barlas K, Baga T. Medial approach for fixation of displaced supracondylar fractures of the humerus in children. Acta Orthop Belg. 2005 Apr; 71(2): 149-53. [[PubMed](#)]
  29. Skaggs DL, Cluck MW, Mostofi A, Flynn JM, Kay RM. Lateral-entry pin fixation in the management of supracondylar fractures in children. J Bone Joint Surg Am. 2004 Apr; 86-A(4): 702-7. [[PubMed](#)]
  30. El-Adl WA, El-Said MA, Boghdady GW, Ali AS. Results of treatment of displaced supracondylar humeral fractures in children by percutaneous lateral cross-wiring technique. Strategies Trauma Limb Reconstr. 2008 Apr; 3(1): 1-7. [[CrossRef](#)] [[PubMed](#)]
  31. Larson L, Firoozbakhsh K, Passarelli R, Bosch P. Biomechanical analysis of pinning techniques for pediatric supracondylar humerus fractures. J Pediatr Orthop. 2006 Sep-Oct; 26(5): 573-8. [[CrossRef](#)] [[PubMed](#)]
  32. Pretell-Mazzini J, Rodriguez-Martin J, Andres-Esteban EM. Does open reduction and pinning affect outcome in severely displaced supracondylar humeral fractures in children? A systematic review. Strategies Trauma Limb Reconstr. 2010 Aug; 5(2): 57-64. [[CrossRef](#)] [[PubMed](#)]
  33. Bashyal RK, Chu JY, Schoenecker PL, Dobbs MB, Luhmann SJ, Gordon JE. Complications after pinning of supracondylar distal humerus fractures. J Pediatr Orthop. 2009 Oct-Nov; 29(7): 704-8. [[CrossRef](#)] [[PubMed](#)]
  34. Babal JC, Mehlman CT, Klein G. Nerve injuries associated with pediatric supracondylar humeral fractures: a meta-analysis. J Pediatr Orthop. 2010 Apr-May; 30(3): 253-63. [[CrossRef](#)] [[PubMed](#)]
  35. Bar-On E, Weigl DM, Becker T, Katz K, Konen O. Intraoperative C-arm radiation affecting factors and reduction by an intervention program. J Pediatr Orthop. 2010 Jun; 30(4): 320-3. [[CrossRef](#)] [[PubMed](#)]
  36. Padman M, Warwick AM, Fernandes JA, Flowers MJ, Davies AG, Bell MJ. Closed reduction and stabilization of supracondylar fractures of the humerus in children: the crucial factor of surgical experience. J Pediatr Orthop B. 2010 Jul; 19(4): 298-303. [[CrossRef](#)] [[PubMed](#)]

## SUPRAKONDILARNI PRELOM HUMERUSA KOD DECE

*Nikola Bojović, Zoran Marjanović, Dragoljub Živanović, Nina Đorđević, Miroslav Stojanović, Goran Janković i Nikola Vacić*

Suprakondilarni prelom humerusa je drugi najčešći prelom kostiju kod dece i mlađih tinejdžera (16.6%). Čini između 60 i 70% svih preloma lakta. Njegov pik je između pete i sedme godine života, nešto češće na nedominantnoj ruci i kod dečaka.

Retrospektivna studija je sprovedena u Klinici za dečju hirurgiju i ortopediju u Nišu. Obuhvaćeni su povređeni, njih 105, koji su primljeni u Kliniku u periodu januar 2008-april 2012. godine zbog suprakondilarnog preloma humerusa, drugog i trećeg tipa po Gartland-u. U momentu preloma, prosečna starost povređenih bila je 7.26 godina. Svi prelomi bili su rešavani u okviru 12h od prijema, pri čemu nije bilo više od dva pokušaja zatvorene repozicije. U analgo-sedaciji je zbrinuto 16 preloma (15.2%), svi Tip II, što je podrazumevalo zatvorenu (ortopedsku) repoziciju i nadlaktanu gipsanu imobilizaciju. Hirurški su zbrinuti u opštoj anesteziji svi ostali prelomi. U 16 slučajeva smo perkutano fiksirali prelom posle zatvorene repozicije a u 73 slučaja smo imali otvorenu repoziciju i pinovanje različitim brojem i položajem „K“ igala.

Nijedan od povređenih nije imao infekciju dubokih tkiva, ali je njih četvoro imalo superficijalnu infekciju oko "K" igala. Cubitus varus deformitet imala su tri povređena, dva kontrakturu u laktu, pet privremenu limitiranost ekstenzije i jedan jatrogenu povredu n. ulnaris-a. Ukupno komplikacija bilo je kod 14.2%. Sve frakture su zarasle u očekivanom periodu (3-4 nedelje). Baumanov ugao, noseći ugao i funkcionalni faktor mereni su postoperativno.

Zatvorena repozicija i perkutano pinovanje "K" iglama, uz Rtg kontrolu, za dislocirane suprakondilarne frakture lakta predstavlja najbezbedniju i vremenski i ekonomski najefektivniju metodu, koja daje stabilnu fiksaciju i odlične rezultate. Preporučujemo rešavanje frakture u okviru 12 časova od prijema i konverziju u otvorenu repoziciju ukoliko ne dođe do senzacije krepitacija u toku zatvorene repozicije, jer se onda najčešće radi o umetanju mekih tkiva između fragmenata. *Acta Medica Medianae 2012;51(3):5-12.*

**Ključne reči:** *suprakondilarni prelom, lakat, repozicija, fiksacija*