

# Development of a safe and quick method for removal of intermaxillary fixation with superelastic Ni-Ti wire

著者名(英)	Masaru KUDO, Takuro KAWAI, Atsue YAMAZAKI, Shigeru UGA, Hanako OHKE, Masahiro KOKUBU, Itaru MIZOGUCHI, Noboru SHINYA
journal or publication title	東日本歯学雑誌
volume	23
number	2
page range	175-181
year	2004-12-31
URL	<a href="http://id.nii.ac.jp/1145/00008894/">http://id.nii.ac.jp/1145/00008894/</a>

[ORIGINAL]

## Development of a safe and quick method for removal of intermaxillary fixation with superelastic Ni–Ti wire

Masaru KUDO, Takuro KAWAI, Atsue YAMAZAKI<sup>1)</sup>, Shigeru UGA<sup>1)</sup>, Hanako OHKE,  
Masahiro KOKUBU, Itaru MIZOGUCHI<sup>1)</sup>, Noboru SHINYA

Department of Dental Anesthesiology,  
School of Dentistry, Health Sciences University of Hokkaido  
<sup>1)</sup>Department of Orthodontics,  
School of Dentistry, Health Sciences University of Hokkaido

### Abstract

To improve emergency intermaxillary fixation release, a novel method of intermaxillary fixation, in which super-elastic nickel-titan (Ni-Ti) alloy wires were applied at 2 places (Method A) was developed. Method A was compared to the previous method (Method B : fixing the jaw at 3 places with stainless steel wires), in terms of the time required to remove the wires and the number of pieces of cut wire left in the oral cavity and pharynx. The average time for removing the wires was  $14.5 \pm 9.9$  (mean  $\pm$  SD) seconds for Method A, and  $79.1 \pm 53.1$  seconds for Method B. The average time was significantly shorter in Method A than in Method B ( $p < 0.01$ ). The number of pieces of cut wire left was zero with Method A. These findings suggest that the novel method (Method A) provides quick and safe wire removal and improves the safety and quality of dentistry in emergency cases.

**Key words :** Intermaxillary fixation release, Ni-Ti alloy wire, Dental anesthesia, Oral and orthognathic surgery, Emergency in dentistry

### I. Introduction

The application of intermaxillary fixation with stainless steel wire is generally performed in orthognathic surgery after operations under general anesthesia. However, after the patients awake from general anesthesia, there is the possibility of airway obstruction due to depression of the tongue base and swelling of the pharynx, and emergencies, such as postoperative nausea and vomiting (PONV) may occur. Under these conditions, it is necessary to quickly and reliably cut and remove the fixing wires to release the intermaxillary fixation and secure the upper airway. We have previously encountered a situation, where a patient experienced upper airway obstruction 15 minutes after awaking from  $N_2O \cdot O_2 \cdot Sevoflurane$  anesthesia and extubation. We released the intermaxillary fixation and performed reintubation, but during the procedure, the patient accidentally aspirated a short piece of cut wire<sup>1)</sup>. Subsequently, we have investigated

---

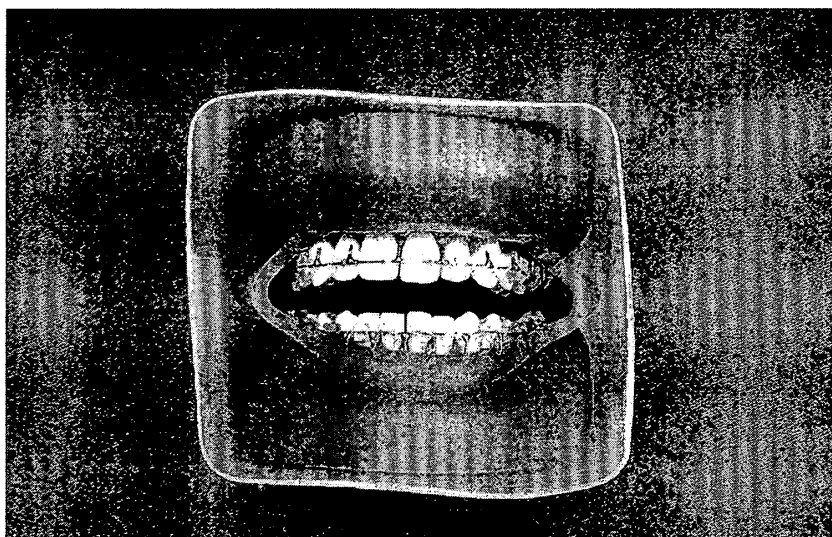
受付：平成16年9月29日

ways to improve the safety and quality of dental, oral and maxillofacial surgery. We have developed a safe intermaxillary fixation method with Ni-Ti alloy wires, in which intermaxillary fixation can easily be released and no pieces of cut wire are left behind in the mouth. In the present study, we used a model to compare our novel method to another conventional intermaxillary fixation method, in terms of safety and ease of release of intermaxillary fixation.

## II. Materials and methods

### 1 Preparation of an intermaxillary fixation model

An model for intermaxillary fixation was prepared by covering a dentition model (Dental Study Model 500A, Nisshin Inc.) with a bag-shaped silicone model of the lips, cheeks and pharyngeal mucosa, and by inserting the model into a plastic container (77mm high, 86mm wide, and 100mm deep)(Fig.1).



**Fig.1** Intermaxillary fixation model

An intermaxillary fixation model was prepared by covering a dentition model (Dental Study Model 500A, Nisshin Inc.) with a bag-shaped silicone model of the lips, cheeks and pharyngeal mucosa, and by inserting the model into a plastic box.

### 2 Intermaxillary fixation

One orthodontist (AY), certified by the Japanese Orthodontic Society, performed the following two intermaxillary fixation methods. In Method A, two nickel-titanium alloy wires (diameter : 0.23 mm, Super-elastic Ni-Ti alloy wires<sup>2)</sup>) were used to fix the jaw at two places (left and right maxillary and mandibular regions), and the ends of the wires were placed outside the mouth. Loop-shaped super-elastic Ni-Ti alloy wires, which were naturally straight, connected to either surgical hooks attached to the incisal and molars or surgical brackets attached to the left and right maxillary and mandibular regions. Also, an auxiliary wire was attached to the left and right sides, and the two auxiliary wires were bundled into a single wire and placed outside the mouth (Fig.2).

In Method B, the methods of Posnik JC<sup>3)</sup> were modified, intermaxillary fixation were achieved at 3

places (the anterior and left and right molar regions) using stainless steel wires (0.4 mm diameter)(Fig.3).

### 3 Operators for wire release

The intermaxillary fixation was released by 11 full-time staff (6 male and 5 female ; average age,  $38.9 \pm 9.0$  years), who were informed of the objective of the present study. They were 8 dentists (4 oral surgeons [2 certified by the Japanese Society of Oral and Maxillofacial Surgeon], 2 orthodontists certified by the Japanese Orthodontic Society, 2 dental anesthesiologists certified by the Japanese Dental Society of Anesthesiology), and 3 nurses with more than 10 years of nursing experience.

### 4 Fixation release

The intermaxillary fixation model was placed on a desk in a room with fluorescent lights between the hours of 17:00 and 21:00. There was no use of spot lights. The removal of intermaxillary fixation wire in an emergency in hospital ward at night was assumed. Each operator was instructed to release the intermaxillary fixation using How-pliers and wire cutters placed on the desk. During this procedure, the operators were prohibited from removing the model from the plastic container or moving the model in the left, right, up or down directions.

### 5 Assessments

1) The amount of time required to release intermaxillary fixation and removal of the wires (time for removing fixation wires)

The operators were asked to sit at the desk on which the model had been placed. At a start signal, they began releasing the intermaxillary fixation and removing the wires. The operators were instructed to say out loud, "I am done." when they had completed the procedure. The time was measured by one of the authors.

2) The number of pieces of cut wire in the pharynx, mouth and appliance, and outside the mouth

After removal of the model (including the silicone lip, cheek and pharyngeal mucosa model) from the plastic case, we counted the number of pieces of cut wire in the oral cavity and pharyngeal mucosa and outside the mouth. The operators were not allowed to pick up pieces of cut wire that fell during the procedure of the fixation release.

a) Number of pieces of cut wire in the mouth and pharyngeal mucosa

The number of pieces of cut wire in the silicone lips, buccal mucosa, and pharyngeal mucosa was counted.

b) Number of pieces of cut wire in the fixation appliance

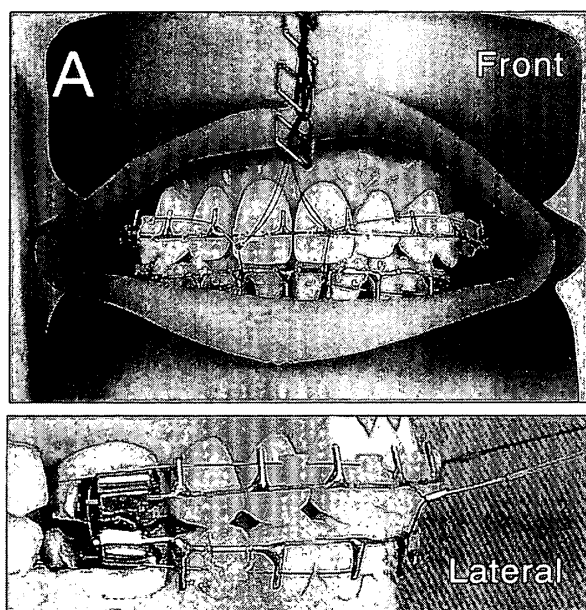
The number of pieces of cut wire in the appliance was counted.

c) Number of pieces of cut wire outside the mouth

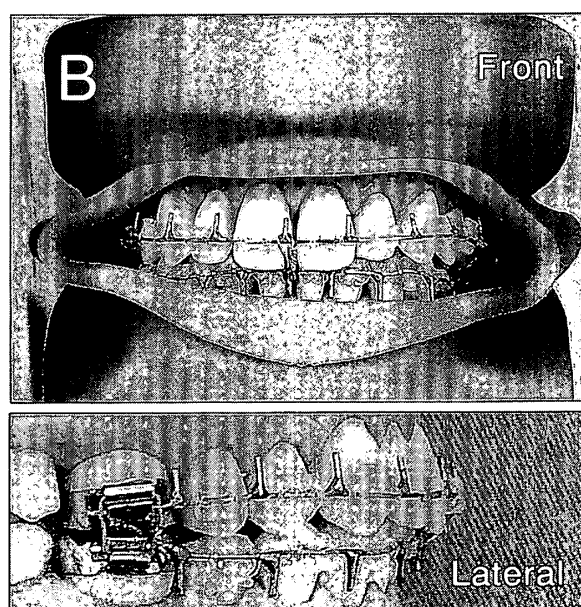
The number of pieces of cut wire that fell outside the mouth was counted.

### 6 Statistical analysis

Analyses were performed with Ystat 2004 (Igakutosho). Differences between the two methods were compared by the Willcoxon's signed rank test. The significance level was set at less than 5%.



**Fig.2** Intermaxillary fixation method A  
The figure shows photographs of the Intermaxillary fixation method A. Two nickel-titanium wires are used to wire the jaw at 2 places on the left and right sides. The excess wires and auxiliary wires are placed outside the mouth so that they can easily be removed.



**Fig.3** Intermaxillary fixation method B  
The figure shows photographs of the intermaxillary fixation method B. The current method is to wire the jaw at 3 pieces : anterior region and left and right molar regions. In the molar regions, the wire is inserted inside a tube, as shown in the lower picture.

### III. Results

#### 1 Time required to remove fixation wires

The average amount of time required to remove the fixation wires was  $14.5 \pm 9.9$  (mean  $\pm$  SD) seconds for Method A (range ; 4–35), and  $79.1 \pm 53.1$  seconds for Method B (range ; 31–230). The amount of time required to remove the fixation wires was statistically significantly shorter for Method A ( $p < 0.01$ ) (Fig.4).

#### 2 Numbers of pieces of cut wire in the pharynx, mouth and appliance, and outside the mouth

##### 1) Number of pieces of cut wire in the mouth and pharyngeal mucosa

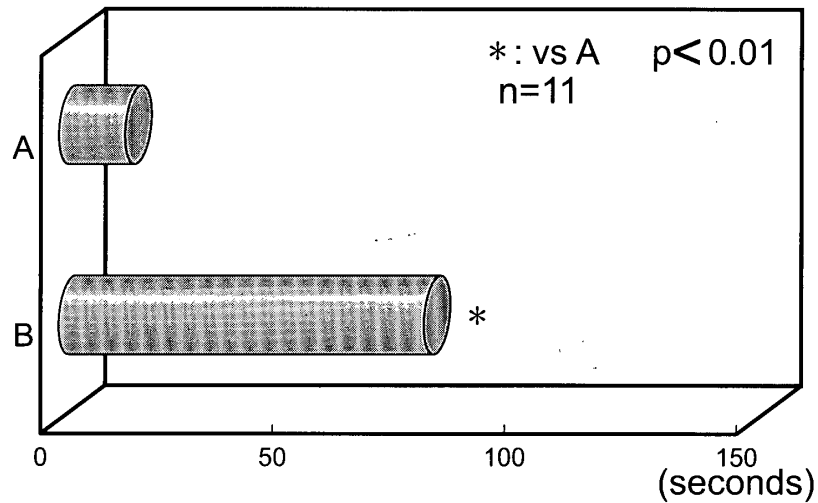
The numbers of pieces of cut wire in the mouth and pharyngeal mucosa was zero for Method A and  $0.3 \pm 0.6$  for Method B, this was not a statistically significantly different (Fig.5).

##### 2) Number of pieces of cut wire in the appliance

The number of pieces of cut wire in the appliance was zero for Method A and  $0.3 \pm 0.6$  for Method B. There was no statistically significant intergroup differences between the two methods.

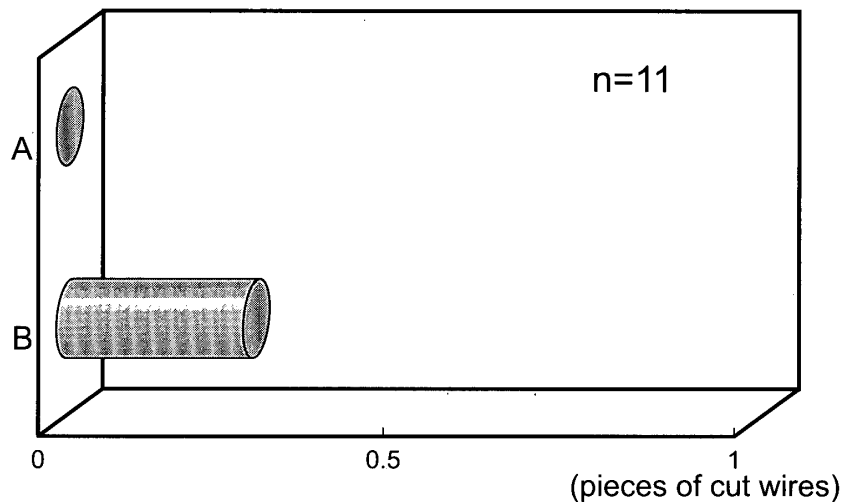
##### 3) Number of pieces of cut wire outside the mouth

The number of pieces of cut wire that fell outside the mouth in both Methods was zero.



**Fig.4** Time required for release of intermaxillary fixation

This graph was average time required for release of intermaxillary fixation. Method A amount of time required to remove the fixation wires was  $14.5 \pm 9.9$  (mean  $\pm$  9SD, range ; 4–35) seconds. Method B :  $79.1 \pm 53.1$  (range ; 31–230) seconds. The amount of time required to remove the fixation wires was significantly less for Method A than for the other method ( $p < 0.01$ ).



**Fig.5** The unumber of pieces of cut wires remaining in mouth and pharynx after intermaxillary fixation release

The number of pieces of cut wire in the mouth and pharyngeal mucosa was zero for Method A and  $0.3 \pm 0.6$  (mean  $\pm$  SD) for Method B. There was no significant difference between Methods A and B ( $p < 0.05$ ).

#### IV. Discussion

The present results showed that our novel method (Method A) is a safe intermaxillary fixation technique, because the fixative wires could be removed in a short period of time and as no pieces of cut wire are left behind in the mouth or pharynx. When cutting and removing the wires, while holding the end of the auxiliary wire using pliers, cutting the left and right wires together at a single location causes the wires to straighten, allowing them to be removed from the appliance in one piece. This makes it possible to remove the wires in a short period of time and avoid leaving behind short pieces of cut wire, which could

enter the trachea and bronchi. The time to remove the fixation wires was less for Method A, indicating that Method A is less dangerous than Method B. At our hospital (attached to the Dentistry, Health Sciences University of Hokkaido), following orthognathic surgery, intermaxillary fixation was previously performed using the old standard method, in which all teeth are fixed, and intermaxillary fixation is achieved at 7 places using stainless steel wires(diameter : 0.3mm)<sup>4)</sup>. Extubation of the endotracheal tube was performed after patients awoke from general anesthesia that was maintained using oxygen, nitrous oxide, and sevoflurane. One of our patients experienced upper airway obstruction 15 minutes after extubation. Consequently, the intermaxillary fixation was released and intubation was performed again, but the patient accidentally aspirated a piece of cut wire that was created during the wire removal procedure<sup>1)</sup>. Subsequently, we investigated ways to improve the safety and ease of fixation release and wire removal, and developed Method A using nickel-titanium alloy wires.

Although there have been several reports concerning medical accidents after the release of intermaxillary fixation at other institutions<sup>5)</sup>, and several studies on the characteristics of various intermaxillary fixation methods<sup>6,7)</sup>, there have been no studies of the safety and ease of wire removal comparing different methods using a model. Tamari et al.<sup>8)</sup> reported an intermaxillary fixation method in which patients can release the fixation appliance on their own in an emergency situation. The amount of time required for release of intermaxillary fixation depends on several factors, such as the degree of body movement, body position, swelling, amount of vomit in the mouth, room lighting, and availability of suction apparatus. The present results suggest that the safe release of intermaxillary fixation may take a long period of time. To promote safety associated with intermaxillary fixation, it is necessary to educate staff concerning rapidity and safe release of intermaxillary fixation in emergency cases such as PONV or upper airway obstruction.

## V. Conclusion

Using a simulation model for fixation and removal of the fixative wire, the time for removal of the fixation wires and the number of pieces of cut wire in the mouth and pharynx were compared for two intermaxillary fixation methods. In a novel method with Ni-Ti wires (Method A), wires could be removed in a shorter period of time without causing pieces of cut wire to be left behind in the mouth and pharynx, than with a previous method (Method B). These results indicate that the established novel method provides a quick and safe removal of intermaxillary fixation.

### References

- 1) Watanabe K, Kudo M, Ohke H, Kawakami J, Egami F, Muto T, Kanazawa M, Shibata T, Arisue M, Kawai T, Kokubu M, Shinya N : A case of upper airway obstruction and foreign body aspiration after sagittal split ramus osteotomy and inter-maxillary fixation. Higashi Nippon Dent J. 20(1) : 47-53, 2001.
- 2) Tomitsuka K, Yoshimasu H, Tanaka N, Shioiri S, Shioda S, Yoneyama T, Hamanaka H : Development of super-elastic Ni-Ti alloy wire for intermaxillary fixation of orthognathic surgery. Jpn.J.Oral Maxillofac. Surg 38(2) : 309-310, 1992.
- 3) Posnick JC : Facial Fractures in the Pediatric Patient, Fundamentals of Maxillofacial Surgery . Springer : 215-223, 1996.
- 4) Thoma KH : Fractures of mandible, Oral surgery fifth, Mosby : 524-571, 1969.
- 5) Fisher SE : Respiratory/cardiac arrest complicating intermaxillary fixation. Br J Oral Surg 20(3) : 192-195, 1982.
- 6) Goss AN, Chau KK, Mayne LH : Intermaxillary fixation : how practicable is emergency jaw release?. Anaesth Intensive Care 7(3) : 253-257, 1979.
- 7) Hennes JA, Wallen TR, Bloomquist DS, Crouch DL : Stability of simultaneous mobilization of the maxilla and mandible utilizing internal rigid fixation. Int J Adult Orthodon Orthognath Surg 3(3) : 127-141, 1988.
- 8) Tamari K, Shiratsuchi Y, Yokota S : An easily and immediately releasable intermaxillary fixation appliance for use after the correction of surgical orthognathic cases of jaw deformity or fracture. Journal of the Japanese Orthodontic Society 47 : 811-814, 1988.