

CASE REPORT

Primary cardiac sarcoma presenting as acute left-sided heart failure

Ranjan Pathak, MD^{1*}, Santosh Nepal, MD², Smith Giri, MD³,
Sushil Ghimire, MD¹ and Madan Raj Aryal, MD¹

¹Department of Medicine, Reading Health System, West Reading, PA, USA; ²Department of Medicine, Rapid City Regional Hospital, Rapid City, SD, USA; ³Department of Medicine, University of Tennessee Health Science Center, Memphis, TN, USA

Primary cardiac sarcomas are rare malignant tumors of the heart. Clinical features depend on the site of tumor and vary from symptoms of congestive heart failure to thromboembolism and arrhythmias. Echocardiography is helpful but definitive diagnosis is established by histopathology. Surgical resection is the mainstay of treatment, and the role of chemotherapy and radiotherapy is unclear. We report a case of primary cardiac sarcoma which presented with signs and symptoms of acute left-sided heart failure.

Keywords: *heart neoplasms; primary cardiac sarcoma; heart failure; left-sided heart failure*

*Correspondence to: Ranjan Pathak, Department of Medicine, Reading Health System, West Reading, PA 19611, USA, Email: ranjanrp@gmail.com

Received: 11 October 2013; Revised: 19 June 2014; Accepted: 20 June 2014; Published: 31 July 2014

Primary tumors of the heart are rare entities. Based on the data of 22 large autopsy series, frequency is estimated to be approximately 0.02% (1). The majority of these tumors are benign and are predominantly myxomas. Primary cardiac sarcomas (PCSs) are rare malignant primary tumors of the heart, accounting for almost 20% of all primary cardiac tumors (2). Little is known about these tumors as studies available on this matter are mostly confined to case reports and single institutional case series. Clinical presentation depends on the site of the tumor and varies from symptoms of congestive heart failure to thromboembolism and arrhythmias (3). In this report, we present a 35-year-old man who initially presented with signs and symptoms of left-sided heart failure caused by a PCS in the left atrium.

Case presentation

A 35-year-old Native American without significant medical history was transferred from another facility for the evaluation of worsening shortness of breath, cough, and hemoptysis of over 2 months. He also had a history of on and off fever, and weight loss of about 20 pounds. He was a known smoker with a history of occasional alcohol intake. Family history was unremarkable. There was no history of recent travel or contact with tuberculosis patients. On examination, vital signs were normal. Mild pallor was noticed with trace pedal edema. A few

crepitations at the right lung base were noted. Cardiac examination was unremarkable.

Laboratory examination revealed hemoglobin of 7.5 g/dL and white blood cell count of 7,900/mm³ (neutrophils 93%). Antinuclear cytoplasmic antibody (ANCA) panel and antinuclear antibody (ANA) were negative. A computerized tomography (CT) of the chest showed right-sided pleural effusion with mediastinal lymphadenopathy measuring 3.2 × 2.2 cm, and a ground glass density with coarsening of interstitial markings in bilateral lower lobes (Fig. 1). Pleurocentesis revealed pinkish fluid with 1,2750/mm³ red blood cells, 400/mm³ white blood cells (neutrophils 17%, monocytes 31%, and lymphocytes 45%), 1.3 g/dL protein, 80 IU/L lactate dehydrogenase, 115 mg/dL glucose, and pH of 7.49 without any malignant cells. Serum protein and glucose were 6.6 g/dL and 180 g/dL, respectively. Bronchoscopic evaluation was also done which was unremarkable.

Transthoracic echocardiogram (TTE) was done which revealed a large left atrial mass measuring 8.15 × 2.2 cm attached to interatrial septum on the left, causing pulmonary venous hypertension with an elevated right ventricular systolic pressure (RVSP). This was followed by a transesophageal echocardiogram (TEE) that revealed a mass completely occupying the left atrium and protruding across the mitral valve into the left ventricle with a mild mitral regurgitation. There was also invasion of the

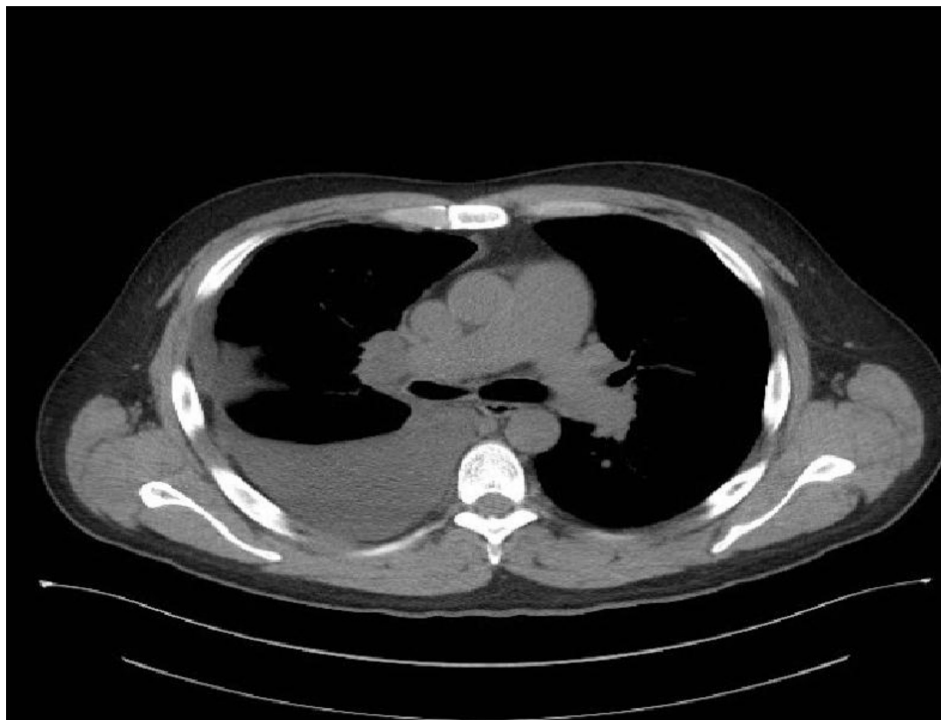


Fig. 1. CT scan without contrast showing right pleural effusion and right hilar adenopathy with suggestion of node or mass with size of 3.2×2.2 cm.

pulmonary veins. The RVSP was elevated at 120 mmHg with a severe tricuspid regurgitation (Fig. 2).

At the time of initial presentation with shortness of breath and hemoptysis, our differential diagnosis was broad and included connective tissue diseases, tuberculosis, lung malignancy, Wegener's granulomatosis, and heart failure. Bronchoscopy and CT of the chest ruled out lung malignancy. ANA, ANCA, and quantiferon tests were negative, ruling out SLE, Wegener's granulomatosis, and tuberculosis, respectively.

Cardiothoracic surgery was consulted for surgical excision of the mass, and the patient underwent a limited excision of the mass along with mitral valve repair. A post procedure TEE showed an improvement in the RVSP of 47 mmHg. Biopsy of the mass revealed high grade undifferentiated pleomorphic neoplasm composed of atypical cells with hyperchromatic nuclei and scattered atypical mitotic figures (Fig. 3). An immunochemical stain was positive for smooth muscle actin and desmin. Stain was negative for S-100, cytokeratin AE1/AE3, myogenin, and Myo D1.

A follow-up positron emission tomography (PET) scan showed residual disease activity in the pulmonary veins. Patient was started on chemotherapy with ifosfamide and doxorubicin and was referred to a higher center for additional management. Patient has received four cycles of chemotherapy so far and one dose of radiation treatment. At 9-month follow up, the patient is doing well without any complications.

Discussion

Primary cardiac tumors are known to be extremely rare (4). The majority of these tumors are benign, with the malignant tumors accounting for only about 25% of primary cardiac tumors (1). Cardiac sarcomas have been classified into angiosarcoma, fibrosarcoma, rhabdomyosarcoma, leiomyosarcoma, liposarcoma, pleomorphic malignant fibrous histiocytoma/pleomorphic undifferentiated sarcoma, and synovial sarcoma based on the classification proposed by WHO in 2004 (2). Among these subtypes, angiosarcomas and pleomorphic undifferentiated sarcomas are the most common ones (5).

PCS may arise at any age, with a reported mean age of 41 years (6). There is no specific sex predilection (2). Left atrium is the most common site of the tumor (2). Although, clinical presentation varies with the site of involvement, symptoms of congestive heart failure are the most common manifestation (4). About a third of these tumors have evidence of systemic metastasis at diagnosis (7). PCS located in the left atrium can cause obstruction of the mitral valve and can present with symptoms of mitral stenosis including dyspnea, cough, hemoptysis, and fatigue on exertion (8). Our patient presented with symptoms suggestive of mitral stenosis and constitutional symptoms of fever, weight loss, and fatigue, which have been reported previously, particularly with atrial myxomas (9).

Undifferentiated pleomorphic sarcoma, as in our case, is a high grade malignant tumor characterized histologically

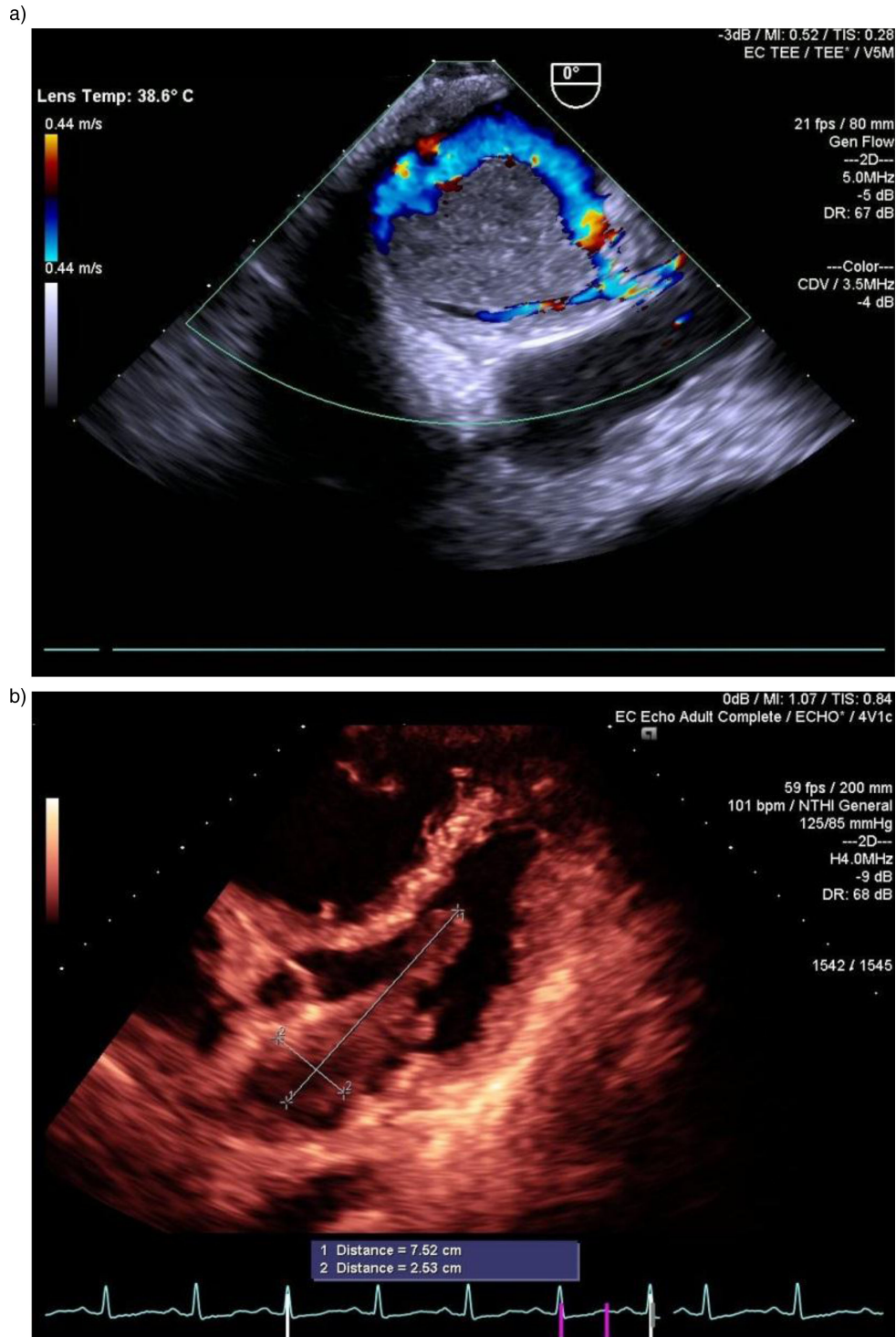


Fig. 2. (a and b) 2-D Echo showing atrial mass originating from left side of the interatrial septum extending beyond mitral valve to left ventricle (measuring 8.15 × 2.24 cm).

by heterogeneous cellularity, pleomorphic appearance, high mitotic activity, and areas of necrosis. In some cases, such tumors comprise of small embryonal looking cells with no further recognizable differentiation (10). Immunohistochemical staining is crucial in these cases with sarcomas being negative markers for epithelial,

neural, or endothelial elements (2). In our case, immunohistochemical staining was positive for desmin and smooth muscle actin suggesting a myogenic origin. However, absence of staining for S100, cytokeratin, myogenic, and myoD1 made neural, lipomatous, epithelial tumor or rhabdomyosarcoma unlikely.

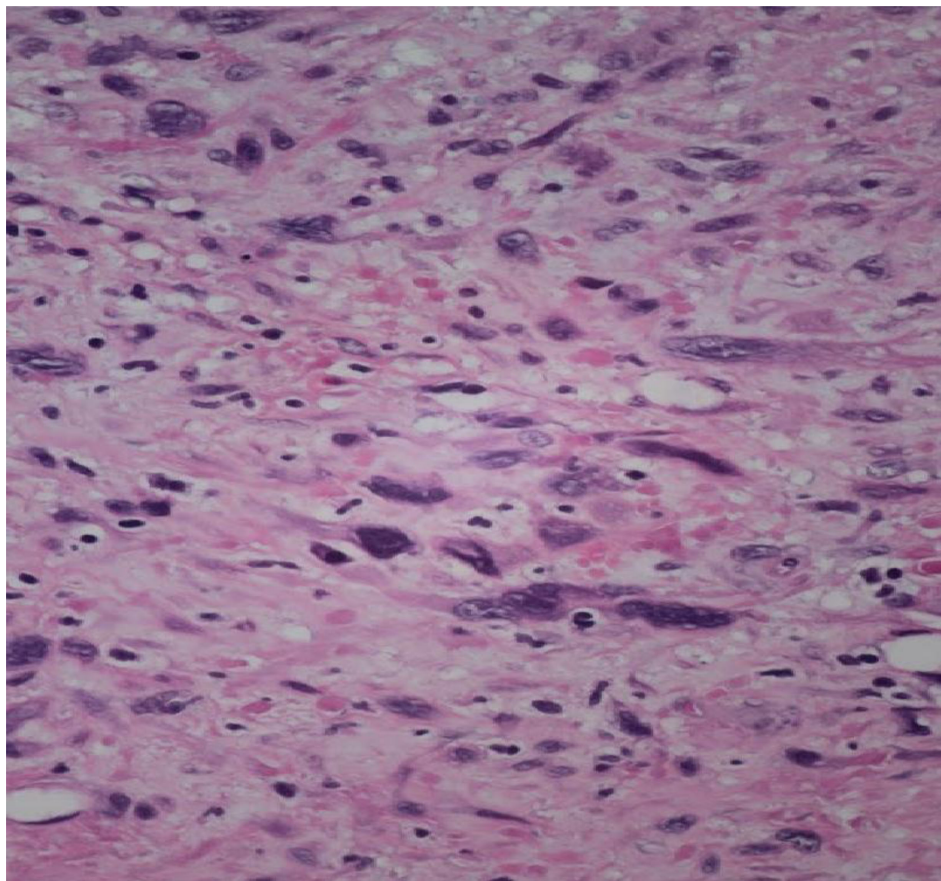


Fig. 3. Slide showing pleomorphic neoplasm with atypical cells with hyperchromatic nuclei scattered atypical mitotic figures.

The average duration of symptoms prior to diagnosis has been reported to be about 5 months (3). The electrocardiogram findings are non-specific and include conduction deficits, low voltage, T-wave changes, and rhythm abnormalities. A chest X-ray may be normal or show cardiomegaly (3). Echocardiography is the mainstay of diagnosis. TEE has been shown to be superior to a TTE in identifying the presence and site of origin of primary cardiac tumors (11). Although it might be difficult to differentiate benign cardiac tumors from malignant ones based on the echocardiographic findings alone, it has been suggested that the presence of non-septal origin, broad attachment on the wall, extension into pulmonary vein, semisolid consistency, and multiple masses can predict the likelihood of a left atrial mass being a malignant (12). A chest CT and MRI can be helpful in the better delineation of anatomy for surgical planning as well as for evaluation of tumor extension (3, 13).

Prognosis of PCS remains poor with a reported median survival of 5–11 months (3, 14). The most important factor dictating prognosis is the ability to achieve a complete surgical resection of the tumor. It has been observed that the median survival increases to 12–27 months with complete resection compared to 4–10 months where complete resection is not possible 15–21. Hence, resection

of tumor is indicated in all cases where possible and has an added benefit of effective palliation of symptoms (22). However because of close proximity to vital structures, it is not always possible to achieve a complete surgical resection. The role of neoadjuvant chemotherapy in these cases remains unclear. Collins et al. reported a 97% reduction in the tumor size after starting oral etoposide in an undifferentiated PCS in a 9-year-old girl. The tumor was subsequently amenable to surgical resection (23). Chemotherapy has been tried, most commonly with doxorubicin and/or ifosfamide containing regimens, with unclear survival benefit. However these studies have been limited by small sample size (12, 15, 19, 20). Hence, additional studies are warranted to identify the role of chemotherapy in these patients. Orthotopic cardiac transplantation has been tried but the experience is limited (24).

In conclusion, PCS are rare malignant tumors of the heart with poor prognosis. Clinical features depend on the site of tumor. In cases of left atrial tumors, patients present with signs and symptoms of left-sided heart failure. Echocardiography is helpful but definitive diagnosis requires histologic sampling. Surgical resection is the mainstay of treatment, and the role of chemotherapy and radiotherapy remains unclear.

Financial Disclosures

None.

Conflict of interest and funding

The authors have not received any funding or benefits from industry or elsewhere to conduct this study.

References

1. Reynen K. Frequency of primary tumors of the heart. *Am J Cardiol* 1996; 77(1): 107.
2. Orlandi A, Ferlosio A, Roselli M, Chiariello L, Spagnoli LG. Cardiac sarcomas: An update. *J Thorac Oncol* 2010; 5(9): 1483–9.
3. Ceresoli G, Passoni P, Benussi S, Alfieri O, Dell'Antonio G, Bolognesi A. Primary cardiac sarcoma in pregnancy: A case report and review of the literature. *Am J Clin Oncol* 1999; 22(5): 460–5.
4. Sarjeant JM, Butany J, Cusimano RJ. Cancer of the heart: Epidemiology and management of primary tumors and metastases. *Am J Cardiovasc Drugs* 2003; 3(6): 407–21.
5. Janigan DT, Husain A, Robinson NA. Cardiac angiosarcomas. A review and a case report. *Cancer* 1986; 57(4): 852–9.
6. Burke AP, Cowan D, Virmani R. Primary sarcomas of the heart. *Cancer* 1992; 69: 387–95.
7. Bakaeen FG, Reardon MJ, Coselli JS, Miller CC, Howell JF, Lawrie GM, et al. Surgical outcome in 85 patients with primary cardiac tumors. *Am J Surg* 2003; 186(6): 641–7; discussion 647.
8. Patil HR, Singh D, Hajdu M. Cardiac sarcoma presenting as heart failure and diagnosed as recurrent myxoma by echocardiogram. *Eur J Echocardiogr* 2010; 11(4): E12.
9. Peters MN, Hall RJ, Cooley DA, Leachman RD, Garcia E. The clinical syndrome of atrial myxoma. *JAMA* 1974; 230(5): 695–701.
10. Orlandi A, Ferlosio A, Dell'Anna V, Quitadamo R, Pellegrino A, Spagnoli LG. Undifferentiated sarcoma of the heart: A rare clinicopathologic presentation. *J Thorac Cardiovasc Surg* 2002; 124(1): 192–3.
11. Mugge A, Daniel WG, Haverich A, Lichtlen PR. Diagnosis of noninfective cardiac mass lesions by two-dimensional echocardiography. Comparison of the transthoracic and transesophageal approaches. *Circulation* 1991; 83(1): 70–8.
12. Kim JT, Baek WK, Kim KH, Yoon YH, Kim DH, Lim HK. A primary cardiac sarcoma preoperatively presented as a benign left atrial myxoma. *Yonsei Med J* 2003; 44(3): 530–3.
13. Alsara O, Rayamajhi S, Ghanem F, Skaf E, Abela GS. Primary cardiac pleomorphic sarcoma presenting as back pain in an 18-year-old man. *Tex Heart Inst J* 2013; 40(3): 339–42.
14. Blondeau P. Primary cardiac tumors – French studies of 533 cases. *Thorac Cardiovasc Surg* 1990; 38(Suppl 2): 192–5.
15. Bakaeen FG, Jaroszewski DE, Rice DC, Walsh GL, Vaporciyan AA, Swisher SS, et al. Outcomes after surgical resection of cardiac sarcoma in the multimodality treatment era. *J Thorac Cardiovasc Surg* 2009; 137(6): 1454–60.
16. Hamidi M, Moody JS, Weigel TL, Kozak KR. Primary cardiac sarcoma. *Ann Thorac Surg* 2010; 90(1): 176–81.
17. Kim MP, Correa AM, Blackmon S, Quiroga-Garza G, Weilbaecher D, Bruckner B, et al. Outcomes after right-side heart sarcoma resection. *Ann Thorac Surg* 2011; 91(3): 770–6.
18. Llombart-Cussac A, Pivot X, Contesso G, Rhor-Alvarado A, Delord JP, Spielmann M, et al. Adjuvant chemotherapy for primary cardiac sarcomas: The IGR experience. *Br J Cancer* 1998; 78(12): 1624–8.
19. Putnam JB, Jr., Sweeney MS, Colon R, Lanza LA, Frazier OH, Cooley DA. Primary cardiac sarcomas. *Ann Thorac Surg* 1991; 51(6): 906–10.
20. Simpson L, Kumar SK, Okuno SH, Schaff HV, Porrata LF, Buckner JC, et al. Malignant primary cardiac tumors: Review of a single institution experience. *Cancer* 2008; 112(11): 2440–6.
21. Truong PT, Jones SO, Martens B, Alexander C, Paquette M, Joe H, et al. Treatment and outcomes in adult patients with primary cardiac sarcoma: The British Columbia Cancer Agency experience. *Ann Surg Oncol* 2009; 16: 3358–65.
22. Centofanti P, Di Rosa E, Deorsola L, Dato GM, Patanè F, La Torre M, et al. Primary cardiac tumors: Early and late results of surgical treatment in 91 patients. *Ann Thorac Surg* 1999; 68: 1236–41.
23. Collins CL, Bartz PJ, Lal DR, Segura AD, Woods RK, Tower RL, 2nd. Significant response to oral etoposide in the treatment of an unresectable cardiac sarcoma. *J Pediatr Hematol Oncol* 2014; 36(4): e237–40.
24. Gowdamarajan A, Michler RE. Therapy for primary cardiac tumors: Is there a role for heart transplantation? *Curr Opin Cardiol* 2000; 15(2): 121–5.