

## CUTANEOUS CRYPTOCOCCOSIS: A MARKER OF LIFE THREATENING DISSEMINATED CRYPTOCOCCOSIS IN HIV AIDS

SKÓRNA KRYPTOKOKOZA: MARKER ZAGRAŻAJĄCY ŻYCIU ROZSIANEJ KRYPTOKOKOZY W HIV AIDS

Hari Kishan Kumar Yadalla<sup>1</sup>, Gandikota Raghu Rama Rao<sup>2</sup>

<sup>1</sup>Department of Dermatology, M.V.J. Medical College & Research Hospital, Hoskote, Bangalore, India

<sup>2</sup>Former Prof. & Head of Dermatology, Andhra Medical College, Consultant Dermatologist Surya skin care and research center, # 15-1-2, Gopal sadan, Naoraji Road, Maharanipeta, Visakhapatnam – 530002. Andhra Pradesh, India

**Corresponding author:** Dr. Hari Kishan Kumar Yadalla [drkishanyadalla@indiatimes.com](mailto:drkishanyadalla@indiatimes.com)

Our Dermatol Online. 2011; 2(4): 203-206

Date of submission: 15.07.2011 / acceptance: 10.09.2011

Conflicts of interest: None

### Abstract

Cryptococcosis is an opportunistic infection caused by a ubiquitous encapsulated yeast, *Cryptococcus neoformans*. Affects 5 – 10 % of patients with HIV worldwide. Disseminated cryptococcosis is one of the AIDS defining criteria and the most common cause of life threatening meningitis. Upto 20% of patients with disseminated disease can have skin involvement. Cutaneous lesions in disseminated cryptococcosis are seldom pathognomonic and portend neurological involvement. The significance of skin lesions may provide the first evidence of dissemination and indicate a poor prognosis, however, earlier recognition and treatment would improve survival. Herein we report a case of cryptococcal meningitis with skin lesions in a HIV seropositive patient.

### Streszczenie

Kryptokokoza jest zakażeniem oportunistycznym spowodowanym wszechobecnym, otoczkowym drożdżakiem, *Cryptococcus neoformans*. Dotyczy 5-10% pacjentów z HIV na całym świecie. Rozsiana kryptokokoza jest jednym z kryteriów określających AIDS i najczęstszą przyczyną zagrażającego życiu zapalenia opon mózgowych. U 20% pacjentów z rozsianą chorobą mogą występować zmiany skórne. Zmiany skórne w rozsianej kryptokokozy rzadko są znamienne dla tej choroby, a stan ogólny pogarsza zaangażowanie zmian neurologicznych. Obecność zmian skórnych może być pierwszym dowodem rozsiania oraz wskazać gorsze rokowanie, jednak wczesne rozpoznawanie oraz leczenie może poprawić przeżywalność. Opisujemy przypadek kryptokokowego zapalenia opon mózgowych z zmianami skórnymi u seropozytywnego pacjenta z HIV.

**Key words:** cutaneous cryptococcosis; HIV AIDS; dissemination

**Słowa kluczowe:** skórna kryptokokoza; HIV AIDS; rozsianie

### Introduction

Patients infected with HIV are susceptible to many opportunistic fungal infections. Cryptococcosis is an opportunistic infection caused by a ubiquitous encapsulated yeast, *Cryptococcus neoformans*, present in soil, dust and pigeon excreta. The main route of infection is inhalation of small yeast forms which are aerosolized. The pulmonary infection is primary site and most frequently self-limited and may be asymptomatic [1]. It occurs in 6 to 13% of patients with acquired immunodeficiency syndrome (AIDS), when their CD4 lymphocyte count is below 200/cmm [2]. Currently, AIDS represents the most common risk factor and cryptococcosis at other sites follows dissemination from

lungs. Most common recognized site of disseminated cryptococcosis is the central nervous system. Cutaneous cryptococcosis is rare (20%) and is a sign of dissemination and may precede life threatening disease by several weeks. The lesions may vary greatly in morphology and mimic molluscum contagiosum or penicillium marneffeii. Other presentations include acneiform papules or pustules, tumors, plaques, abscess, cellulitis, purpura, draining sinus, ulcers, bullae, subcutaneous swelling, herpetiform lesions, violaceous lichenoid lesions, nodular eruption on chin, a warty tumor on foot, a pseudofolliculitis & cryptococcosis mimicking Kaposi sarcoma [1,3]. These lesions are an

ominous sign as they are often the first presenting symptom of systemic disease.

### Case Report

A 38-year-old male presented with skin lesions over face, chest & back since 10 days and was admitted in neurology ward with severe headache, vomiting and seizures of 1 week duration.

Patient was a known HIV seropositive since 3 yrs. Patient was asymptomatic till he presented with above complaints. No history of similar complaints in the past. History of extramarital exposure – 5 yrs back. No history of any chronic illness and patient did not have antiretroviral therapy.

On Dermatological examination, multiple umbilicated papules and nodules present over face, front of the chest, upper back, upper arms & forearms (Fig. 1,2). Few lesions showed necrosis at the centre (Fig. 3). Excoriations were seen. No lesions were seen over palms, soles, oral mucosa and genitals. There was no cervical or axillary lymphadenopathy. Systemic examination of nervous system was remarkably normal with no signs of meningeal irritation and neck stiffness, deep tendon reflexes were normal.

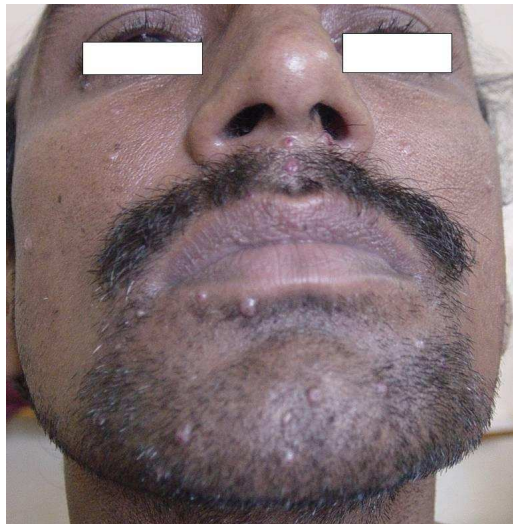

Figure 1. MC like lesions over face

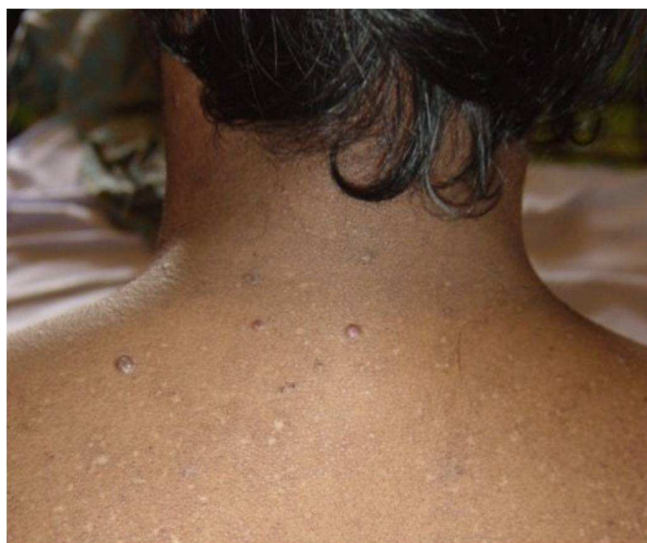

Figure 2. Papules and nodules over the upper back

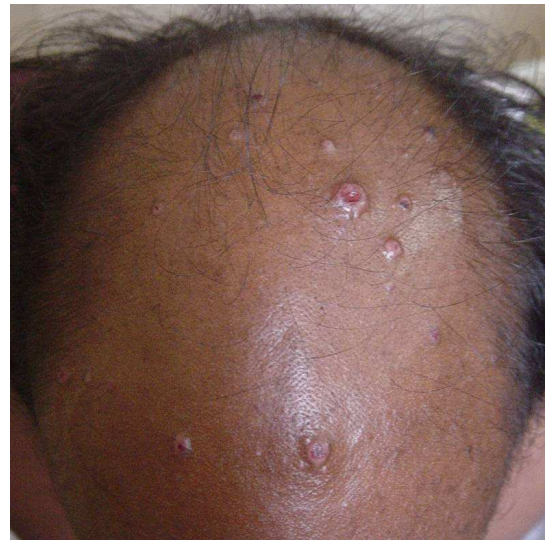

Figure 3. Lesions showing central necrosis

There was no hepatosplenomegaly and lungs were apparently normal. Haematological and Biochemical investigations were within normal limits except ESR was 95mm/1<sup>st</sup> hour. CD4 counts revealed 140 cells/cu mm. CSF examination revealed round bodies arranged singly & budding yeast cells upon gram staining (Fig. 4). Negative staining with congo red with mordant showed typical capsule surrounding budding yeast cells suggestive of *Cryptococcus* (Fig. 5). Plain CT scan of brain showed normal study. Histopathology of Skin biopsy showed thinning of epidermis and dermis loaded with small round bodies and deep inflammatory reaction in H&E (Fig. 6) and was positive for special stain Alcian blue which confirmed cryptococcosis. Culture showed cream colour mucoid growth seen in saboraud agar media and bio-chemical tests revealed urease positivity which was consistent with *Cryptococcus neoformans var. neoformans* (Fig. 7,8).

The patient was started on Inj. fluconazole IV along with ART and symptomatic treatment. Patient died four days later.

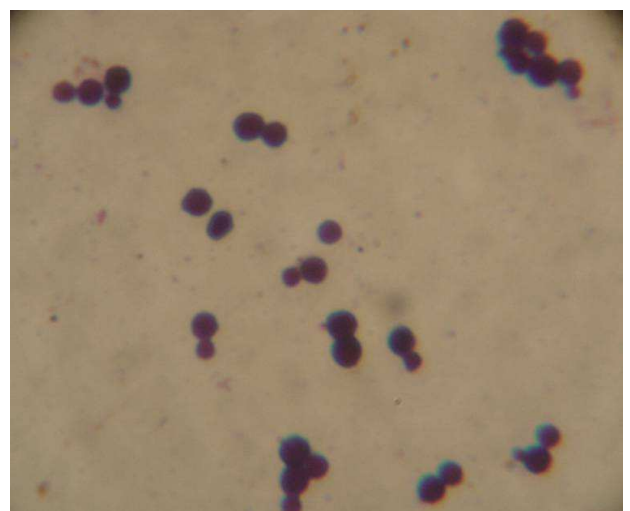


Figure 4. Gram stain showing round bodies arranged singly & budding yeast cells consistent with *Cryptococcus*



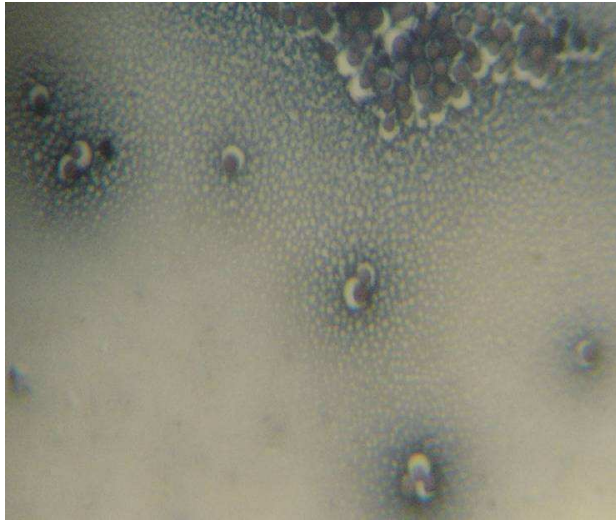


Figure 5. Negative staining with Congo red with mordant showing typical capsule surrounding budding yeast cells suggestive of *Cryptococcus*

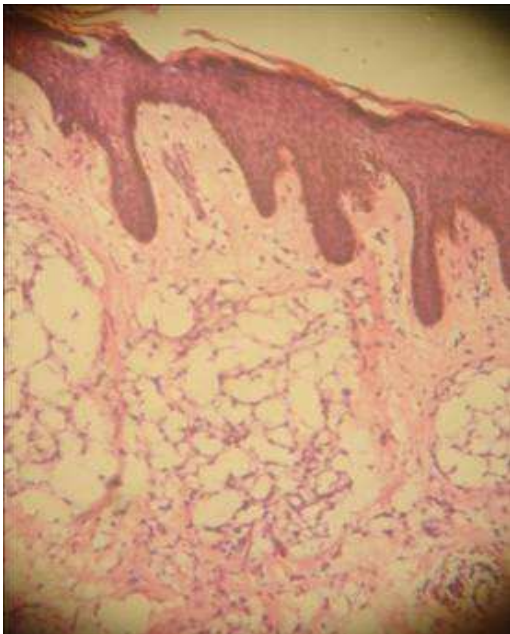


Figure 6. Histopathology of skin biopsy showed thinning of epidermis and dermis loaded with small round bodies and deep inflammatory reaction. (H&E, 40X)

### Discussion

Cryptococcosis is synonymous with Torulosis and European Blastomycosis. It is an acute, subacute or chronic infection caused by encapsulated yeast '*Cryptococcus neoformans*'. *Cryptococcus* has a predilection for brain & meninges, occasionally lungs & skin. Other organs involved rarely are bone marrow, heart, liver, spleen, kidneys, thyroid, lymph nodes & adrenal glands. *C. neoformans* was first demonstrated by Busse & Buschke in 1894. *C. neoformans* has two variants: a) *C. neoformans* var. *neoformans*, b) *C. neoformans* var. *gattii*. Serotypes A, D, or AD & B or C have been isolated. In Europe and USA, *neoformans* is found whereas in tropics & Africa *gattii* is seen. In HIV infection, *neoformans* variety is most common.



Figure 7. Culture shows cream-colored mucoid growth seen in Sabouraud agar media consistent with *Cryptococcus neoformans*




Figure 8. Bio-chemical tests revealed urease positivity which was consistent with *Cryptococcus neoformans* var. *neoformans*

*neoformans* exists as a saprophyte, abundant in soil enriched in pigeon droppings. *gattii* is isolated from leaf & bark debris from red gum trees. Main route of infection is inhalation of small yeast forms which are aerosolized. Most common age group affected between 30 to 60 years, uncommon in children.

Predisposing factors include immunodeficient states – AIDS, malignant lymphomas, sarcoidosis, collagen disease, carcinoma, systemic corticosteroid therapy & patients with immunosuppression following renal transplantation [4-6].

Cryptococcosis a 'Sleeping giant' among fungal diseases, Ajello in 1980. But after emergence of AIDS, cryptococcosis an 'Awakening giant' [7]. It affects 5 – 10 % of patients with AIDS worldwide. Upto 20% of

patients with disseminated disease have skin involvement, mostly by strains of serotype D. Mortality is high with 30% fatality inspite of antifungals [6].

In immunocompetent individuals, CNS is the most common system involved. It presents as chronic meningitis and focal brain lesions with classic signs of meningismus, changes in consciousness, mental changes & nerve palsies. In AIDS patients, symptoms of meningitis are minimal. Evidence of wide dissemination is by positive blood cultures or multiple skin lesions.

In pulmonary infection, chest signs include nodular shadows, cavitation & pleural effusion.

In disseminated disease, cutaneous lesions may precede or follow the signs of involvement of CNS & lungs. It occurs in about 10% of patients and are seldom pathognomonic. Molluscum contagiosum like lesions, i.e, umbilicated skin-coloured papules or nodules is the most common morphology of cutaneous cryptococcosis in 54% [6,7]. Acneiform papules or pustules are characteristic of widespread systemic infection. Most common sites are head & neck in 78%, but may be widespread [8]. Other cutaneous lesions include pustules, cellulitis, ulceration, panniculitis, palpable purpura, subcutaneous abscess and pyoderma gangrenosum like lesions [6].

In HIV AIDS, cryptococcosis is suspected when papulonodular necrotizing skin lesions like MC are seen with neurological or pulmonary disease. Other varieties described are herpetiform lesions, violaceous lichenoid lesions, acneiform papulopustular & nodular eruption on chin, a warty tumor on foot, a pseudofolliculitis and cryptococcosis mimicking Kaposi sarcoma [6,9]. Commonest differentials are Molluscum contagiosum, other systemic mycoses like Histoplasmosis and infections such as *Penicillium marneffi*. In all suspicious lesions, it is important to take biopsy & culture.

Systemic diagnosis is done with aid of serology, blood culture and lumbar puncture, CSF serology, culture and India ink staining. Cutaneous diagnosis is confirmed by skin biopsy with special stains for capsule (eg: mucicarmine or alcian blue) and culture or Tzanck preparation.

## REFERENCES:

1. Quartaralo N, Thomas I, Li H, Weiderkehr, Schwartz RA, Lambert WC: Cutaneous cryptococcosis. *Acta dermatol* 2002; 11: 4.
2. Murakawa GJ, Kerschmann R, Berger T: Cutaneous cryptococcus infection and AIDS. Report of 12 cases and review of literature. *Arch dermatol* 1996; 132: 5.
3. Vasanthi S, Padmavathy BK, Gopal R, Sundaram RS, Manoharan G: Cutaneous cryptococcosis among HIV infected patients. *Indian J Med Microbiol.* 2002; 20: 165-166.
4. Hay RJ. Yeast infections. *Dermatologic Clinics.* 1996; 14: 113-124.
5. Hay RJ, Moore M. Mycology: In : Champion RH, Burton JL, Burns DA, Brettnach SM, eds. *Rook/Wilkinson/Ebling Textbook of Dermatology.* 6<sup>th</sup> ed. London. Blackwell Science, 1998: 1372-3137.

Direct Microscopy of (Blood or CSF) with India ink or Nigrosin mounts shows large (5-15 micron) budding cells with characteristic capsules. Culture characteristics shows colony growth which is soft, cream to pale brown & mucoid. Microscopy shows yeasts alone and no filaments.

Physiological tests reveal growth at 37<sup>0</sup>C, Urease production, Phenoloxidase production and assimilation of creatinine and various carbohydrates. Serological tests are rapid and specific, useful in disseminated or CNS infection by detection of cryptococcal capsular antigen using Latex agglutination test or ELISA assay of blood or CSF. Very high titres are found in AIDS patients in serum & CSF. Non-AIDS patients with single, localised skin lesions are antigen-negative. Histopathology of tissue sections with special stains reveal large encapsulated budding cells with very little inflammation or granulomatous reaction [4-7]. In Non-AIDS Patients, mainstay of treatment is I.V amphotericin B combined with flucytosine. In AIDS patients, I.V amphotericin B with or without flucytosine for 7-14 days to induce remission, followed by long term oral maintenance with fluconazole 200-400 mg/day is recommended [10].

## Conclusions

Cutaneous cryptococcosis may resemble molluscum-contagiosum, awareness of this rare opportunistic infection is warranted in clinical practice. Moreover, Cutaneous cryptococcosis lesions may precede the more serious disseminated forms, the early recognition and confirmation of these lesions may help the clinician to start appropriate therapy at the right time.

## Acknowledgements

We are extremely thankful and express our sincere regards to Dr. Y. Prabhakar, MD. DM, Consultant Neurologist, Dr. Jyothi Padmaja, MD (Micro), Prof. & HOD, Andhra medical College, Viskhapatnam. Dr. P. Raja Kumari, MD (Path), Arya Diagnostics

6. Hay RJ: Deep fungal infections. In : Freedberg IM, Eisen AZ, Wolff K. etal, eds. *Fitz Patricks's Dermatology in General Medicine.* 5<sup>th</sup> eds. New York. McGraw Hill, 1999: 2383-2389.
7. Aberg JA, Powderly WG: Cryptococcosis and HIV-HIV insite knowledge base chapter. University of California, San Francisco 2002.
8. Rajetha D, Janaki C, Sentaiselvi G, Janaki VR: Disseminated cutaneous cryptococcosis in a patient with HIV infection *Indian J Dermatol* 2004; 49: 90-92.
9. Chiewchanvit S, Chuaychoo B, Mahanupab P: Disseminated cryptococcosis presenting as molluscum-like lesions in three male patients with acquired immunodeficiency syndrome. *J Med Assoc Thai.* 1994; 77: 322-326.
10. Powderly WG: Medscape fungal infections – Diagnosis and management in patients with HIV disease. CME.