

REVIEW ARTICLE

Impacted Canine: Diagnosis and Prevention

¹Abhishek Choudhary, ²Ankur Chaukse, ³Ritesh Chhajed, ⁴Ashutosh Dubey, ⁵Madhuri Gupta, ⁶Ramit Chaddha

ABSTRACT

Since impacted canines are encountered often, with an incidence rate of 1 to 2% in the general population, it is important for a dentist to identify the signs and symptoms of this condition and follow interceptive treatment or orthodontic treatment. Features of buccal or palatal canine impaction show lack of canine bulges in the buccal sulcus and asymmetry in dental midlines. Diagnosis of impacted canines at an early age of 8 to 10 years can reduce further complications, such as surgical exposure or root resorption of the lateral incisors, and will reduce the total duration of the treatment. The interceptive orthodontic treatment procedure with extraction of the primary maxillary cuspids can prevent impaction of the permanent maxillary cuspids and additional sequelae.

Keywords: Canine, Impacted canines, Impacted teeth diagnosis, Interceptive treatment, Orthodontics.

How to cite this article: Choudhary A, Chaukse A, Chhajed R, Dubey A, Gupta M, Chaddha R. Impacted Canine: Diagnosis and Prevention. *J Orofac Res* 2015;5(3):80-83.

Source of support: Nil

Conflict of interest: None

INTRODUCTION

An impacted tooth is one that fails to erupt into the oral cavity after clinical and radiographic assessment within the specific time due to adjacent teeth position, dense overlying bone, thick soft tissue coverage, or a genetic abnormality.¹ The most commonly impacted tooth in the oral cavity is mandibular third molar followed by maxillary third molar because they are usually last to erupt between the ages of 17 and 21. The second most

frequently impacted teeth are permanent maxillary canines with the incidence rate of 1 to 2%.² The reason for impaction is due to the long path of eruption before it emerges into the oral cavity.³ Maxillary deciduous canine extraction may help in allowing the impacted canines to correct their paths of eruption and erupt into the oral cavity with relatively good alignment.⁴ Diagnosis of impacted canines at an early age (8–10 years) can reduce further complications, such as orthodontic root resorption of the lateral incisors and surgical exposure in future.⁵

PREVALENCE AND ETIOLOGY

Studies have found that 85% of impacted maxillary permanent canines are palatal impactions, while only 15% are labial impactions. Buccally placed canines are impacted as they lack adequate space for their eruption, while palatally placed cuspids rarely erupt due to denser and thick palatal bone. Palatally erupting or impacted maxillary canines are commonly seen in females as compared with males with a ratio of 2:1, have high family association, and are common in Caucasians than Asians.⁶ Unilateral canine impactions are more common compared with bilateral, which is only 8 to 10%.⁷ The exact etiology of impacted canines is still unknown, but the guidance theory and the genetic theory that were earlier proposed explain the etiology to some extent. The “guidance theory of palatal canine displacement” proposes that impaction of canine is a consequence of local predisposing causes, which include congenitally missing lateral incisors, odontomes, supernumerary teeth, and soft tissue barriers, which obstruct eruption of the canine. It is seen that maxillary canines are the last teeth to develop and travel a long path before they erupt into the dental arch, and so chances of space required for eruption are less. The second theory explains on a genetic cause.⁸ Palatal impacted canines are seen with other dental abnormalities like tooth size, shape, and number of discrepancies, which Baccetti⁹ reported to be linked genetically.

DIAGNOSIS

Early detection of impacted maxillary canines may reduce treatment time, complexity, complications, and cost. The clinician can look for the presence and position of the

^{1, 3, 5, 6}Postgraduate Student, ²Reader, ⁴Assistant Professor

^{1, 2, 6}Department of Orthodontics, People's Dental Academy Bhopal, Madhya Pradesh, India

³Department of Orthodontics, People's College of Dental Sciences and Research Centre, Bhopal, Madhya Pradesh, India

⁴Department of Periodontics, People's Dental Academy Bhopal, Madhya Pradesh, India

⁵Department of Oral Medicine and Radiology, People's Dental Academy, Bhopal, Madhya Pradesh, India

Corresponding Author: Abhishek Choudhary, D-24 Sterling Oasis, Rajat Vihar, Hoshangabad Road, Bhopal, Madhya Pradesh, India, Phone: +919893257264, e-mail: dr.abhi2013@gmail.com

canines using three simple methods: Visual inspection of bulging canines, palpation, and radiographs.

Visual Inspection

Clinical signs of palatal impaction include lack of a canine bulge in the buccal sulcus by the age of 9 to 10 years, overretained primary canines, and asymmetry in the midline. Primary cuspids that are retained beyond the age of 13 years and have no significant mobility strongly indicate displacement and impaction of permanent canines or their absence.¹⁰

Palpation

Using the index fingers of both hands with simultaneous palpation of the buccal and lingual mucosa, position of impacted canine can be assessed. Eruption time of a maxillary canine varies from 9.3 to 13.1 years.

Radiographs

A panoramic radiograph is taken in conjunction with two periapical views using Clarke's Rule (Buccal Object Rule), which states that on changing the angulation of X-ray tube in mesial or distal direction, if impacted teeth image moves in the direction of X-ray beam then it is lingually or palatally impacted, while if image moves away from direction of beam then it is buccally placed. Ericson and Kuroi¹¹ found that periapical radiographs allowed accurate location of the teeth in 92% of the cases they evaluated.

Although periapical films are diagnostic for transverse position, occlusal radiographs are more accurate for determining the positions of the canines relative to the midline.¹² But the main disadvantage of occlusal radiographs is that it cannot provide exact location and shape of impacted canine, which is important in treatment planning. Lateral cephalograms are also helpful in assessing the anterior-posterior position of the displaced tooth, as well as its inclination and vertical location in the alveolus.¹³ Computed tomography (CT) is more accurately used nowadays for locating the impacted cuspid in three dimensions and for diagnosing associated lesions such as root resorption of adjacent teeth with its disadvantage of more radiation exposure compared with panoramic.

Interceptive Treatment

In mild class I malocclusions where permanent maxillary canine is impacted or erupting buccally or palatally, the preventive treatment of choice is extraction of the primary cuspids with Dewel's method within 10 to 13 years of age. Power and Short¹⁰ showed that interceptive extraction

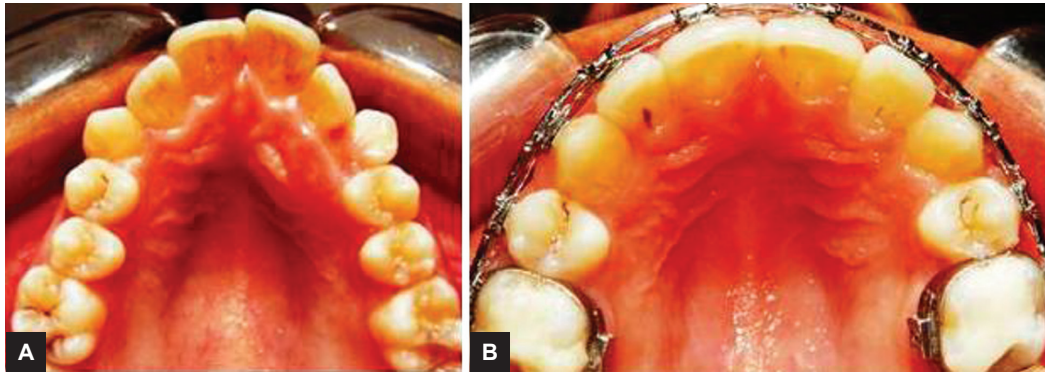
of the primary canine completely resolves permanent canine impaction in 62% of cases. As a general rule, when the degree of overlap between the permanent maxillary cuspid and the neighboring lateral incisor exceeds half the width of the incisor root, the chances for complete recovery are poor. Studies have also shown that prognosis of palatally placed canines with crown tip angulated distal to midline of lateral incisor is better.¹⁴

OPTIONS FOR TREATING PALATALLY IMPACTED CANINES

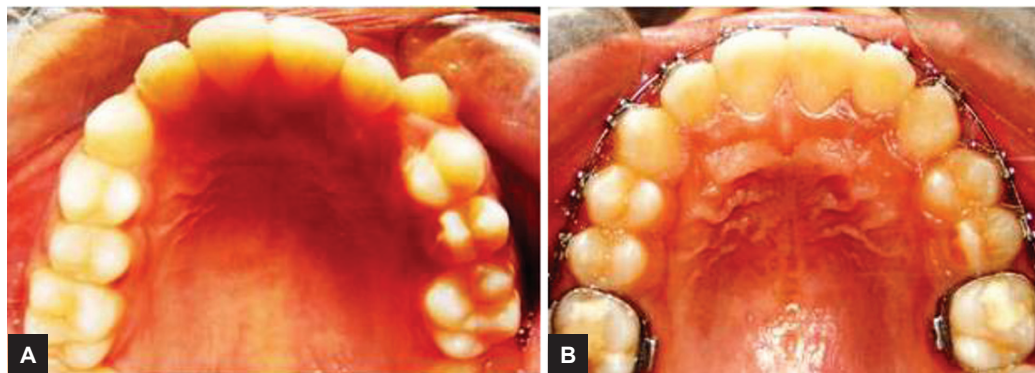
Preda et al¹⁵ found that more mesially positioned canine cusp tips are associated with greater resorption of lateral incisor roots. Unerupted or partly erupted cuspids may increase the risk of infection and cystic lesions and compromise the life span of neighboring lateral incisors due to root resorption.^{2,15,16} As discussed earlier, they can be treated as interceptive and do not require surgical uncovering. These include extraction of maxillary deciduous canines at the appropriate time and in the appropriate situation, use of cervical headgear to create maxillary arch length, use of a palatal expander to increase maxillary arch length,¹⁷ and use of brackets and arch wires to create additional space in the alveolar ridge during the mixed dentition to allow the eruption of maxillary canine naturally (Figs 1 and 2).

There are two strategies for sequencing the orthodontics and the surgical uncovering procedure. One is to place brackets on the maxillary teeth, creating sufficient space for the impacted canine, followed by surgically uncovering the impacted tooth and placement of dressing for few weeks. After a short healing period of a few weeks, traction of impaction can be started.

The other strategy is to uncover a palatally displaced canine, leaving a light cure dressing over it for a few weeks and allow the tooth to erupt autonomously into the palate.¹⁸ Usually 6 to 9 months later, these teeth will have erupted sufficiently so that orthodontic appliances can be placed, and the canines can be moved into the dental arch.¹⁹ One disadvantage of this technique is that the crown of the canine is still buried beneath the palatal bone. When a force is placed on the canine, it moves against the bone to bring in occlusion. This places enamel in direct contact with the bone, since no cells of enamel promote resorption of the palatal bone but it is likely to be because of pressure necrosis. When such crown is moved through the bone, it does not osseointegrate, which can result in the creation of an alveolar bone defect on the margins of canine.²⁰ When a tooth is impacted in bone for a long time in adults, the tissue surrounding the periodontal ligament (PDL) can undergo disuse



Figs 1A and B: Patient 1. (A) Left retained deciduous canines with permanent impacted canine in upper arch, and (B) after alignment of permanent impacted canine



Figs 2A and B: Patient 2. (A) Left retained deciduous canines with permanent impacted canine in upper arch, and (B) after alignment of permanent impacted canine

atrophy. It is seen that as soon as any tooth is uncovered surgically, it will have a functional PDL that will respond to an orthodontic force. The PDL response is better in children compared with that in adults. Early traction in adults often results in little or no movement, and the orthodontist might assume that the canine is ankylosed. The functional PDL takes a few months to develop in around a recently uncovered tooth in an adult.

Presurgical Orthodontic Treatment

Adequate anchorage should be provided by the arch to bring canine down, which can be done either by fixed appliances making them one unit or by placing an implant²¹ and engaging the canine directly into it. The width of impacted canine should be kept in mind, which is between 7.5 and 8 mm normally, so that enough of space can be created before bringing it down.

Gingivectomy Technique

This technique is preferred on buccally impacted canines where the tip of canine is located near cemento-enamel junction of lateral incisor. Remember to leave 3 mm of keratinized gingival for esthetic consideration during the procedure by Kirkland knife or fine round diamond bur. Approximately 1/2 to 2/3rd of crown should be exposed for adequate working and bonding. Bracket is placed with

ZOE dressing for 2 to 3 weeks, after that traction can be applied. This is the simplest method causing minimum trauma to the tissues done in clinics.

Apically Displaced Technique

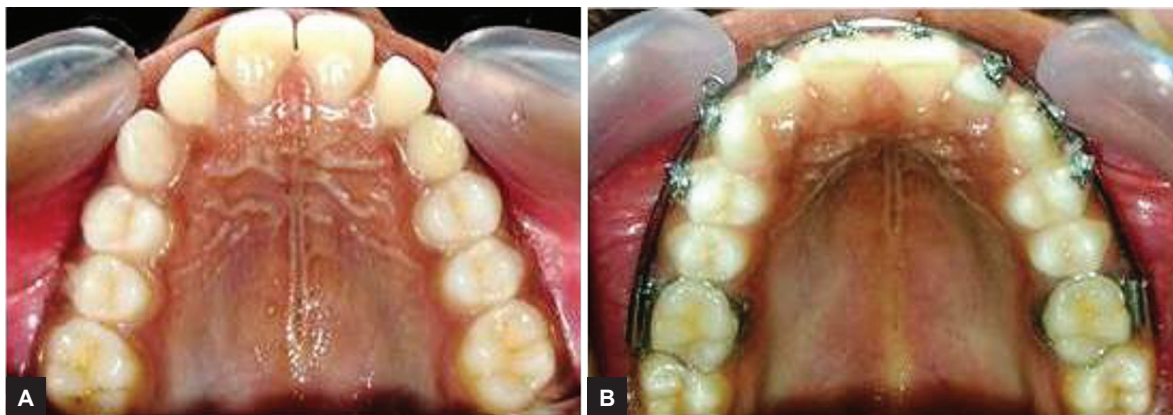
This technique has the advantage of preserving keratinized gingival, but it also leads to irregular gingival margins.

Closed Technique

This technique is the most preferred choice in cases where canines are positioned more apically; e.g., near nasal spine or mid of alveolar crest, as it preserves the esthetics also. Due to more amount of bone removal for bracket placement, this technique is used (Fig. 3). Before flap closure, teeth are luxated with periosteal or straight elevator so that eruption can be enhanced. The orthodontic activation can be done after a week.

Conditions where extraction of impacted canine is advised:

- Impacted canine is ankylosed
- During movement if external or internal root resorption occurs
- Canine root is severely dilacerated
- If there are pathologic changes (e.g., cystic formation, infection)
- The patient does not desire orthodontic treatment.



Figs 3A and B: (A) Upper arch bilateral retained deciduous canines with permanent impacted canine, and (B) bilateral impacted canines surgically exposed and brought in alignment

CONCLUSION

The prevalence of maxillary canine impaction is significant and thus dental practitioners should be aware of dental anomalies like palatally impacted maxillary canines, so that early recognition and interceptive treatment is possible. Early radiographic examination of the patient is important for treatment planning. The need for complex orthodontic therapy and surgical intervention may be avoided if the deciduous canines are extracted appropriately. Uncovering of impacted canines can prevent formation of cysts, periodontal defects, and resorption of the roots of the adjacent teeth. We also conclude that preorthodontic uncovering and autonomous eruption of palatally impacted maxillary canines may simplify procedure with minimum complications and reduced treatment time at the right age. Therefore, a good knowledge of the clinician may improve situations in future treatment options, which can have a significant impact on the treatment outcome.

REFERENCES

1. Thilander B, Jakobsson SO. Local factors in impaction of maxillary canines. *Acta Odontol Scand* 1968 May; 26(2): 145-168.
2. Rayne J. The unerupted maxillary canine. *Dent Pract Dent Rec* 1969 Feb;19(6):194-204.
3. Bass TB. Observations on the misplaced upper canine tooth. *Dent Pract Dent Rec* 1967 Sep;18(1):25-33.
4. Becker A, Zilberman Y, Tsur B. Root length of lateral incisors adjacent to palatally-displaced maxillary cuspids. *Angle Orthod* 1984 Jul;54(3):218-225.
5. Bjerklin K, Kurol J, Valentin J. Ectopic eruption of maxillary first permanent molars and association with other tooth and developmental disturbances. *Eur J Orthod* 1992 Oct;14(5): 369-375.
6. Bishara SE. Impacted maxillary canines: a review. *Am J Orthod Dentofacial Orthop* 1992 Feb;101(2):159-171.
7. Shapira Y, Kuflinec MN. Early diagnosis and interception of potential maxillary canine impaction. *J Am Dent Assoc* 1998 Oct;129(10):1450-1454.
8. Lappin M. Practical management of the impacted maxillary cuspid. *Am J Orthod Dentofacial Orthop* 1951 Oct;37(10): 769-778.
9. Baccetti T. A controlled study of associated dental anomalies. *Angle Orthod* 1998 Jun;68(3):267-274.
10. Power SM, Short MB. An investigation into the response of palatally displaced canines to the removal of deciduous canines and an assessment of factors contributing to favourable eruption. *Br J Orthod* 1993 Aug;20(3):217-223.
11. Ericson S, Kurol J. Radiographic examination of ectopically erupting maxillary canines. *Am J Orthod Dentofacial Orthop* 1987 Jun;91(6):483-492.
12. Jacobs SG. Reducing the incidences of palatally impacted maxillary canines by extraction of deciduous canines: a useful preventive/interceptive orthodontic procedure. Case reports. *Aust Dent J* 1992 Feb;37(1):6-11.
13. Caminiti MF, Sandor GK, Giambattistini C, Tompson B. Outcomes of the surgical exposure, bonding, and eruption of 82 impacted maxillary canines. *J Can Dent Assoc* 1998 Sep;64(8):572-574, 576-579.
14. Rohlin M, Rundquist L. Apical root anatomy of impacted maxillary canines. A clinical and radiographic study. *Oral Surg Oral Med Oral Pathol* 1984;58:141-147.
15. Preda L, Fianza L, Ericson S, Kurol J. Early treatment of palatally erupting maxillary canines by extraction of the primary canines. *Eur J Orthod* 1988;10:283-295.
16. O'Neill J. Maxillary expansion as an interceptive treatment for impacted canines. *Evid Based Dent* 2010;11(3):86-87.
17. Leonardi M, Armi P, Franchi L, Baccetti T. Two interceptive approaches to palatally displaced canines: a prospective longitudinal study. *Angle Orthod* 2004 Oct;74(5): 581-586.
18. Clark D. The management of impacted canines: free physiologic eruption. *J Am Dent Assoc* 1971 Apr;82(4): 836-840.
19. Ferguson J, Parvizi F. Eruption of palatal canines following surgical exposure: a review of outcomes in a series of consecutively treated cases. *Br J Orthod* 1997 Aug;24(3):203-207.
20. Kokich V. Surgical and orthodontic management of impacted maxillary canines. *Am J Orthod Dentofacial Orthop* 2004 Sep;126(3):278-283.
21. Park HS, Kwon OW, Sung JH. Micro-implant anchorage for forced eruption of impacted canines. *JCO* 2004 May;38(5): 297-302.