

## CASE REPORT

# Rare Case of Buccal Exostosis in Edentulous Mandibular Body Region

<sup>1</sup>Amita Rani, <sup>2</sup>Rajni Poswal

## ABSTRACT

Buccal exostoses are benign, broad-based surface masses of the facial aspect of the maxilla and less commonly, the mandible. It is believed that this is one way, bone responds to stresses applied to it. They begin to develop in the early adulthood and may slowly enlarge over the years. To the best of our knowledge, it is the second reported case of single buccal exostosis in mandibular molar region and first of its kind in edentulous mandible. The following paper presents a very rare and unique case of buccal-sided mandibular molar exostosis in an edentulous mandible of an old female and its surgical management.

**Keywords:** Buccal exostosis, Edentulous mandible, Torus mandibularis.

**How to cite this article:** Rani A, Poswal R. Rare Case of Buccal Exostosis in Edentulous Mandibular Body Region. *J Orofac Res* 2015;5(2):65-67.

**Source of support:** Nil

**Conflict of interest:** None

## INTRODUCTION

An exostosis is a localized, peripheral bony overgrowth of benign nature with unknown etiology. It may be a nodular, flat or pedunculated protuberance located on the alveolar surfaces of the jaw bones.<sup>1</sup> Multiple exostoses occasionally occur in the same individual. They may appear as isolated, discrete bony overgrowths on the facial aspect of alveolar bone in young, dentate subjects or as somewhat less usually found multiple exostosis in maxilla (torus palatinus) and in mandible (mandibular tori).<sup>2</sup>

The etiology of oral bony exostosis is still not clear. Racial, autosomal dominant factors, dental attrition, and even nutritional factors have been suggested as having

an influence. In the jaws, depending on the anatomic location they are named as torus palatinus (TP), torus mandibularis (TM), or buccal bone exostosis (BBE). Buccal bone exostosis (BBE) is benign, broad-based surface masses on facial aspect of maxilla and less commonly, the mandible in ratio of 5.1:1 respectively.<sup>3</sup>

They begin to develop in early adulthood and may very slowly enlarge over the years. They are self-limiting and painless, but occasionally may become several centimeters across. Buccal exostoses are significant with regards to prosthodontics because they may interfere with denture insertion. Also, buccal exostosis may be traumatized and interfere with oral hygiene procedures.<sup>2</sup>

The case report presented below illustrates a unique and rare presentation of a unilateral exostosis on the buccal aspect of mandible body in molar region, in an edentulous mandible of an old female and its successful management by the author.

## CASE REPORT

A female patient aged 65 years, reported to our department with complaint of vague facial pain extending from the angle of mandible to body region since 3 months. Pain was mild in nature, which increases in intensity on applying pressure to overlying skin. There was no associated history of any kind of trauma to face. On clinical examination extraorally, there was approximately 1 × 1 cm hard, fixed and rounded, well-circumscribed bony projection palpable in right edentulous mandibular body-angle region. Overlying skin was slightly tender to pressure. Intraoral examination showed no significant findings, apart from the same fixed rounded bony protuberance palpable on buccal aspect of mandibular right molar region through the mucosa. She had edentulous mandible with only two anterior teeth present and she was not using artificial denture (neither fixed nor removable). The residual ridge was smooth with normal pink colored overlying mucosa. There was no paresthesia, mobility, crepitus or discharge in mandible molar region. Cervical lymph nodes were not palpable.

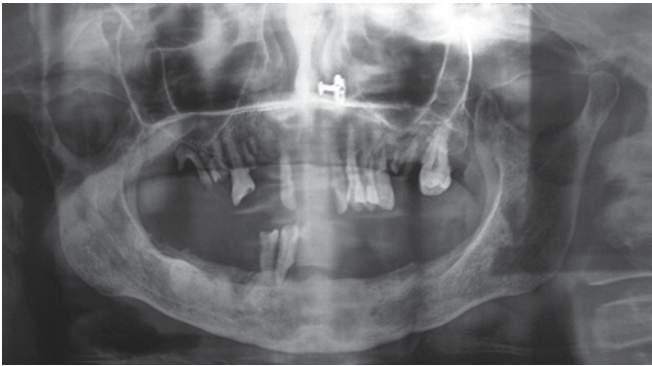
As the bony outgrowth was easily palpable clinically on buccal cortex of mandibular body region so radiographic examination was done only with orthopantomogram (OPG) and no other radiographic projection

<sup>1</sup>Senior Resident, <sup>2</sup>Junior Resident

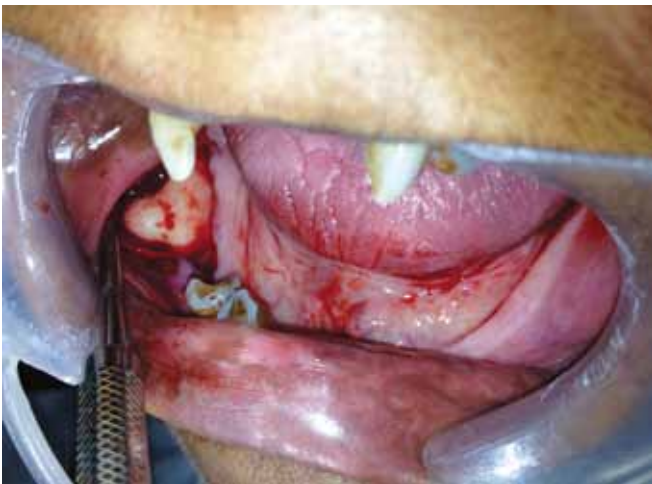
<sup>1</sup>Department of Dentistry, University College of Medical Sciences and Guru Teg Bahadur Hospital, New Delhi, India

<sup>2</sup>Department of Neurology, Postgraduate Institute of Medical Sciences, Rohtak, Haryana, India

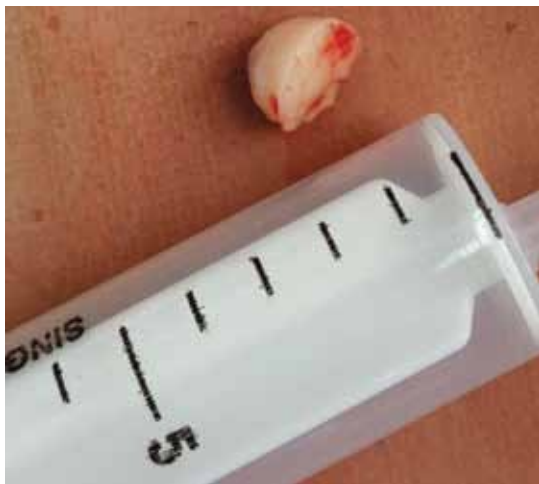**Corresponding Author:** Amita Rani, Senior Resident Department of Dentistry, University College of Medical Sciences and Guru Teg Bahadur Hospital, New Delhi, India Phone: 7838120250, e-mail: poswal.dramita152@gmail.com



**Fig. 1:** Panoramic radiograph showing well-circumscribed radiopaque mass, oblong shaped in mandible right body region



**Fig. 2:** Surgical exposure showing buccal exostosis in right mandibular molar region



**Fig. 3:** Excised exostosis

was used. Panoramic radiograph revealed a 1 × 1 cm well circumscribed radiopaque mass, oblong shaped in mandible right molar region, lying above the mandibular canal (Fig. 1). There was no evidence of residual root in mandibular molar region.

Correlating the clinical and radiographic findings, provisional diagnosis of a buccal exostosis was made. Routine blood investigations were within normal limit. Under local anesthesia, surgical exposure was achieved

using crestal incision in molar region. Exostosis was exposed and seen as rounded bony projection stalked at right angle to buccal cortex of mandible in molar region (Fig. 2). Surgical procedure to separate the exostosis from buccal cortex consisted of placing the molt periosteal elevator below exostosis over the lower border of mandible. The bony growth was cut from superior end with #702 SS white straight fissure bur. After making groove at superior border, a fine chisel was used and with two to three soft blows with mallet, the exostosis was completely dislodged (Fig. 3). The rough buccal bone was smoothed with acrylic trimming bur. After thorough irrigation, primary closure achieved. Histopathological examination confirmed the diagnosis. Postoperative course was uneventful.

## DISCUSSION

The prevalence rate of tori in populations with different ethnic origins varied from 0 to 66% for TP, and from 0 to 85.7% for TM.<sup>4,5</sup> Maxilla is shown to exhibit the highest prevalence rate of 5.1:1 in comparison to mandible with male population afflicted more than female 1.66:1, in all intraoral locations.<sup>3</sup> Usually, the bicuspid and molar areas are the affected sites yet occasionally they may occur in other parts of the jaw, either as a smooth bulging of the bone surface continuous with the adjacent area or as discrete, multilocular spherical projections with a broad base that forms a nodular cluster.<sup>6,7</sup> Buccal exostosis in edentulous are found less commonly than tori.<sup>8</sup>

Buccal exostosis is found only on the facial surface of the alveolar bone, usually the maxillary alveolus.<sup>9</sup> Buccal surface involvement, however, typically in the mandible has been an unusual occurrence. Basha and Dutt reported a rare case of BBE at the angle of the mandible.<sup>10</sup>

Torus mandibularis is recognized as a bony ridge or a series of bony lumps or nodules appearing on the lingual surface of alveolar margin of mandible, generally in premolar region. The torus may be bosselated or multilobulated but exostosis is typically a single, broad based, smooth surfaced mass, with a central sharp, pointed projection of bone producing tenderness immediately beneath the surface mucosa.

Exostoses might perform a buttressing function reinforcing the alveolar process against excessive occlusal force. Therefore, the altered function may lead to exostosis development in genetically predisposed population. The reduction of muscular forces following edentulism leads to remodeling and obliteration of exostoses in some patients.<sup>11</sup>

There is increasing correlation between marked exostosis and a significant attrition of teeth in some older subjects.<sup>12</sup> A similar pathophysiology may be implicated

in the occurrence of reactive subpontic exostosis, which may develop from the alveolar crestal bone beneath the pontic of a posterior bridge. Stress causes the crestal alveolar bone to grow under the pontic along a vector opposing the forces of occlusion.<sup>12</sup>

Less commonly, solitary exostosis may occur in response to local irritation from the alveolar bone beneath free gingival grafts and skin grafts. Presumably the graft acts as a stimulant to the periosteum thus, commencing new bone synthesis.

Exostoses should be differentiated from compact osteoma, cancellous osteoma, osteochondroma, organized subperiosteal hematoma, mature ossifying fibroma (expanding cortical lamina), periosteal osteosarcoma or chondrosarcoma. Osteomas are benign, developmental neoplasms, which induce proliferation of dense, compact or coarse, cancellous bone usually in an endosteal or periosteal location.<sup>13,14</sup> Neither the torus nor the bony exostosis require treatment unless it becomes large enough to interfere with function, denture placement, causes recurring traumatic surface ulceration (usually from sharp food).<sup>15</sup> When treatment is elected, the bony mass may be removed using bone cutting bur or chiseled off through the base of the lesion. If surgical treatment is not an option in edentulous patients, denture may be relieved to avoid pressure injury on the overlying mucosa.

The novelty of this article lies with the fact that the single bony outgrowth in question was found along the buccal aspect of the edentulous mandible molar region in a female patient; all factors emphatically documented in literature of least predilection. To the best of our knowledge it is the first and unique case of buccal bone exostosis in edentulous mandibular molar region and was successfully managed surgically.

## REFERENCES

1. Stafne EC, Gibilisco JA. Oral roentgenographic diagnosis. 4th ed. Philadelphia: WB Saunders Company; 1975. p. 89-91.
2. Sonnier KE, Horning GM, Cohen ME. Palatal tubercles, palatal tori and mandibular tori: prevalence and anatomical features in a US population. *J Periodontol* 1999;70:329-336.
3. Jankittivong A, Langlais R. Buccal and palatal exostoses: prevalence and concurrence with tori. *Oral Surg Oral Med Oral Pathol Oral RadioI Endod* 2000;90:48-53.
4. Pechenkina EA, Benfer RA Jr. The role of occlusal stress and gingival infection in the formation of exostoses on mandible and maxilla from Neolithic China. *Homo* 2002;53:112-130.
5. Kerdpon D, Sirirungrojying S. A clinical study of oral tori in the southern Thailand: prevalence and the relation to parafunctional activity. *Euro J Oral Sci* 1999;107:9-13.
6. Stephen TS, Robert CF, Leslie F. Company. Principle and Practice of Oral Medicine. Philadelphia: WB Saunders company; 1984. p. 476-477.
7. Bruce I, Ndanu TA, Addo ME. Epidemiological aspects of oral tori in a Ghanaian community. *Int Dent J* 2004;54:78-82.
8. Shafer WG, Hine MK, Levy BM. A textbook of oral pathology. 4th ed. Philadelphia: WB Saunders Co; 1983. p. 167-169.
9. Rezaei RF, Jackson JT, Salamat K. Torus palatinus, an exostosis of unknown etiology: review of the literature. *Compend Contin Educ Dent* 1985;6:149-152.
10. Basha S, Dutt SC. Buccal-sided mandibular angle exostosis: a rare case report. *Contemp Clin Dent* 2011;2:237-239.
11. Axelsson G, Hedegård B. Torus palatinus in Icelandic schoolchildren. *Am J Phys Anthropol* 1984;67:105-112.
12. Burkes EJ, Marbry DL, Brooks RE. Subpontic osseous proliferation. *J Prosthet Dent* 1985;53:780-785.
13. Kashima K, Rahman OI, Sakoda S, Shiba R. Unusual peripheral osteoma of the mandible: report of 2 cases. *J Oral Maxillofac Surg* 2000;58(8):911-913.
14. Bosshardt L, Gordon RC, Westerberg M, Morgan A. Recurrent peripheral osteoma of mandible: report of case. *J Oral Surg* 1971;29(6):446-450.
15. Puttaswamaiah RN, Galgali SR, Gowda VS. Exostosis: a donor site for autograft. *Indian J Dent Res* 2011;22(6):860-862.