

CASE REPORT

Cone Beam Computed Tomography Evaluation and Surgical Treatment of an Open Apex Case with Biodentine

¹Fahad Ahmed, ²Mahesh Pratap Singh, ³Manish Agrawal, ⁴Kunwar Suhrab Singh, ⁵Khushboo Mansoori, ⁶Priyank Sethi

ABSTRACT

Trauma to the facial region is a common event with injury of teeth. The treatment is aimed at the functional restoration of tooth along with complete biologic healing. Biodentine (Septodont, St Maurdes Fossés, France) introduced in the year 2011. It is a calcium silicate based material and is claimed by the manufacturers as repair of crown and root dentin repair treatment, perforations, resorptions, apexification, and root end fillings. This article presents a case report of cone beam computed tomography (CBCT) diagnosis and surgical management of an open apex case using biodentine as retrograde filling material.

Keywords: Open apex, Blunderbass canal, Biodentine, CBCT, Root end filling.

How to cite this article: Ahmed F, Singh MP, Agrawal M, Singh KS, Mansoori K, Sethi P. Cone Beam Computed Tomography Evaluation and Surgical Treatment of an Open Apex Case with Biodentine. *J Orofac Res* 2014;4(4):217-221.

Source of support: Nil

Conflict of interest: None declared

INTRODUCTION

Success of endodontic treatment relies on two factors: complete asepsis and three dimensional obturation of the root canal system. One of the biggest challenge in endodontic treatment is management of immature teeth, with absence of natural constriction of teeth. Therefore, endodontic treatment of open apex case is aimed at formation of an apical barrier or a stop against which root canal filling material can be placed. This technique is termed as apexification.¹

The formation of an apical barrier dates back to the use of calcium hydroxide powder to the concept of over instrumentation to produce blood clot.² Popular materials like mineral trioxide aggregate (MTA) has been shown to be a very successful for root end filling material.³ The main drawbacks of this material so far have been longer setting time and unfriendly handling, which made the technique sensitive methods, such as apical closure even more difficult.⁴

Like MTA, Biodentine is a new calcium silicate based cement. It has physical and chemical properties similar to various Portland cement derivatives.⁵ Laurent et al through his experiment proved Biodentine to be bio-compatible.⁶ Biodentine, as claimed by its manufacturers is a bioactive dentin substitute indicated for the repair of root perforations, apexification and root end filling. With modification in its composition by addition of setting accelerators and softeners, supplied in a predosed capsule along with shorter setting time make Biodentine a user-friendly material.^{7,8}

This case report presents the cone beam computed tomography (CBCT) evaluation and surgical treatment of an open apex case with retrograde filling of Biodentine.

CLINICAL REPORT

A 20-year-old male patient, with the chief complaint of pain and discolored upper front tooth (Fig. 1), had trauma to the teeth due to a fall more than 10 years ago. After the trauma for the maxillary left central incisor, patient was symptomless for some time but in due course of time, developed periodic swelling and now from the past 6 months he has intermittent pus discharge. On consulting a dentist, endodontic treatment for the left central incisor was started but as the pain was progressively increasing, so the patient was referred by the dentist to the People's College of Dental Sciences and Research Centre, Bhopal. The patient's medical history was noncontributory and vital signs were normal. Tenderness on percussion and palpation was absent. The periodontal status was normal (probing depth <3 mm) with no mobility. Radiographic examination of the central incisor revealed a large blunderbuss canal in relation to maxillary left central incisor. The root end had thin dentinal walls with apical flaring (Fig. 2). The lateral

^{1,4,5}Postgraduate Student, ²Professor and Head, ³Professor
⁶Senior Lecturer

¹⁻⁵Department of Conservative Dentistry and Endodontics
People's College of Dental Sciences and Research Centre
Bhopal, Madhya Pradesh, India

⁶Saraswati Dhanwantari Dental College and Hospital, Parbhani
Maharashtra, India

Corresponding Author: Fahad Ahmed, Postgraduate Student
Department of Conservative Dentistry and Endodontics
House No. 106, Rajeev Nagar, Lal Ghati, Bhopal-462001
Madhya Pradesh, India, Phone: +91-7566517266, e-mail:
dr.ahmedfahad@gmail.com

incisor had intact periodontal ligament space and showed complete root formation. Electric and cold tooth vitality testing were performed for all the maxillary anterior teeth. The maxillary left central incisor gave a negative response and all the other teeth gave a positive response. According to the clinical and radiographic findings, there were two treatment options available for the central incisor, either a nonsurgical endodontic retreatment with apexification or surgical retrograde filling. Taking into consideration the modern guidelines, CBCT (Kodak CS3D 9000) (Figs 3A to E) evaluation was done to check the width of the remaining tooth structure. Since, the width was found to be less than 1 mm retrograde approach was preferred.

Treatment Protocol

The tooth was not anesthetized since it was found to be nonvital. After isolation with rubber dam, access was modified in the central incisor with Endo Access Bur (Dentsply Maillefer, Ballaigue, Switzerland) with water spray. Working length was estimated by an apex locator (Root ZX mini—J Morita Mfg. Corp. Kyoto, Japan), but due to inconsistent reading, an additional intraoral periapical radiograph (IOPAR) (Fig. 4) was also taken for confirmation. Minimal instrumentation of the left central incisor with Reamer # 80 (Medicept UK Ltd.) was carried out with a light action to avoid further weakening of the already thin dentinal walls along with passive irrigation with 10 ml of 3% sodium hypochlorite and 2% chlorhexidine solution (Sigma Chemicals, St Louis, MO, USA) alternatively with sterile saline. Irrigation was carried out with side-vented irrigation needles (RC Twents irrigation needle, Prime Dental Products Pvt. Ltd. Mulund, Mumbai) keeping them 1 mm short of the radiographic apex and no attempt was made on shaping the canal. The canal was dried with a large size paper point and an

intracanal dressing of calcium hydroxide and iodoform combination (Metapex™, META Biomed Co. Ltd., Korea) was given. The access cavity was temporarily sealed with temporary filling material Coltosol-F (Coltene/Whaledent, Altstätten/Switzerland) and the patient was recalled after 2 weeks. After 2 weeks, when the patient was asymptomatic. The tooth was isolated followed by removal of intracanal dressing with copious irrigation. The canal was flushed with 10 ml of 3% hypochlorite followed by 10 ml of sterile saline and dried with absorbent paper points. Region in relation to 12, 11, 21, 22 was anesthetized using 2% lidocaine with 1:100000 adrenaline. A crevicular incision was given with a no. 15 BP blade and full thickness mucoperiosteal flap was raised beyond the mucogingival junction (Fig. 5). Curettage was done. Biodentine was placed through retrograde approach with respect to 21 with help of Carrier 4880 (GDC, India) (Figs 6A and B). The flap was then placed back and sutures were placed. Patient was recalled after 2 weeks. The hardness of the apical plug was checked with an endodontic plugger and the remaining portion of the canal was sealed using thermoplastic gutta-percha (DiaGun, DiaDent Group international, Chungcheongbuk-do, Korea) and restored (Fig. 7) Follow-up clinical examination and IOPAR after 1 year showed complete healing (Fig. 8).

DISCUSSION

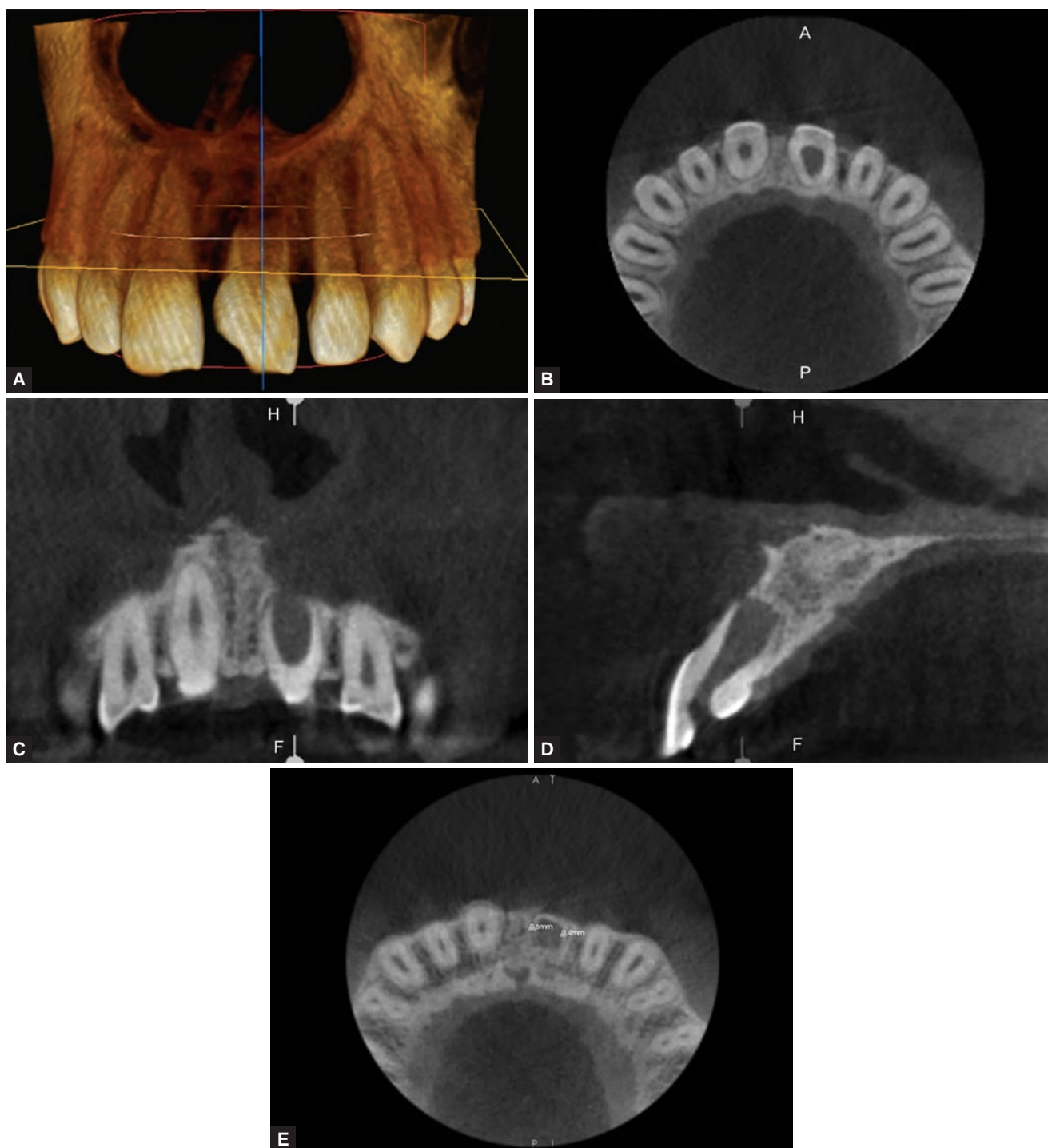
The goal of this treatment was to obtain an apical barrier to prevent the passage of bacterial toxins into the periapical tissues from the root canal and technically this barrier is necessary for compaction of root filling material during obturation.^{9,10} Promoted as a dentin substitute, Biodentine (Septodont, Saint Maur des Fosses, France) can also be used as an endodontic repair material. In its composition the powder mainly consists of tricalcium silicate, with the addition to the powder of CaCO₃ and ZrO₂ while

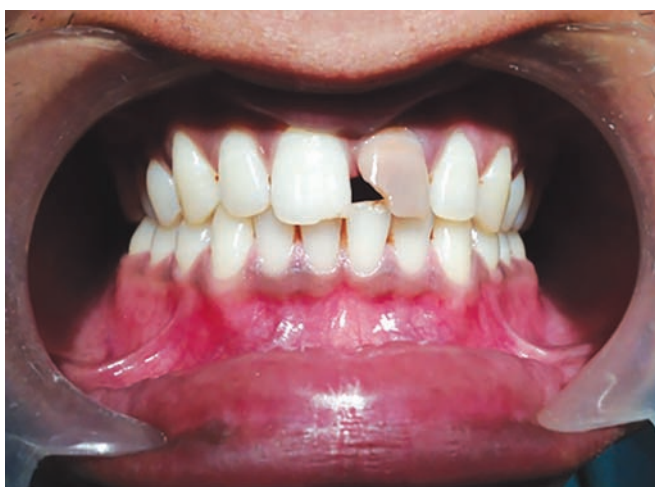

Fig. 1: Preoperative photograph

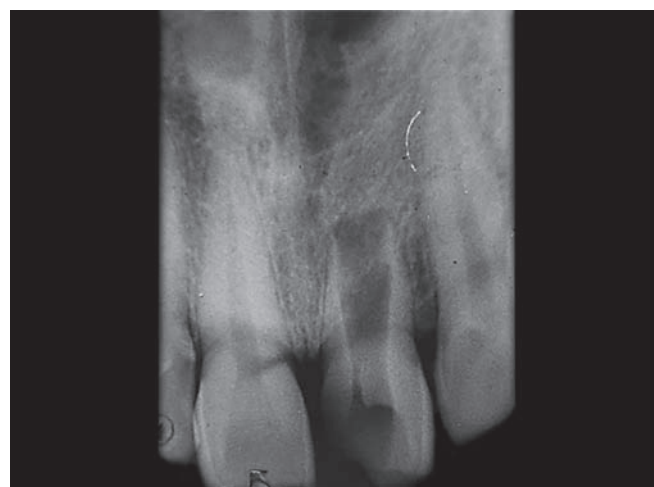

Fig. 2: Preoperative IOPAR



Figs 3A to E: Cone beam computed tomography images: (A) CBCT view, (B) CBCT axial-view, (C) CBCT coronal-view, (D) CBCT sagittal-view and (E) axial-view of apical portion (remaining tooth width 0.6 and 0.4 mm)

liquid component has calcium chloride (CaCl_2), as setting accelerator, in the water reducing agent.⁶

Cone beam computed tomography is an excellent tool for the assessment of various endodontic challenges as it is more accurate in detection and localization of endodontic problems. It can provide additional information in three dimensions when compared to two-dimensional conventional IOPA radiography, and thus helps in the diagnosis, treatment planning, management and follow-up of cases more predictably.^{11,12} In this case, both IOPA

radiographs and CBCT scans were done for diagnosis. Cone beam computed tomography images in all the three planes helped in the measurement assessment of apical region tooth width which was found to be less than 1 mm, which was not possible with IOPAR.

To dry the canal dry and make it infection free, Meta-pak was used as intracanal medicament for 2 weeks. As reported by Hasheminia et al, the fracture resistance of tooth is not affected by use of calcium hydroxide for such a short-term.¹³ By inducing odontoblast differentiation

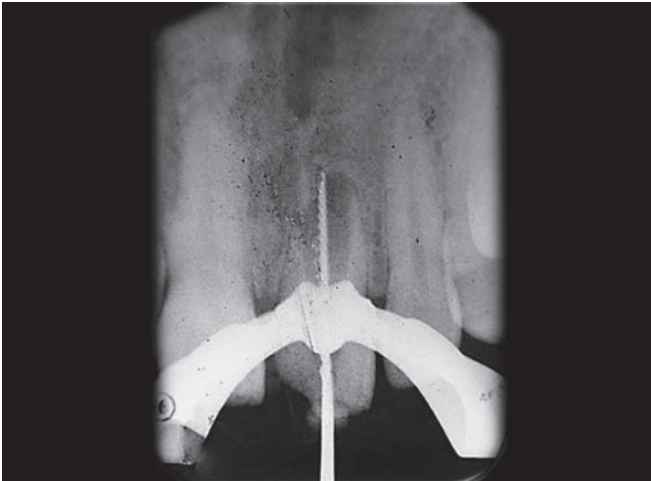

Fig. 4: Working length IOPAR

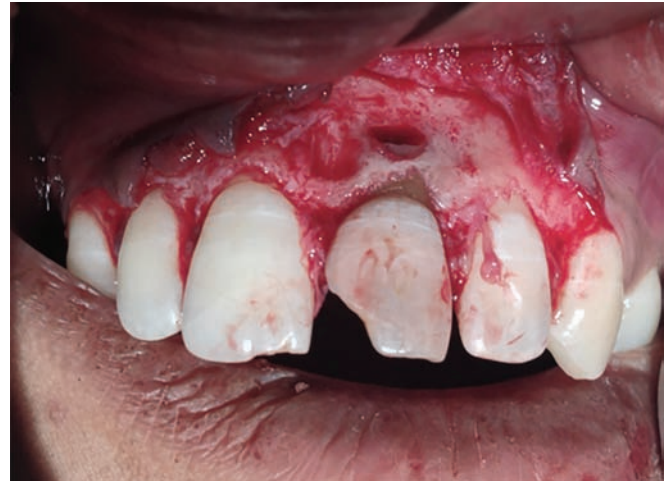
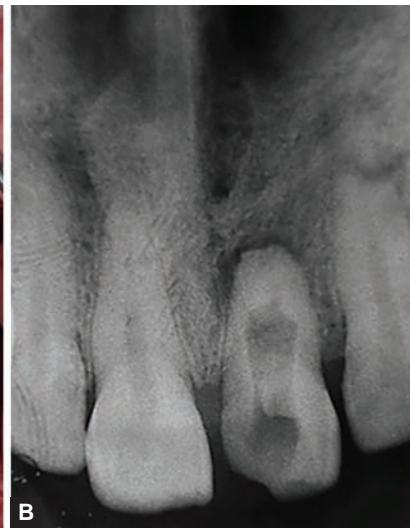
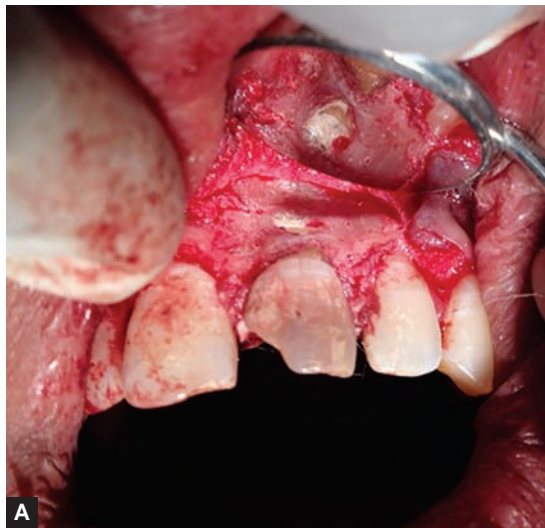Fig. 5: Surgical flap raised



Figs 6A and B: (A) Retrograde filling and (B) post-surgery IOPAR with biodentine

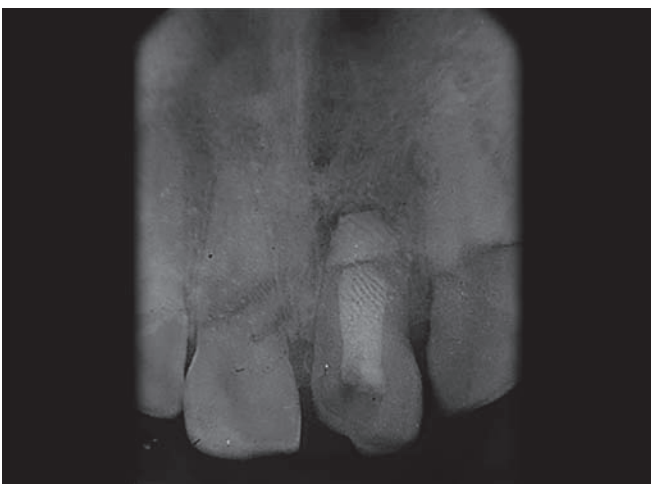


Fig. 7: Postobturation IOPAR

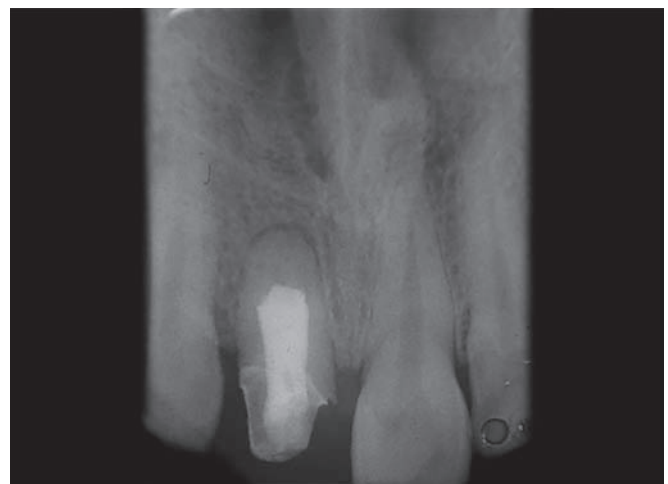

Fig. 8: Follow-up IOPAR (1 year)

from pulp progenitor cells. Biodentine has shown to stimulate dentin regeneration as reported by About et al.¹⁴ As reported by Han and Okiji, calcium and silicon uptake by adjacent root canal dentin in the presence of phosphate buffered saline was greater for Biodentine

than MTA¹⁵ Biodentine has been shown to exhibited the least microleakage when compared to glass ionomer cement and MTA.¹⁶ Biodentine has ability to release calcium ions and presented alkaline pH as reported by Sulthan et al.¹⁷ The 24 hours push out strength of Biodentine was

found to greater than MTA.¹⁸ This case report emphasizes on the importance of CBCT in diagnosis and treatment of cases of open apices of tooth through surgical approach using Biodentine.

SUMMARY

Cone beam computed tomography was found to be useful for the diagnosis, management and postoperative evaluation of a case involving a permanent anterior tooth with open apex. The Biodentine was found to be an excellent material for endodontic treatment in such a case resulting in successful treatment outcome, both clinically and radiographically.

REFERENCES

1. Felipe WT, Felipe MC, Rocha MJ. The effect of mineral trioxide aggregate on the apexification and periapical healing of teeth with incomplete root formation. *Int Endod J* 2006; 39(1):2-9.
2. Coomaraswamy KS, Lumley PJ, Hofmann MP. Effect of bis-muth oxide radiopacifier content on the material properties of an endodontic portland cement-based (MTA-like) system. *J Endod* 2007;33(3):295-298.
3. Giuliani V, Baccetti T, Pace R, Pagavino G. The use of MTA in teeth with necrotic pulps and open apices. *Dent Traumatol* 2002;18(4):217-221.
4. Parirokh M, Torabinejad M. Mineral trioxide aggregate: a comprehensive literature review—part III: clinical applications, drawbacks and mechanism of action. *J Endod* 2010; 36(3):400-413.
5. Saidon J, He J, Zhu Q, Safavi K, Spångberg LS. Cell and tissue reactions to mineral trioxide aggregate and portland cement. *Oral Surg Oral Med Oral Pathol Oral Radiol Endod* 2003; 95(4):483-489.
6. Laurent P, Camps J, De Méo M, Déjou J, About I. Induction of specific cell responses to a Ca₃SiO₅ based posterior restorative material. *Dent Mater* 2008;24(11):1486-1494.
7. Wang X, Sun H, Chang J. Characterization of Ca₃SiO₅/CaCl₂ composite cement for dental application. *Dent Mater* 2008; 24(1):74-82.
8. Wongkornchaowalit N, Lertchirakarn V. Setting time and flowability of accelerated portland cement mixed with poly-carboxylate superplasticizer. *J Endod* 2011;37(3):387-389.
9. Komabayashi T, Spångberg LS. Comparative analysis of the particle size and shape of commercially available mineral trioxide aggregates and Portland cement: a study with a flow particle image analyzer. *J Endod* 2008;34(1):94-98.
10. Trope M. Treatment of immature teeth with non-vital pulps and apical periodontitis. *Endotopic* 2007;14(1):51-59.
11. Abraham D, Bahuguna N, Manan R. Use of CBCT in the successful management of endodontic cases. *J Clin Imag Sci* 2012;2:50.
12. Ball RL, Barbizam JV, Cohenca N. Intraoperative endodontic applications of cone-beam computed tomography. *J Endod* 2013;39(4):548-557.
13. Hasheminia SM, Norozynasab S, Fezianfard M. The effect of three different calcium hydroxide combinations on root dentin microhardness. *Res J Biol Sci* 2009;4(1):121-125.
14. About I, Laurent P, Tecles O. Bioactivity of Biodentine™ a Ca₃SiO₅-based dentine substitute. Oral Session. IADR Congress July, 2010, Barcelona, Spain.
15. Han L, Okiji T. Uptake of calcium and silicon released from calcium silicate-based endodontic materials into root canal dentine. *Int Endod J* 2011;44(12):1081-1087.
16. Kokate SR, Pawar AM. An in vitro comparative stereomicroscopic evaluation of marginal seal between MTA, Glass Inomer Cement and Biodentine as root end filling materials using 1% methylene blue as tracer. *Endod* 2012;2:36-42.
17. Sulthan IR, Ramchandran A, Deepalakshmi A, Kumarapan SK. Evaluation of pH and calcium ion release of mineral trioxide aggregate and a new root-end filling material. *E J Dent* 2012; 2(2):166-169.
18. Aggarwal V, Singla M, Miglani S, Kohli S. Comparative evaluation of push-out bond strength of ProRoot MTA, Biodentine, and MTA Plus in furcation perforation repair. *J Conserv Dent* 2013;16(5):462-465.