

## CASE REPORT

# Gingival Melanin Depigmentation: A Review and Case Report

<sup>1</sup>Sumedha Srivastava, <sup>2</sup>Trilok Shrivastava, <sup>3</sup>Shivani Dwivedi, <sup>4</sup>Pramod Yadav

## ABSTRACT

The color of the gingiva has a tremendous impact on the esthetics of the smile. Clinically gingival melanin hyper pigmentation is presented as 'black gum' which is a common esthetic problem especially for those who have gummy smile. Several attempts have been made for removal of gingival pigmentation by different techniques. Each technique had its own supremacy in efficiency and also draw back. In the present cases, an effort has been made to assess the procedure of melanin depigmentation using surgical scalpel technique.

**Keywords:** Melanin, Depigmentation, Gingiva, Melanocytes.

**How to cite this article:** Srivastava S, Shrivastava T, Dwivedi S, Yadav P. Gingival Melanin Depigmentation: A Review and Case Report. *J Orofac Res* 2014;4(1):50-54.

**Source of support:** Nil

**Conflict of interest:** None declared

## INTRODUCTION

Gingival health and appearance are the essential components of an attractive smile. Gingiva is the most frequently pigmented intraoral tissue and common esthetic concerns which require patients to seek cosmetic treatment for their unsightly pigmented gingiva. There are several factors responsible for the color of gingiva, namely number and size of the blood vessels, epithelial thickness, quantity of keratinization and pigments within the gingival epithelium. According to Dummett,<sup>1</sup> color of the healthy gingiva is variable, ranging from pale pink to deep bluish purple. Melanin, carotene,

reduced hemoglobin and oxyhemoglobin are the main pigments contributing to the normal color of the oral mucosa.<sup>2</sup>

Oral melanin pigmentation is considered to be multifactorial which could be either physiological or pathological apart from this gingival hyperpigmentation is seen as a genetic trait in some populations and is more appropriately termed physiologic or racial gingival pigmentation. Infections, trauma, drugs, hormone deficiency, and some systemic factors, such as Addison's disease, also can cause gingival pigmentation.<sup>3,4</sup> Among the various types of pigments, melanin is the most common pigment contributing to the normal color of the gingiva. Several studies have been done on melanin pigment as it is the most important pigment of the skin. Melanin hyperpigmentation of gingival usually does not present as a medical problem, but many patients may consider their black gums to be unesthetic. This problem is more embarrassing in patients with 'gummy smile.' Clinically, in the facial aspect of the gingiva, gingival melanin hyperpigmentation appear as light to dark brown and sometimes blue black area. Attached gingiva is the most common site. The color is often a diffuse, symmetric, ribbon like dark band or irregularly shaped patch with a well-demarcated border.<sup>5</sup>

According to Dummett: Gupta Oral Pigmentation Index (DOPI) : (1964)<sup>6</sup>

- 0 —no clinical pigmentation (pink gingiva).
- 1 —mild clinical pigmentation (mild light brown color).
- 2 —moderate clinical pigmentation (medium brown or mixed pink and brown color).
- 3 —heavy clinical pigmentation (deep brown or bluish black color).

Melanin synthesis occurs only in the cytoplasm of melanocytes, the melanin-forming cells, present at the epidermal-dermal junction of the skin and the mucous membranes. Chemically, melanin granule is round and approximately 0.3 microns in diameter with molecular weight of 20,000.<sup>7</sup> Histologically and microscopically, melanocyte is dendritic cell located in the basal and suprabasal cell layers of the epithelium. The cell of melanocyte, revealed well developed Golgi complex, extensive area of rough endoplasmic reticulum and melanin pigment.<sup>8</sup> A reciprocal relationship was found between gingival pigmentation and skin. Fair-skinned individuals are very likely to have nonpigmented gingiva, but, in darker skinned persons, the chance of having pigmen-

<sup>1-4</sup>Senior Lecturer

<sup>1,3</sup>Department of Periodontology, People's College of Dental Sciences and Research Centre, Bhopal, Madhya Pradesh India

<sup>2</sup>Department of Orthodontics, People's Dental Academy Bhopal, Madhya Pradesh, India

<sup>4</sup>Department of Community Dentistry, KD Dental College Mathura, Uttar Pradesh, India

**Corresponding Author:** Sumedha Srivastava, Senior Lecturer, Department of Periodontology, People's College of Dental Sciences and Research Centre, People's Dental Academy Campus, Aashiyana Building, MIG-8, Bhanpur Road, Bhopal-462037, Madhya Pradesh, India, Phone: 09589478706, e-mail: [drsumi0109@gmail.com](mailto:drsumi0109@gmail.com)

ted gingiva is extremely high.<sup>1</sup> Various treatment modalities have been made for cosmetic removal of pigmented area with unpredictable results. These include gingivectomy<sup>8</sup> gingivectomy with free gingival autografting,<sup>9</sup> abrasion with diamond burs,<sup>10</sup> acellular dermal matrix allografts<sup>11</sup> cryosurgery,<sup>12</sup> electrosurgery<sup>13</sup> and various types of lasers<sup>14</sup> Each technique had its own supremacy in efficiency and also draw back. Demand for cosmetic therapy is mostly seen in patients with a high smile line, i.e. gummy smile. Gingival depigmentation is one of a periodontal plastic surgical procedure through which the gingival hyperpigmentation is removed or reduced by various techniques. This article describes two cases of depigmentation technique using scalpel technique.

## CASE REPORTS

### Case 1

A 21 years old male patient with a wheatish complexion but heavily pigmented dark gums reported with a chief complain of black gums which esthetically interfered his smile and speech. Patients was young and esthetically conscious. On clinical examination a healthy periodontium was seen with gingival melanin hyper pigmentation on the maxillary arch which was moderately diffused on broad area of the entire anterior labial attached gingival (Fig. 1A). On mandibular arch, the pigment was not that densely gathered as brown continuous band and the smile of the patient was not affected

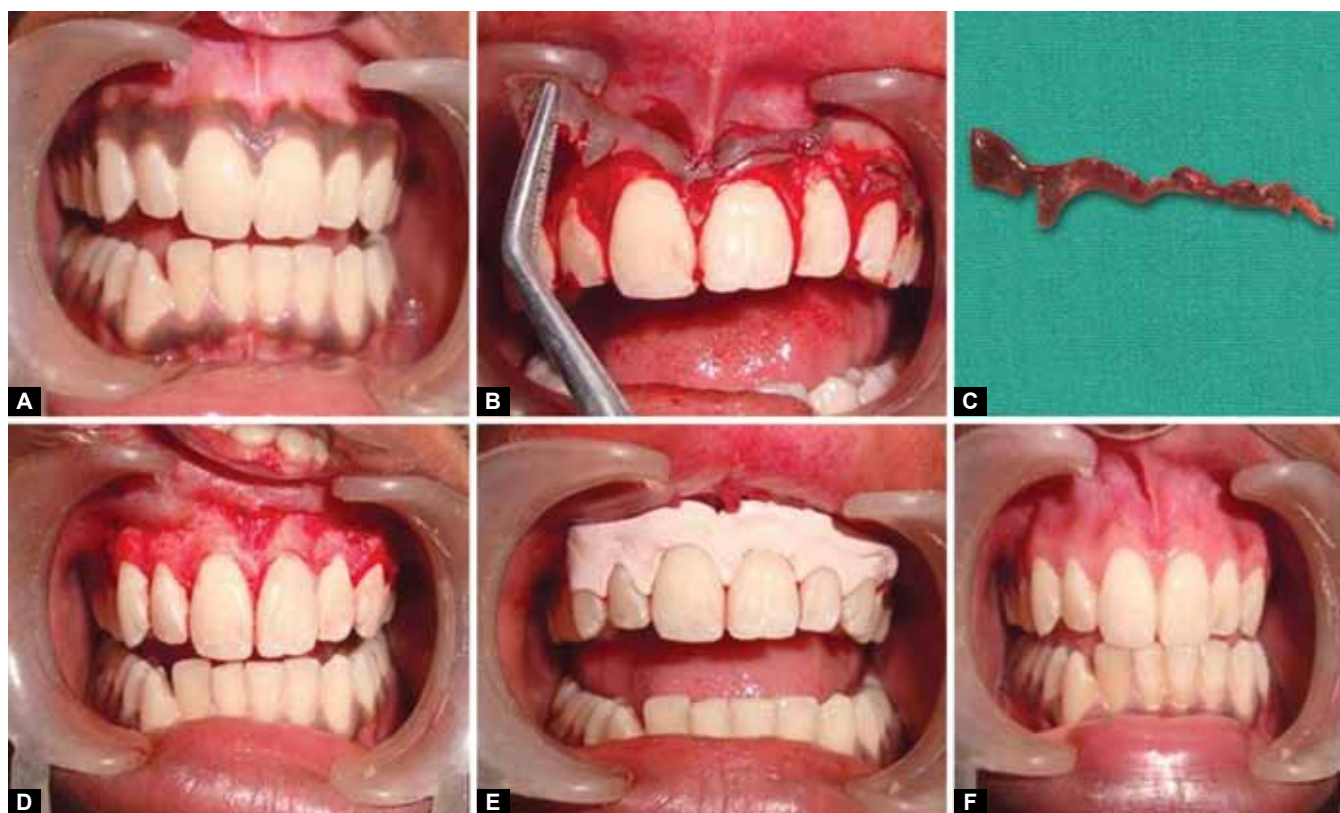
by this, so the decision for depigmentation was taken with scalpel technique only on maxillary arch.

### Case 2

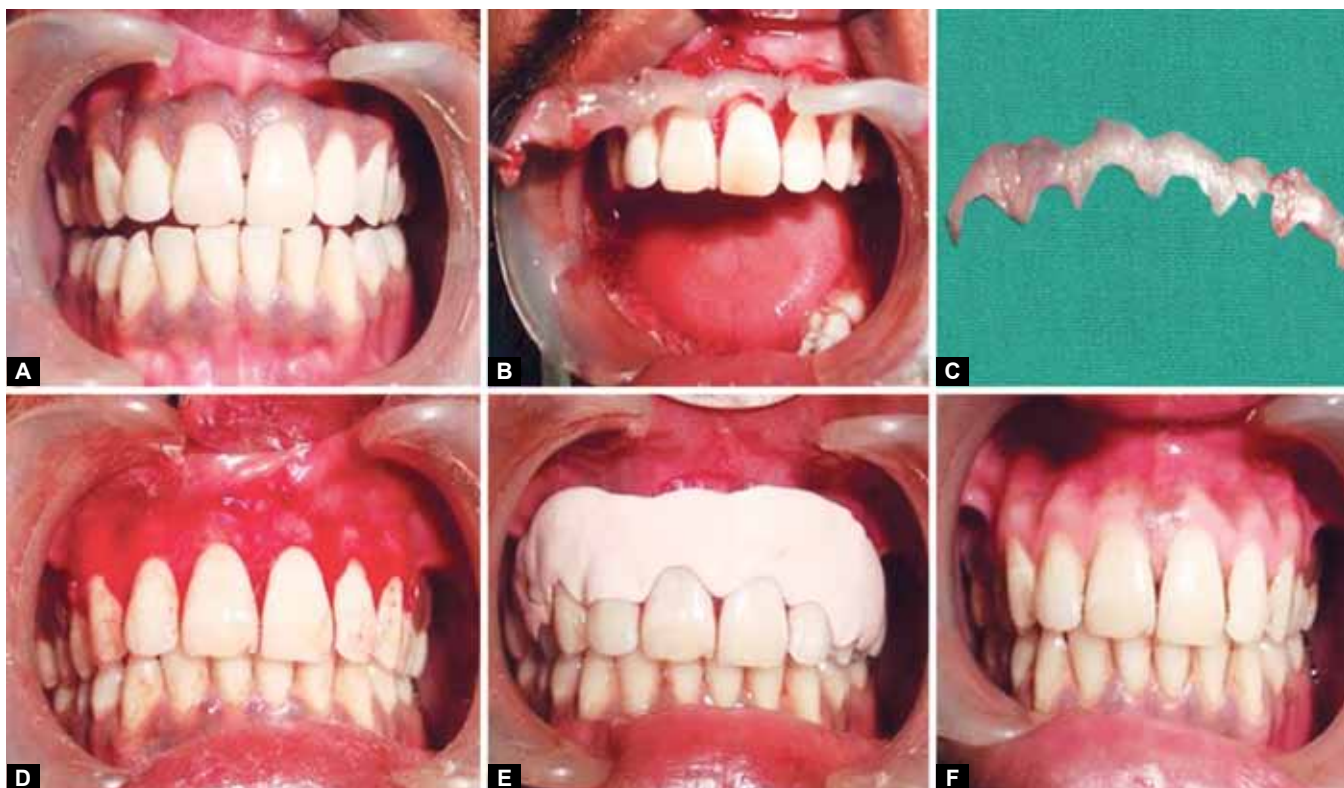A male patient with fair skin of 25 years of age reported with the chief complain of dark and black gums. He requested for any cosmetic therapy through which his smile and esthetics can be enhanced. Patients was medically sound (Fig. 2A). Clinical examination of this case also showed the healthy periodontium but heavily pigmented gingiva with a continuous band of dark color on the maxillary labial arch however, the mandibular gingival pigmentation was still not obvious during smile, so decision for depigmentation was carried out only in maxillary arch.

### Surgical Technique

Prior to surgery a complete medical history and investigations for blood were carried out to rule out any systemic contraindications for the surgery. Considering the patient's concern, surgical depigmentation procedure was planned. The entire procedure was explained to the patient and written consent was obtained. Routine oral hygiene procedures were carried out and oral hygiene instructions were given. A presurgical rinse with chlorhexidine was done in order to maintain asepsis during entire surgical procedure. Local anesthesia 2% lignocaine containing adrenaline at a concentration of 1:80,000



**Figs 1A to F:** Case 1: (A) Preoperative, (B) epithelium removed by scalpel technique, (C) removed epithelium, (D) raw area after de-epithelization, (E) periodontal dressing given and (F) postoperative after 1 year



**Figs 2A to F:** Case 2: (A) Preoperative, (B) epithelium removed by scalpel technique, (C) removed epithelium, (D) raw area after de-epithelization, (E) periodontal dressing given and (F) postoperative after 1 year

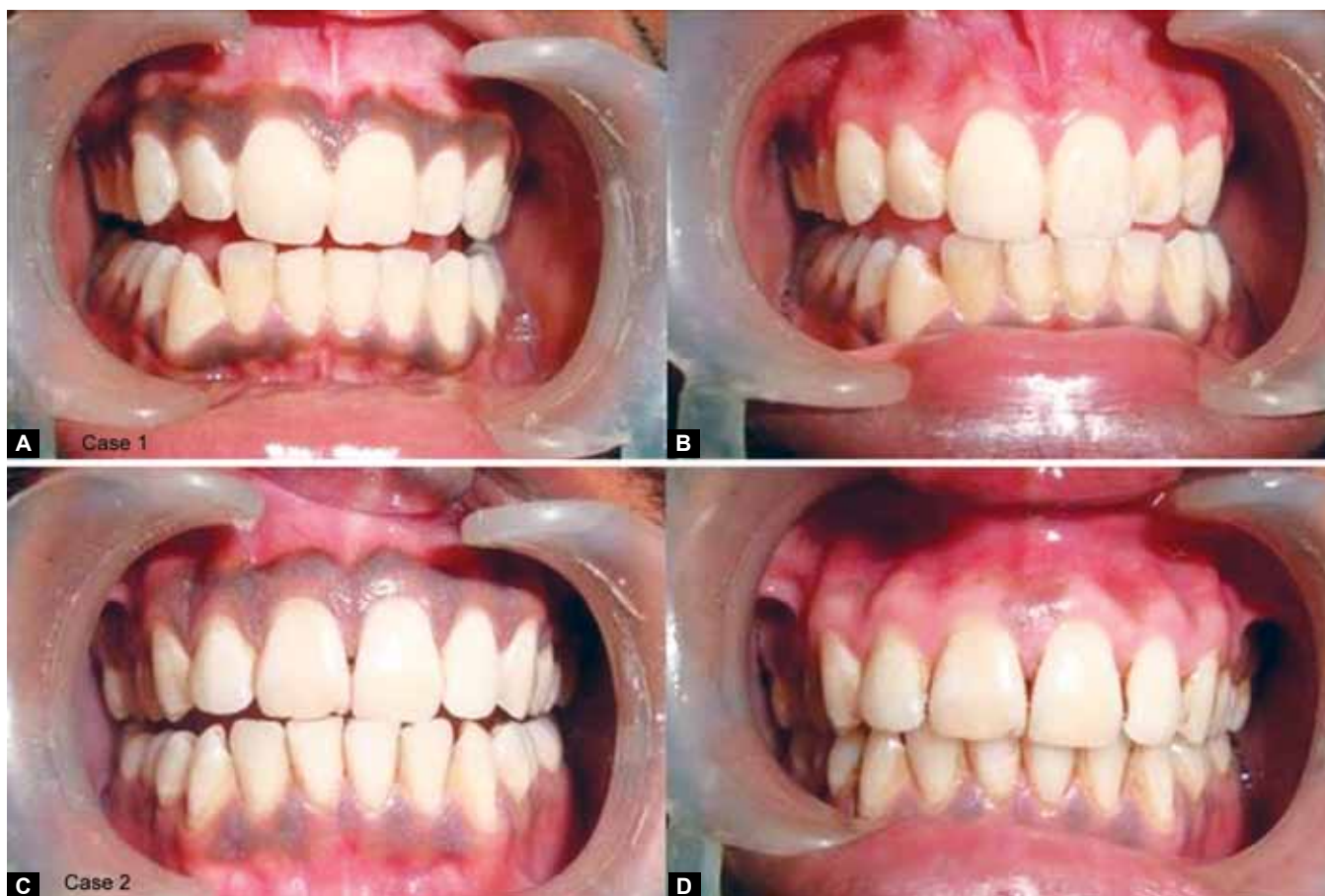was given from premolar to premolar area in maxillary arch. Blade no. 15 with Bard Parker handle was used. The entire pigmented epithelium (Figs 1B and 2B) was removed with the scalpel (Figs 1C and 2C) the bleeding was controlled with the pressure pack (Figs 1D and 2D). A noneugenol periodontal dressing was given (Figs 1E and 2E). Patient was advice antibiotic and analgesic postoperatively for 5 days. The patient was reviewed at the end of 1 week. Healing was uneventful without any postsurgical complication. The gingiva appear pink healthy and firm. The patient expressed satisfaction over the enhanced color of the gingival. At the end of 1 month, reepithelialization was complete. The cases were reevaluated again after 1 year (Figs 1F and 2F).

## DISCUSSION

Melanin pigmentation is frequently seen by melanin deposition through the active melanocytes located mainly in the basal layer of the oral epithelium. Pigmentation can be removed for esthetic reasons. No sign of repigmentation was seen with respect to case no. 1 (Figs 3A and B) however, slight repigmentation was seen in case no. 2 at an interval of one years' postoperatively that too in the form of a small patch between the central incisors (Figs 3C and D).

Repigmentation refers to the clinical reappearance of melanin pigment following a period of clinical depigmentation. The exact mechanism of repigmentation is not known but according to 'migration theory', active melanocytes from

adjacent pigmented tissues migrate to treated area and cause failure.<sup>15</sup> Irrespective of various techniques the problem of repigmentation was seen by many other authors, though there may be considerable variation in there follow-up period. The result of the gingivectomy procedure used by Dummett et al<sup>16</sup> to remove pigmented gingiva showed the repigmentation in 67% of the areas, with in 33 days after surgical removal however in 33% of areas, repigmentation did not occur up to 431 days after surgery. Hirschfeld et al<sup>17</sup> used phenol (90%) and alcohol (95%) and observed repigmentation which was soon developed in three patients; the rest of the subjects met with the same results within a shorter duration of time. Sameer et al<sup>18</sup> treated three cases of gingival hyperpigmentation by abrasion with a high-speed hand piece and diamond bur and reported no repigmentation in a follow-up period of 18 months contrary to this Farnoosh<sup>19</sup> reported slight repigmentation in two cases after a period of 20 months with similar technique. Bergamaschi et al<sup>8</sup> studied melanin repigmentation after gingivectomy and concluded that the gingival resective procedures, offer no permanent results if performed solely for cosmetic reasons. Tal et al.<sup>20</sup> used cryosurgery for the removal of gingival pigmentation and reported no repigmentation up to a 20-month follow-up period. The results of Perlmutter and Tal<sup>15</sup> studies with scalpel technique showed that gingival repigmentation occur after seven years in one patient however in other, treated areas remain depigmented even after 8 years follow-up



**Figs 3A to D:** (A and B) Preoperative and 1 year postoperative of case 1, (C and D) preoperative and 1 year postoperative of case 2

duration. Thus, the mixed results were seen with different techniques. Some were positive while some were negative for repigmentation occurrence.

The various depigmentation techniques with different success rate have been reported in the literature with their own advantages and disadvantages, however the selection of a technique for depigmentation should be based on clinical experience, availability of the resources and affordability of patients. Among all the available technique we have focused on the scalpel technique because of the its economical, less time consuming, faster healing and without the requirement of any special or costly armamentarium. However, sometimes scalpel surgery causes unpleasant bleeding during and after the surgical procedure, to overcome this problem it is always advisable to use periodontal dressing for about 1 week duration in order to cover exposed lamina propria and also to comfort the patient while eating.

Dummett and Bolden<sup>16</sup> et al: used gingivectomy to remove pigmented gingival but found the mixed results regarding repigmentation. A free gingival graft which required additional surgical site has also been used, but color matching and demarcated line around graft itself may pose esthetic problem. Chemical agents like phenol (90%) and alcohol (95%) worked by destroying tissue down to and slightly below the basal layer of the mucous membranes. It

was found that these agents were harmful to oral soft tissue cause pain and tissue necrosis along with the repigmentation which was observed later.<sup>17</sup> It is often difficult to control the depth of deepithelization by using bur abrasion or surgical bur technique. Moreover, there is a possibility of postoperative bleeding and pain.

Electrosurgery requires more expertise than scalpel surgery. The study done by Glickman and Imber in 1970 compared electrosurgery and periodontal knives and concluded that in deep gingival resection, inflammation was intense, and loss of crestal bone height occurred with electrosurgery.<sup>21</sup> When comes to Cryosurgery it requires technical skill, expensive instrument which is not commonly available in the clinics moreover it is also accompanied by increased soft tissue destruction as the depth of penetration cannot be controlled.<sup>22</sup>

Recently laser therapy is also used for the same Atsawa-suwan<sup>23</sup> et al used Nd:YAG laser for the treatment of hyperpigmented gingiva and reported no recurrence in a period of 11 to 13 months of follow-up this could be because of laser beam even destroys the epithelial cells including those at the basal layer, and hence reduces repigmentation. It was also suggested that Nd:YAG laser should be used cautiously. The advantage of using laser beam is that it produces bloodless field for surgery, causes minimum damage to the periosteum

and underlying bone, and the treated gingiva and mucosa do not need any dressing. This has the advantages of easy handling, short treatment time, hemostasis, and decontamination and sterilization effects. But this approach needs expensive and sophisticated equipment, which makes the treatment very expensive so this technique is not widely accepted or popularly used at present.

## CONCLUSION

The gingival tissues play an important role in healthy and beautiful smile. Hyper pigmentation of gingiva is a common esthetic but not a medical problem. The surgical procedure described here for depigmentation was found to be simple, still popular, economical and clinically satisfactory with least discomfort and minimal tissue removal of the patients. In the present cases the patients have reported feeling better about their appearance, with complete satisfaction especially during smiling and speech.

## REFERENCES

- Dummett CO, Barends G. Pigmentation of the oral tissue: a review of the literature. *J Periodontol* 1967;38:369-377.
- Tal H, Oegiesser D, Tal M. Gingival depigmentation by Erbium: YAG laser: clinical observations and patients responses. *J Periodontol* 2003;74:1660-1667.
- Dummett CO. Oral tissue color changes. *Ala J Med Sci* 1979; 16:274-283.
- Dummett CO. Overview of normal oral pigmentations. *Ala J Med Sci* 1979;16:262-273.
- Krom JC, Waas AM, Oosterveld P, et al. The oral pigmentation chart: a clinical adjunct for oral pigmentation in removable prostheses. *Int J Prosthodont* 2005;18:66-70.
- Dummett CO, Gupta OP. Estimating the epidemiology of the oral pigmentation. *J Natl Med Assoc* 1964;56:419-420.
- Bolden TE. Histology of Oral Pigmentation. In first symposium on oral pigmentation, Dummett CO, consulting editor. *J Periodontol* 1960;31:361-374.
- Bergamaschi O, Kon S, Doine AI, et al. Melanin repigmentation after gingivectomy: a 5-year clinical and transmission electron microscopic study in humans. *Int J Periodontics Restorative Dent* 1993;13(1):85-92.
- Tamizi M, Taheri M. Treatment of severe physiologic gingival pigmentation with free gingival autograft. *Quintessence Int* 1996;27:555-558.
- Bishop K. Treatment of unsightly oral pigmentation: a case report. *Dent Update* 1994;21:236-237.
- Pontes AE, Pontes CC, Souza SL, Novaes AB Jr, Grisi MF, Taba M Jr. Evaluation of the efficacy of the acellular dermal matrix allograft with partial thickness flap in elimination of the gingival melanin pigmentation—a comparative clinical study with 12 months of follow-up. *J Esthetic Rest Dent* 2006;18:135-143.
- Yeh CJ. Cryosurgical management of melanin pigmented gingival. *Oral Surg Oral Med Oral Pathol Oral Rad Endod* 1998;86:660-663.
- Gnanasekhar JD, Saleh Al-Duwairi Y. Electrosurgery in dentistry. *Quintessence Int* 2001;1:34-39.
- Stabholz A, Zeltser R, Sela M, Peretz B, Moshonov J, Ziskind D, et al. The use of lasers in dentistry: principles of operation and clinical applications. *Compend Contin Educ Dent* 2003;24:935-948.
- Perlmutter S, Tal H. Repigmentation of the gingiva following injury. *J Periodontol* 1986;57:48-50.
- Dummett CO, Bolden TE. Postsurgical clinical repigmentation of the gingiva. *Oral Surg Oral Med Oral Pathol* 1963;16:353-365.
- Hirschfeld I, Hirschfeld L. Oral pigmentation and method of removing it. *Oral Surg Oral Med Oral Pathol* 1951;4:1012-1016.
- Mokeem SA. Management of gingival hyperpigmentation by surgical abrasion: Report of 3 cases. *Saudi Dental Journal* 2006;18:161-166.
- Farnoosh AA. Treatment of gingival pigmentation and discoloration for esthetic purposes. *Int J Periodont Rest Dent* 1990;10:313-318.
- Tal H, Landsberg J, Kozlovsky A. Cryosurgical depigmentation of the gingival. A case report. *J Clin Periodontol* 1987;14: 614-617.
- Glickman I, Imber I. Comparison of gingival resection with electrosurgery and periodontal knives: a biometric and histologic study. *J Periodontol* 1970;41:142-148.
- Ishida CE, Ramose SM. Cryosurgery in oral lesions. *Int J Dermatol* 1998;37:283-285.
- Atsawasuwan P, Greethong K, Nimmanon V. Treatment of gingival hyperpigmentation for esthetic purposes by Nd: YAG laser: Report of 4 cases. *J Periodontol* 2000;71:315-321.