

CASE REPORT

An Upper Lip Swelling: A Case Report, Differential Diagnosis and Review of Literature

Preeti Tomar Bhattacharya, Sumona Pal, Rupam Sinha, Mayukh Misra, Arka Bhattacharya

ABSTRACT

Pleomorphic adenoma is the most common tumor of the salivary glands. About 90% of these tumors occur in the parotid gland and 10% in the minor salivary glands. The most common site for pleomorphic adenoma of the minor salivary glands is the palate followed by upper lip. Surgical removal with adequate margins is the principal treatment. Due to its microscopic projections, this tumor requires a wide resection to avoid recurrence. We report a case of pleomorphic adenoma in the upper lip of an elderly female with emphasis on differential diagnosis and relevant review of literature.

Keywords: Pleomorphic adenoma, Salivary glands, Neoplasm, Salivary gland anlage tumor.

How to cite this article: Bhattacharya PT, Pal S, Sinha R, Misra M, Bhattacharya A. An Upper Lip Swelling: A Case Report, Differential Diagnosis and Review of Literature. *J Orofac Res* 2013;3(2):136-139.

Source of support: Nil

Conflict of interest: None declared

INTRODUCTION

About 3 to 10% of the neoplasms of the head and neck region constitute pleomorphic adenomas.¹ Pleomorphic adenoma shows female predilection in fourth to sixth decade of life and generally involves major salivary glands and less commonly minor salivary glands. The palate is most common site followed by upper lip which comprises about 20 to 40% of all intraoral cases.^{2,3} The other reported intraoral locations of pleomorphic adenoma are buccal mucosa, floor of mouth, tongue, tonsil, pharynx, retromolar area and nasal cavity.⁴⁻⁶

Cytogenetic and molecular studies have reported that it is of epithelial origin with chromosomal abnormalities at 8q12 and 12q25.⁷ The most typical presentation of pleomorphic adenoma is a slowly growing, painless, well defined, firm mobile swelling with no secondary changes. Pleomorphic adenoma as the name suggests shows highly variable morphology and consists of epithelial and mesenchymal cells. It is broadly accepted that both epithelial and mesenchymal elements arise from same cell clone and the tumor do not show any difference in behavior based on proportion of various elements.⁸ This paper intends to report a relatively rare lesion in an elderly female with differential diagnosis and brief review of literature.

CASE REPORT

A 70-year-old female patient reported to the Department of Oral Medicine and Radiology with complaint of a swelling in the upper lip since 3 years which was increasingly causing discomfort to her. The patient had undergone extraction of upper teeth due to mobility 10 years back. There was no history of trauma to the region of complaint. The swelling was gradual in onset and constantly increasing in size. The patient did not notice any pain, discharge or paresthesia in the region of complaint at any point of time. There was reportedly increased discomfort in speech and chewing. Her medical, dental and family histories were noncontributory. The patient's general physical examination did not reveal any abnormality. There was no regional lymphadenopathy. The extraoral examination revealed facial asymmetry due to a diffuse swelling of upper lip predominantly on right side (Fig. 1). On local intraoral examination a solitary well defined roughly oval slightly lobulated swelling measuring 4 × 3 cm was noted in the upper lip extending 0.6 cm from labial frenum on left side to 3.5 cm from labial frenum on right side anteroposteriorly and from the depth of vestibule till vermilion border superoinferiorly. The swelling was pinkish in color with few areas showing bluish tinge, had smooth surface with no areas of ulceration or any discharge and showed superficial vascularity. The surrounding mucosa appeared normal. On palpation it was nontender, soft to firm in consistency and not fixed to the underlying structures. The lesion did not cause any resorption of labial cortical plate (Fig. 2).

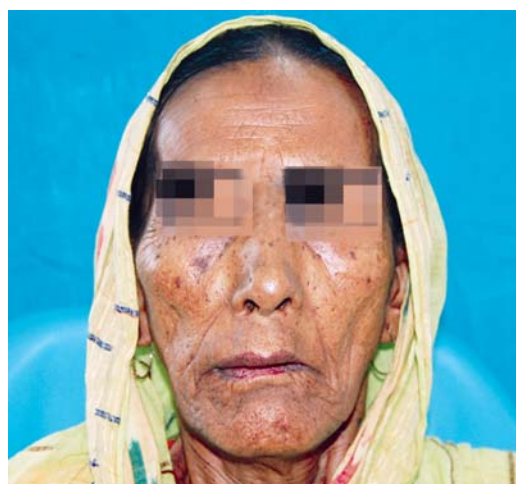

Fig. 1: Extraoral photograph

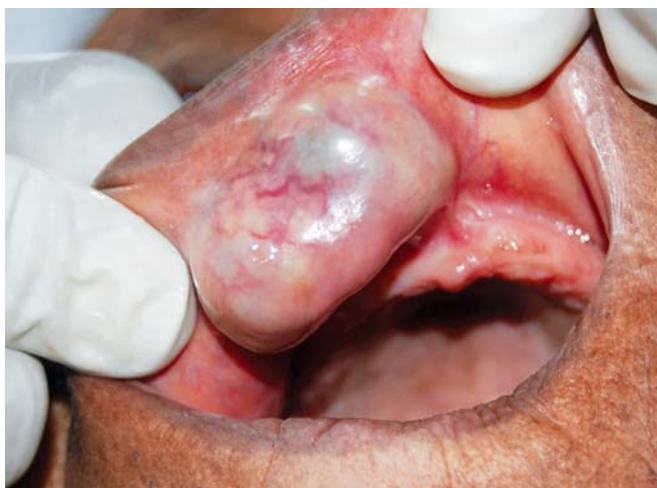

Fig. 2: Intraoral view

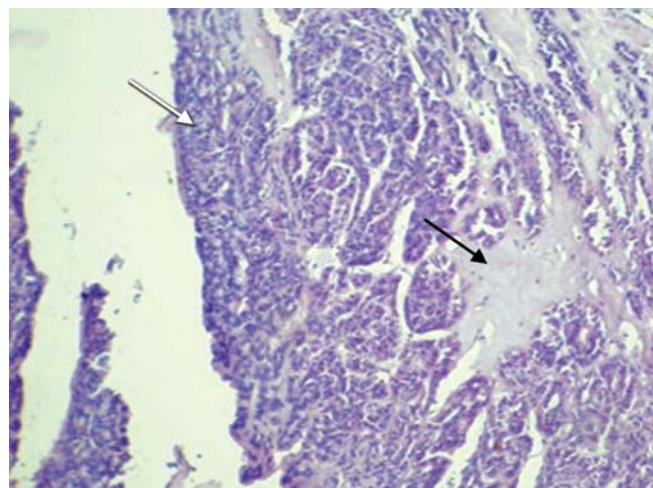


Fig. 4: Photomicrograph showing ductal cells and hyaline material

A provisional diagnosis of pleomorphic adenoma was made. Blood investigation did not reveal any abnormality. Owing to the lesion being very well defined excisional biopsy was planned under local anesthesia. An elliptical incision was made around the tumor keeping a margin of 1 cm all around the lesion. This was done to maintain the contour of lip. With the help of electrocautery the lesion was excised *in toto*. Labial artery was ligated. Hemostasis was achieved and suturing was done maintaining the contour and continuity of lip (Fig. 3).

The patient's recovery was uneventful and is currently under follow-up.

The histopathological examination revealed an encapsulated tumor mass showing sheets and strands of small, cuboidal darkly staining ductal epithelium. At places cells were arranged in double layer surrounding cystic spaces with small, darker myoepithelial cells as distinct outer layer. The central spaces contained eosinophilic mucoid material. The fibrocollagenous stromal tissue showed deposition of hyaline material (Fig. 4). Thus, the provisional diagnosis was confirmed.

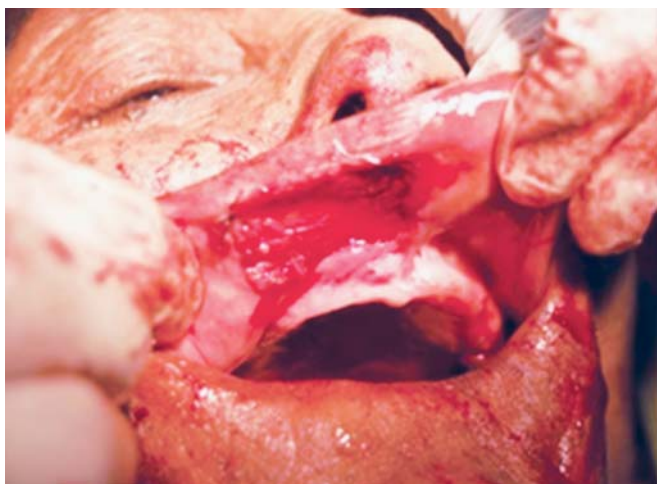

Fig. 3: Immediate postoperative view

DISCUSSION

Pleomorphic adenoma has been known with different names over years such as mixed tumor, enclavoma, branchioma, endothelioma and enchondroma. The tumor was named by Willis characterizing the unusual histologic pattern of the lesion. Lee et al examined pleomorphic adenomas in 13 female subjects. They used the HUMARA assay which is a polymerase chain reaction. It is possible to study the clonality of tissues by examining the methylation pattern of CAG repeats in HUMARA assay. A monoclonal pattern was observed in the stromal and epithelial elements in majority of the cases. These findings advocate monoclonal origin of both stromal and epithelial cells in pleomorphic adenoma of salivary gland.⁸ Variants of pleomorphic adenoma comprise pleomorphic adenoma with lipomatous change,⁹ myxoliopmatous pleomorphic adenoma, pleomorphic adenoma with squamous differentiation and benign metastasizing mixed tumor.¹⁰

According to Bernier the average age of 33.2 years was noted in pleomorphic adenoma of the lips with peak incidence in the third and fourth decades.¹¹ The female predilection was seen in our case also but the average age was much higher in the presented case.

Pleomorphic adenoma usually manifest as a slow growing, nontender, firm mobile swelling rarely with any evidence of secondary changes. When close under mucosa they exhibit a bluish tinge. Similar clinical manifestations were apparent in the current case. The pleomorphic adenomas of palate are fixed and some might show rapid growth. Kroll and Hick reported that 16.9% of pleomorphic adenoma arose in the upper lip and 2.9% in the lower lip.¹² There is a noted tendency for benign tumors to arise in upper lip and malignant in lower lip. The reason thought to be is the difference in the embryonic development of the lips.¹³

The differential diagnosis of a well defined submucosal swelling in the upper lip should be arrived based on the anatomic structures present in that location. So the possible sources of development of this swelling can be from minor salivary glands, muscles, adipose tissue, fibrous tissue, neural, vascular and extranodal lymphoid tissue.

On clinical examination, slow growth and well defined nature of the submucosal swelling were thought to represent a benign noninflammatory process. In the upper lip, the two most common salivary gland tumors are the pleomorphic adenoma and the canalicular adenoma. Both typically present as painless, slow growing, firm, freely movable masses. Sometimes, these lesions can appear fluctuant if there is a prominent cystic component. Pleomorphic adenoma can occur at any age. Canalicular adenoma shows a striking predilection for the upper lip, with more than 75% occurring in this one location. They nearly always occur in older adults, with a peak prevalence in the seventh decade of life. Owing to rarity of occurrence of canalicular adenoma, provisional diagnosis of pleomorphic adenoma was considered in this case. Other benign minor salivary gland tumors that should also be considered are basal cell adenoma, oxyphilic adenoma and Warthin's tumor. Since, the lesion was long standing and keeping in mind chances of recent malignant transformation low grade malignant tumors of minor salivary glands which must be given consideration are carcinoma ex-pleomorphic adenoma, mucoepidermoid carcinoma, acinic cell carcinoma, adenoid cystic carcinoma, polymorphous low grade adenocarcinoma and salivary adenocarcinoma not otherwise specified. Benign mesenchymal tumors which should be included under differential diagnosis are fibroma (fibrous tissue origin), fibrolipoma (adipose fibrous tissue origin), neurofibroma/schwannoma (neural tissue origin), and rhabdomyoma (skeletal muscle origin). Rarities such as foreign body granuloma, myofibroma, solitary fibrous tumor and nonaggressive extranodal non-Hodgkin's lymphoma are other possibilities.

Fibroma present as a well defined pedunculated or sessile nodule ranging from few millimeters to several centimeters in dimension but usually less than 1.5 cm and can occur in any age. Both schwannoma and neurofibroma present as slow growing submucosal masses which can attain large sizes but both lesions show younger age predilection. Adult rhabdomyomas of the head and neck occur largely in middle-aged and older patients but majority show male predominance. Oral cavity is one of the most frequent sites for this tumor. The tumor appears as a nodule or submucosal mass that can grow to many centimeters. Fibrolipoma is characterized by a significant fibrous component intermixed with the lobules of fat cells. Solitary fibrous tumor is a

benign proliferation of spindle cells. This lesion was initially described as a tumor of the pleura and has also been illustrated in different intraoral locations. Oral lesions are observed in adults and present as submucosal masses largely in the buccal mucosa. The indolent type of non-Hodgkin lymphoma can present as a nodule with a history of long duration.^{14,15} In cases with red-purplish color dominance, vascular tumors should also be considered in differential diagnosis.

Histopathologically, pleomorphic adenoma is characterized by a variety of tissues consisting of epithelial cells, arranged in a variety of patterns like islands, ribbons, sheets, or ductal, together with areas of squamous differentiation or with plasmacytoid appearance. Myoepithelial cells produce of chondroid, collagenous, mucoid and osseous stroma. Generally, the minor salivary gland tumors are more cellular than those of the major glands. Histologic features suggestive of malignant transformation include extensive hyalinization, cellular atypism, necrosis, calcification and invasion.¹⁶

Myoepithelial cells in pleomorphic adenomas are immunoreactive for keratin, S-100 protein, glial fibrillary acidic protein, actin and vimentin.

A lesion referred to as salivary gland anlage tumor (SGAT) shows considerable histological resemblance to pleomorphic adenoma. The epithelial and mesenchymal components of SGAT are structurally similar to myoepithelium. The epithelial cells express a broad spectrum of keratins and epithelial membrane antigens while the stromal cells express vimentin and smooth muscle actin similar to pleomorphic adenoma. Though SGAT is believed to be a hamartomatous proliferation rather than a neoplasm and manifest mostly within 2 weeks of life. Hence it is also referred to as congenital pleomorphic adenoma.¹⁷

Minor salivary gland tumors are managed by total excision that includes a 1 cm rim of the surrounding issue. The pleomorphic adenomas of minor salivary gland are partially encapsulated. The prognosis will be excellent if resection is adequate. Thus, recurrence may be noted secondary to incomplete excision of the tumor.

Malignant degeneration is the potential complication resulting in carcinoma ex pleomorphic adenoma, adenocarcinoma or undifferentiated carcinoma. The risk of malignant transformation increases with the duration of the tumor and mean age of the patient. Regular follow-up is indicated to detect local recurrence and malignant transformation.

REFERENCES

1. Garcia Berrocal JR, Ramirez Camacho R, Trinidad A, Salas C. Mixed tumor (pleomorphic adenoma) of head and neck. Typical

- and atypical patterns. *An Otorrinolaringol Ibero Am* 2000; 27:333-40.
2. Chaudhry AP, Vickers RA, Gorlin RJ. Intraoral minor salivary gland tumors: An analysis of 1414 cases. *Oral Surg* 1961;14: 1194-226.
 3. Eveson JW, Cawson RA. Tumors of the minor (oropharyngeal) salivary glands: A demographic study of 336 cases. *J Oral Pathol* 1985;14:500-03.
 4. Spiro RH. Salivary neoplasms: Overview of a 35-year experience with 2,807 patients. *Head Neck Surg* 1986;8:177-84.
 5. Waldron CA, el-Mofty SK, Gnepp DR. Tumours of the intraoral minor salivary glands: A demographic and histologic study of 426 cases. *Oral Surg Oral Med Oral Pathol* 1988;66:323-33.
 6. Cohen MA. Pleomorphic adenoma of the cheek. *Int J Oral Maxillofac Surg* 1986;15:777-79.
 7. Farina A, Pelucchi S, Grandi E, Carinci F. Histological subtypes of pleomorphic adenoma and age frequency distribution. *Br J Oral Maxillofac Surg* 1999;37:154-55.
 8. Lee PS, Sabbath-Solitare M, Redondo TC, Ongcapin EH. Molecular evidence that the stromal and epithelial cells in pleomorphic adenomas of salivary gland arise from the same origin: Clonal analysis using human androgen receptor gene (HUMARA) assay. *Hum Pathol* 2000;31:498-503.
 9. Kondo T. A case of lipomatous pleomorphic adenoma in the parotid gland. *Diagn Pathol* 2009;4:16.
 10. Ide F, Kusama K. Myxolipomatous pleomorphic adenoma: An unusual oral presentation. *J Oral Pathol Med* 2004;33:53-55.
 11. Bernier JL. Mixed tumors of lips. *J Oral Surg* 1946;4:193-202.
 12. Krolls SO, Hicks JL. Mixed tumors of the lower lip. *Oral Surg* 1973;35:212.
 13. Shrestha A, Reddy NS, Ganguly SN. Pleomorphic adenoma of upper lip: A case report. *Nepal Med Coll J* 2010;6:51-53.
 14. Neville BW, Damm DD, Allen CM, Bouquot JE. Soft tissue tumors. *Oral and maxillofacial pathology* (2nd ed). Philadelphia: WB Saunders Company 2002:438-95.
 15. Regezi JA, Sciubba JJ, Jordan RCK. Lymphoid lesions. *Oral pathology clinical pathologic correlations* (4th ed). St Louis: Saunders 2003:222-32.
 16. Marx RE, Stern D. Salivary gland neoplasms. *Oral maxillofacial pathology: A rationale for diagnosis and treatment* (1st ed). Hong Kong: Quintessence Publishing Co 2003:520-21.
 17. Cohen EG, Yoder M, Thomas RM, Salerno D, Isaacson G. Congenital salivary gland anlage tumor of the nasopharynx. *Pediatrics* 2003;112:e66-69.

ABOUT THE AUTHORS

Preeti Tomar Bhattacharya (Corresponding Author)

Lecturer, Department of Oral Medicine and Radiology, Haldia Institute of Dental Sciences and Research, Haldia, West Bengal, India, e-mail: preeti_kgmu@rediffmail.com

Sumona Pal

Lecturer, Department of Oral Medicine and Radiology, Haldia Institute of Dental Sciences and Research, Haldia, West Bengal, India

Rupam Sinha

Professor, Department of Oral Medicine and Radiology, Haldia Institute of Dental Sciences and Research, Haldia, West Bengal, India

Mayukh Misra

Lecturer, Department of Oral and Maxillofacial Surgery, Haldia Institute of Dental Sciences and Research, Haldia, West Bengal, India

Arka Bhattacharya

Student, Department of Oral Medicine and Radiology, Haldia Institute of Dental Sciences and Research, Haldia, West Bengal, India