

CASE REPORT

Restoring the Esthetics in Hemiparalytic Patient with Detachable Prosthesis

Smriti Kapur Dewan, Monika Sehgal, Aman Arora, Sushant Garg, Sheen Juneja Arora, Neha Seth

ABSTRACT

Emphasis on facial esthetics has become an integral part of dental treatment. Restoring and improving facial appearance of a complete edentulous patient with hollow cheeks is a challenge to the prosthodontist. Thus, to improve patient's lower lip contour that was paralyzed and to improve patient's oral competency, a detachable prosthesis was fabricated. This clinical report describes the procedure for making a lip plumper prosthesis to improve patient esthetics, oral function.

Keywords: Hemiparalysis, Oral competency, Lip plumper, Detachable prosthesis, Ball end clasps.

How to cite this article: Dewan SK, Sehgal M, Arora A, Garg S, Arora SJ, Seth N. Restoring the Esthetics in Hemiparalytic Patient with Detachable Prosthesis. *J Orofac Res* 2013;3(2): 125-127.

Source of support: Nil

Conflict of interest: None declared

INTRODUCTION

Prosthetic rehabilitation of a completely edentulous patient no longer confines to only replacement of missing teeth. Patients are increasingly demanding improvement in esthetics at the end of treatment. Slumped or hollow cheeks can add years to a person's age.¹ However, there are some situations in which patients suffer from deformity of the lip due to damage of the marginal mandibular branch of the facial nerve. Loss of motor innervation to muscles controlling the lower lip leads to paralysis on the affected side of the mouth.² In these situations, patients are treated using therapies that induce the regeneration of nerves, including nerve grafting, adenosine triphosphate drugs, vitamins and acupuncture.³ Recent advances in treatment modalities, including reconstructive surgery, have resulted in improved collaborative rehabilitation efforts between surgical reconstruction and prosthodontic rehabilitation.^{4,5} Few papers focusing on the prosthetic rehabilitation for paralytic lip after a mandibulectomy have been reported in the literature.⁶ This clinical report describes the procedure for making an intraoral lip plumper prosthesis to improve patient's esthetics and oral function. This article has described a simple, effective and noninvasive treatment alternative to improve facial appearance in a completely edentulous patient with hollow cheeks by the use of

detachable plumper prosthesis, using customized attachments.

CASE REPORT

A 60-year-old female reported to the Department of Prosthodontics for replacement of missing teeth. The patient had unilateral facial paralysis, and a history of a gradual, progressive onset of symptoms. Extraoral examination demonstrated that the lower lip was unsupported on the right side with the loss of muscle tone and deepening of the mentolabial sulcus (Fig. 1). Intraoral examination demonstrated complete upper and lower edentulous ridges. No bony spicules were present.

Preliminary impressions were made with irreversible hydrocolloid (Zelgan) (Fig. 2). Custom trays were fabricated and single step border moulding was done using medium body polyether (Aquasil). From the final impressions using light body polyvinyl siloxane definitive casts were prepared (3M ESPE) (Fig. 3). Jaw relations and the anterior teeth arrangement were done in the conventional manner. Cuspless teeth were chosen for the posterior teeth arrangement. At the time of try-in, detachable lip plumper prosthesis was fabricated for restoring the contour of right side of lip. Wax up of the lip plumper was retained on the right buccal surface of the mandibular trial denture with the help of retentive orthodontic ball-end clasps (Fig. 4). Wax-up was adjusted until an adequate lip support was achieved (Fig. 5). Flasking and dewaxing were done, curing of both the complete denture and lip plumper prosthesis




Fig. 1: Patient without lip plumper prosthesis

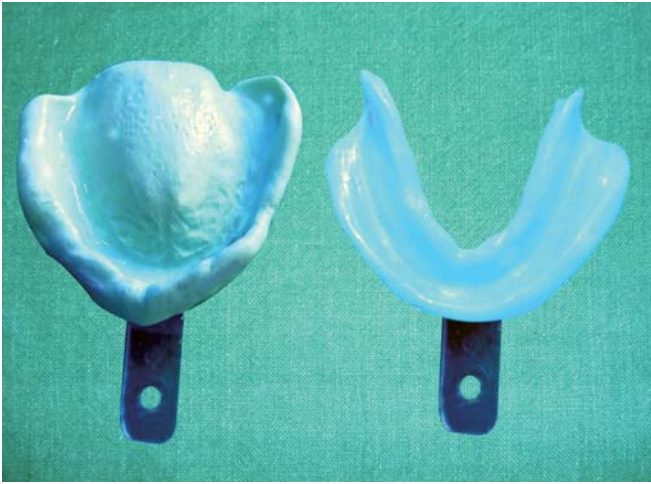

Fig. 2: Preliminary impressions

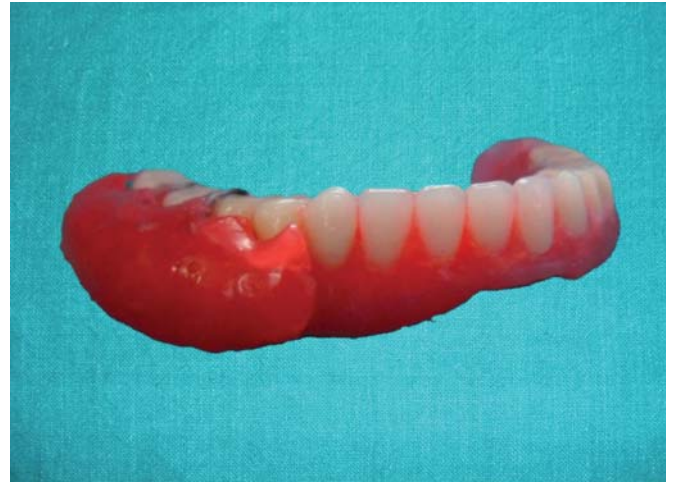

Fig. 5: Lateral view of wax-up of lip plumper retained with ball-end clasps

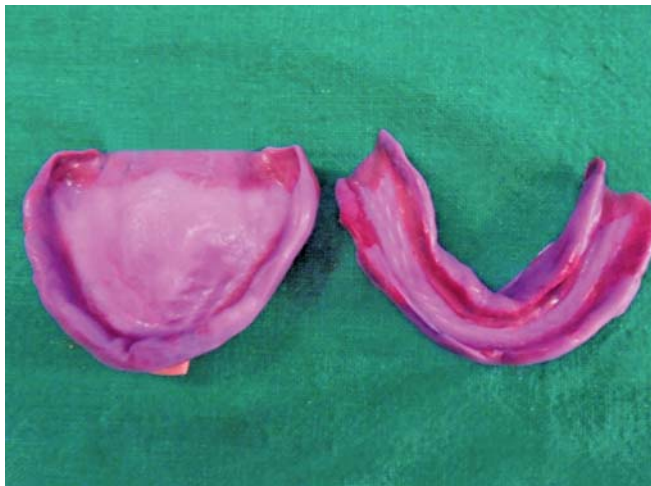

Fig. 3: Final impressions

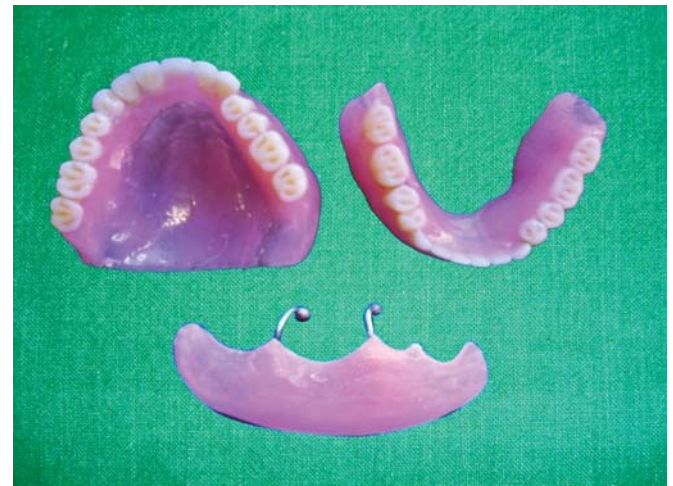

Fig. 6A: Cured denture with lip plumper prosthesis

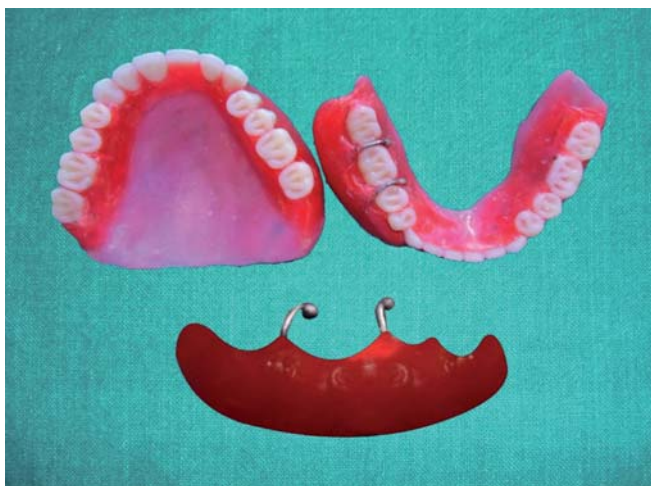

Fig. 4: Wax-up of lip plumper retained on mandibular trial denture

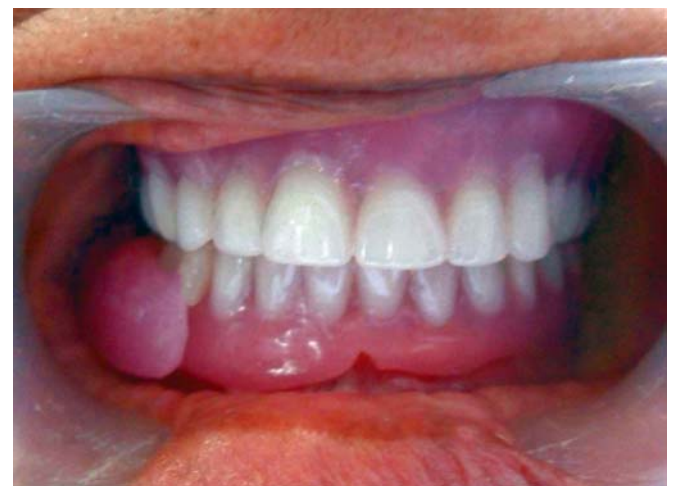

Fig. 6B: Intraoral view of denture with lip plumper prosthesis

were done separately with heat-polymerized acrylic resin. The complete denture with detachable lip plumper prosthesis was delivered to the patient (Figs 6A and B). The profile of the right lower lip of the patient was improved by wearing

the lip plumper prosthesis (Fig. 7). Denture care instructions were given to the patient. Patient was recalled after 24 hours, 1, 3 week and then after 3 months for the follow-up. Denture adjustment was done according to the patient's complaint.



Fig. 7: Patient with lip plumper prosthesis

DISCUSSION

The detachable lip plumper prosthesis successfully restored the contour of the lip and improved the function for a patient. With the lip plumper in position, the unfavorable sequel of loss of oral competency was diminished by restoring the lower lip to a more anatomically correct relationship with the upper lip. The advantage of detachable prosthesis is that it is easily retrievable and hygienic due to ease of cleansibility. This clinical report indicated the lip plumper prosthesis which has potential as a treatment method to alleviate the problems and the resultant loss of muscle activity associated with such esthetic impairment.⁶ The detachable prosthesis with ball-end clasps was recommended for achieving additional retention. Monoplane occlusion scheme was chosen to reduce the destructive lateral forces on the denture thus keeping the masticatory forces perpendicular to support. Complete denture and lip plumper were fabricated from heat-polymerized acrylic resin, so as not to compromise the patient's esthetics. With the prosthesis, changes in appearance, function and psychological wellbeing have an enormous impact on the patients' personal lives and are rewarding for the maxillofacial prosthodontist who is providing this care.⁷

SUMMARY

An intraoral detachable prosthesis was fabricated to restore more normal contour to a patient's lower lip that was compromised. The prosthesis successfully restored the lost lip support, reduced the incidence of lip biting and improved the patient's oral competency. The clinical results indicate that a lip plumper prosthesis has the potential to treat the resultant loss of muscle activity associated with such neurological impairment.

REFERENCES

1. Nandita NK, Meena AA, Vidya C. Customised attachments retained cheek plumper prosthesis: A case report. *J Ind Prostho Society* 2012;12:198-200.
2. Beumer J, Marunick MT, Curtis TA, Roumanas E. Acquired defect of the mandible. In: Beumer J, Curtis TA, Marunick MT, (Eds). *Maxillofacial rehabilitation: Prosthodontic and surgical considerations*. St. Louis: Ishiyaku EuroAmerica; 1996:113-223.
3. Jones JK, Van Sickels JE. Facial nerve injuries associated with orthognathic surgery: A review of incidence and management. *J Oral Maxillofac Surg* 1991;49:740-44.
4. Curtis DA, Plesh O, Miller AJ, Curtis TA, Sharma A, Schweitzer R, et al. A comparison of masticatory function in patients with or without reconstruction of the mandible. *Head Neck* 1997;19:287-96.
5. Head C, Alam D, Sercarz JA, Lee JT, Rawnsley JD, Berke GS, et al. Microvascular flap reconstruction of the mandible: A comparison of bone grafts and bridging plates for restoration of mandibular continuity. *Otolaryngol Head Neck Surg* 2003;129:48-54.
6. Hitoshi M, Chiaki K, Takashi O, Hisashi T. Lip plumper prosthesis for a patient with a marginal mandibulectomy: A clinical report. *J Prosthet Dent* 2004;92:23-26.
7. Chakravarthy R. Magnet retained sectional lip plumper prosthesis for a patient with hemimandibulectomy. *J Clin Diagn Res* 2010 June 2582;(4):2582-86.

ABOUT THE AUTHORS

Smriti Kapur Dewan

Assistant Professor, Department of Prosthodontics, Sh. JN Kapoor DAV (C) Dental College, Yamuna Nagar, Haryana, India

Correspondence Address: 33, Shakti Nagar, Yamuna Nagar-135001 Haryana, India, Phone: 8950400094, e-mail: doctor_smriti83@yahoo.co.in

Monika Sehgal

Reader, Department of Prosthodontics, Sh. JN Kapoor DAV (C) Dental College, Yamuna Nagar, Haryana, India

Aman Arora

Professor and Head, Department of Prosthodontics, Sh. JN Kapoor DAV (C) Dental College, Yamuna Nagar, Haryana, India

Sushant Garg

Professor, Department of Prosthodontics, Sh. JN Kapoor DAV (C) Dental College, Yamuna Nagar, Haryana, India

Sheen Juneja Arora

Reader, Department of Prosthodontics and Crown and Bridge, Sh. JN Kapoor DAV (C) Dental College, Yamuna Nagar, Haryana, India

Neha Seth

Postgraduate Student, Department of Prosthodontics, Sh. JN Kapoor DAV (C) Dental College, Yamuna Nagar, Haryana, India