

CASE REPORT

Cleidocranial Dysplasia

Sunanda Chavva, Nallamilli VS Sekhar Reddy, MR Haranatha Reddy, Rajkumar Badam

ABSTRACT

Cleidocranial dysplasia (CCD) is a bone disorder with cranial malformations, dental abnormalities, clavicular hypoplasia or agenesis and narrow thorax which allows approximation of shoulders in front of chest. We report a case of CCD and discuss about it.

Keywords: Cleidocranial dysplasia, Clavicles, Open fontanelles, Multiple supernumerary teeth, Impacted teeth, CBFA1 gene.

How to cite this article: Chavva S, Reddy NVSS, Reddy MRH, Badam R. Cleidocranial Dysplasia. *J Orofac Res* 2012;2(4): 232-234.

Source of support: Nil

Conflict of interest: None declared

INTRODUCTION

Cleidocranial dysplasia (CCD) is an autosomal dominant disorder, although 40% of cases appear spontaneously with no apparent genetic cause. This was first reported in 1760 and later by Martin in 1898. This is also called Marie-Sainton disease/mutational dysostosis. This condition is usually caused by mutation of core binding factor- α 1 gene (CBFA1 gene) located at chromosome 6p21 (microdeletion defect). It is caused by mutation of RUN X2 gene which encodes protein for correct functioning of osteoblasts. CBFA1 gene is also responsible for chondrocyte formation. The fontanelles of skull are open and excessively large due to delayed ossification. Wormian bones are seen. Bossing of the frontal, parietal and occipital regions give the skull a large globular shape with small face. The characteristic skull abnormalities are sometimes referred to as 'Arnold head' named after the descendants of a Chinese who settled in South Africa and changed his name to Arnold.¹

There is hypertelorism, flat nasal bridge or absent nasal bones, hypoplastic maxilla, hypoplastic zygoma resulting in concave facial profile. The synostosis of metopic suture gives the forehead a sunken appearance. There is frontal bossing, pseudomandibular prognathism and under-developed paranasal sinuses. Conduction deafness and mental retardation can be present in some cases. There is brachycephaly. Other features include retained deciduous teeth and multiple impacted supernumerary teeth particularly in premolar region, hand abnormalities like short broad thumbs. The chest is bell-shaped thorax with short oblique ribs. The pubic symphysis is wide and dysplastic. Femur head has chef's hat appearance. There may be

segmental calvarial thickening. There will be parallelism of mandibular ramus due to temporalis muscle pull.^{1,2}

CASE REPORT

A 17-year-old female patient came to dental clinic for cosmetic correction. On examination, she had brachycephaly, hypoplastic maxilla, hypoplastic zygoma, hypertelorism and concave facial profile. Her shoulders could be brought together at the midline. She had broad short thumbs and was of short stature (Fig. 1). She had sunken appearance on frontal bone (Fig. 2). Intraoral examination revealed multiple retained deciduous teeth and missing permanent teeth (Fig. 3). Radiographs showed multiple supernumerary impacted teeth (Fig. 4). There were absent nasal bones, hypoplastic maxilla

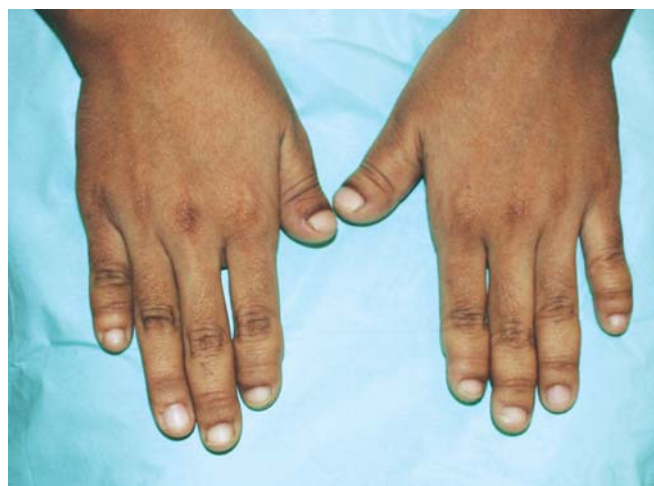

Fig. 1: Short thumbs and short terminal phalanges

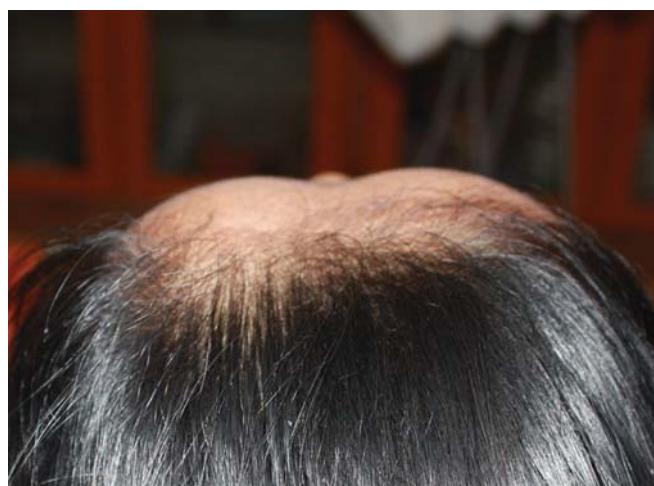

Fig. 2: Frontal bossing

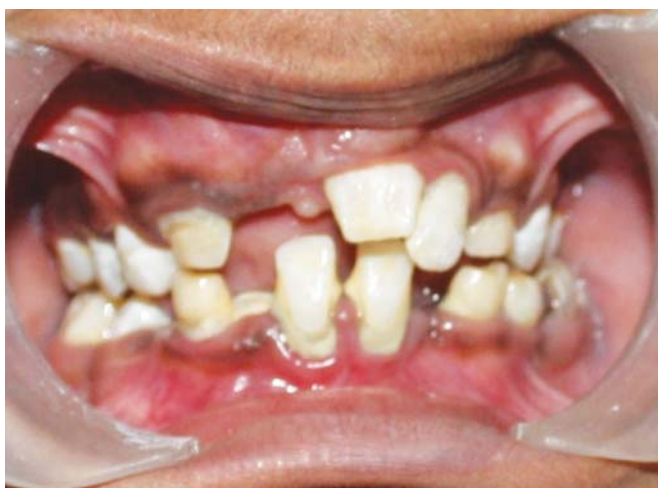

Fig. 3: Retained deciduous teeth and missing permanent teeth

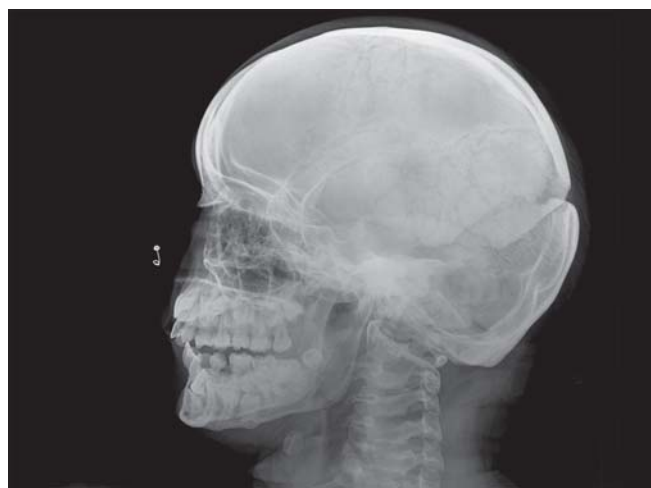


Fig. 6: Open posterior fontanelle

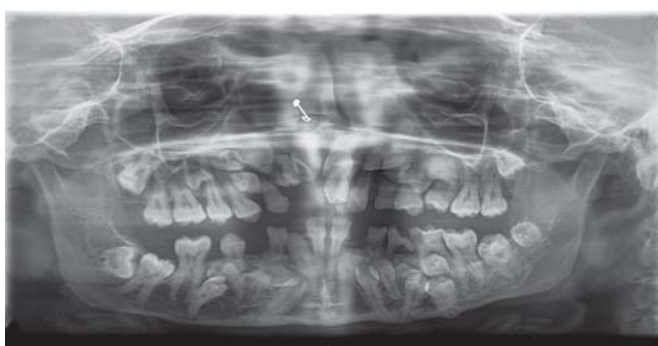

Fig. 4: Multiple unerupted supernumerary teeth

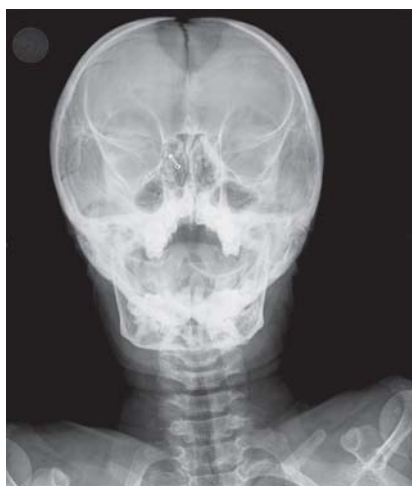

Fig. 5: Open anterior fontanelle

and hypoplastic zygoma. The anterior and posterior fontanelles were open. The lambdoid suture was also involved (Figs 5 and 6).

DISCUSSION

Many patients with hypoplastic or absent clavicles have gone through life, even working as manual laborers without disability resulting from this defect. Depending on the degree of clavicular hypoplasia, appearance ranges from a

dimple in the skin to sloping shoulders. Underdeveloped or absent clavicle make it possible for these patients to voluntarily bring the shoulders together. Complete absence of clavicle is rare, whereas hypoplasia of the acromial end is common. Abnormalities in number of ribs, such as cervical or absent ribs are not uncommon.^{3,4}

The thoracic cage is small and bell shaped with short oblique ribs. The narrow thorax may lead to respiratory distress in early infancy. The short stature is due to involvement of long bones. Both intramembranous and endochondral ossification are involved. The retained deciduous, supernumerary teeth and unerupted permanent teeth lead to malocclusion. It is probable that in CCD patients, presence of multiple supernumerary teeth may be one of the causes of impaction of permanent teeth. The resorption of dental lamina gets delayed and it gets reactivated to form supernumerary teeth.³⁻⁵ This reactivation happens after the mineralization of permanent teeth crowns. The failure of eruption of teeth has been associated with lack of cellular cementum. It has been postulated that failure of cementum formation may be due to mechanical resistance to eruption by dense alveolar bone overlying the unerupted teeth.

Hemivertebrae and posterior wedging of thoracic vertebrae may contribute to kyphoscoliosis and pulmonary complications. Pelvic bone dysplasia necessitates cesarean section in pregnant women. There is no specific treatment for patients with CCD. Genetic counseling is most important. Protective head gear may be recommended while fontanelles remain patent. The current mode of therapy for dental anomalies combines early surgical intervention with orthodontic treatment. Extraction of supernumerary teeth and over retained primary teeth, when the root formation of succedaneous teeth is greater than 50% followed by surgical exposure of unerupted teeth has resulted in stimulation of cementum formation and eruption of dentition with normal

root formation. Orthognathic surgery for correction of dentofacial deformity, postsurgical orthodontics and prosthetics can be anticipated.⁶

Differential diagnosis includes Peutz-Jeghers syndrome and Gardner syndrome since both have multiple supernumerary impacted teeth. In Peutz-Jegher syndrome, clinically there is pigmentation around body orifices. There is intestinal polyposis as well. In Gardner syndrome, there is intestinal polyposis along with other soft tissue and bone tumors. Pyknodysostosis or Maroteaux-Lamy syndrome has most of the features of CCD. But, the bones are dense and fragile. They have partial agenesis of terminal phalanges of hands and feet. Hypoplasia of clavicles can be found in partial trisomy 11q/22q and trisomy 20p. Wide cranial sutures are a rather nonspecific sign of CCD. The cranial sutures can be an indication of increased intracranial pressure or craniosynostosis. They may also be present in syndromes with impaired bone growth, including those with increased bone density (Kenny-Caffey syndrome, pyknodysostosis and others), decreased mineralization (osteogenesis imperfecta, hypophosphatasia and others) or generalized growth deficiency/bone maturation (arthritic hypothyroidism, Silver-Russell syndrome and others).^{7,8}

CONCLUSION

The triad of multiple unerupted supernumerary teeth, open fontanelles and absent or hypoplastic clavicles should be considered for diagnosis of CCD. Confirmation of the diagnosis routinely should include clinical examination of cranium, face and the clavicles. The eruption status of dentition should be compared with patient's chronological age. Combined team approach for each abnormality should be done in CCD.^{9,10}

REFERENCES

1. Mundlos S. Cleidocranial dysplasia: Clinical and molecular genetics. *J Med Genet* 1999;36:177-82.
2. Golan I, Baumert U, Wagener H, et al. Atypical expression of cleidocranial dysplasia: Clinical and molecular-genetic analysis. *Orthod Craniofacial Res* 2002;5:243-49.

3. Brueton LA, Reeve A, Ellis R, Husband P, Thompson EM, Kingston HM. Apparent cleidocranial dysplasia associated with abnormalities of 8q22 in three individuals. *Am j Med Genet* 1992;43:612-18.
4. Francke U, Weber F, Sparkes RS, Mattson PD, Mann J. Duplication 11 (q21-23-qter) syndrome. *Birth Defects* 1977;13:167-86.
5. Nakai H, Yamamoto Y, Kuroki Y. Partial trisomy of 11 and 22 due to familial translocation t(11;22)(q23;q11) inherited in three generations. *Hum Genet* 1979;51:349-55.
6. Alves N, de Oliveira R. Cleidocranial dysostosis: A case report. *Int J Morphol* 2008;26(4):1065-68.
7. Schnitzel A. Trisomy 20pter-q11 in a malformed boy from at (13; 20)(p11;q11) translocation carrier mother. *Hum Genet* 1980;53:169-72.
8. Ono E, Filho EM, Castilho JC, Tanaka JL, Moraes LC, Moraes ME. Cleidocranial dysplasia: Importance of radiographic diagnosis of the condition. *J Oral Sic Images* 2006;48:161-66.
9. Cleidocranial dysostosis. Available from: en.wikipedia.org/wiki/Cleidocranial_dysostosis.
10. Weerakkody Y, Bhattacharya B. Cleidocranial dysostosis. Available from: <http://radiopaedia.org/articles/cleidocranial-dysostosis>.

ABOUT THE AUTHORS

Sunanda Chavva

Professor, Department of Oral Medicine and Radiology, Panineeya Institute of Dental Sciences and Research Centre, Hyderabad, Andhra Pradesh, India

Nallamilli VS Sekhar Reddy (Corresponding Author)

Professor, Department of Oral and Maxillofacial Surgery, Panineeya Institute of Dental Sciences and Research Centre, Road No. 5 Kamalanagar, Dilshukhnagar, Hyderabad-500035, Andhra Pradesh India, e-mail: srn115@gmail.com

MR Haranatha Reddy

Professor, Department of Oral and Maxillofacial Surgery, Panineeya Institute of Dental Sciences and Research Centre, Hyderabad, Andhra Pradesh, India

Rajkumar Badam

Reader, Department of Oral Medicine and Radiology, Panineeya Institute of Dental Sciences and Research Centre, Hyderabad, Andhra Pradesh, India