

CASE REPORT

Molar Impactions: Etiology, Implications and Treatment Modalities with Presentation of an Unusual Case

Manjot Kaur, Singla Shefali

ABSTRACT

Tooth development results from a complicated multistep interaction between the oral epithelium and the underlying mesenchymal tissue. Abnormal tissue interactions during tooth development may potentially result in ectopic tooth development and eruption. We report a case of unerupted second molar and impacted third molar and an attempt is made to review possible causes of noneruption of teeth and their treatment modalities.

It is essential to diagnose and treat eruption disturbances as early as possible because treatment at a later stage is usually more complicated due to the tendency of malocclusion to increase with time and decrease the ability of remaining dentition to adjust.

Keywords: Impaction, Eruption, Retention.

How to cite this article: Kaur M, Shefali S. Molar Impactions: Etiology, Implications and Treatment Modalities with Presentation of an Unusual Case. *J Orofac Res* 2012;2(3):171-173.

Source of support: Nil

Conflict of interest: None declared

INTRODUCTION

Tooth development results from a complicated multistep interaction between the oral epithelium and the underlying mesenchymal tissue. Abnormal tissue interactions during tooth development may potentially result in ectopic tooth development and eruption. The impaction of mandibular second molars, given that its incidence is 0.03 to 0.21%, is a rare complication in tooth eruption. It has been detected more often in the unilateral form than the bilateral and is more common in the mandible than in the maxilla.¹ We report a case of unerupted second molar and impacted third molar in the left mandibular arch and an attempt is made to review possible causes of noneruption of teeth and their treatment modalities.

It is essential to diagnose and treat eruption disturbances as early as possible because treatment at a later stage is usually more complicated due to the tendency of malocclusion to increase with time and decrease the ability of remaining dentition to adjust.

CASE HISTORY

A 59-year-old man with excellent general health, reported to the prosthodontics department of the institute, to get a crown over his root canal treated mandibular left first premolar.

On intraoral examination, a mesially inclined tooth in the mandibular left second molar region was observed and the first molar was in infraocclusion (Fig. 1). Lower right

third molar was impacted. The maxillary arch was normal in width with impacted third molars. No history of trauma or previous infection to affected areas was specified. Medical and family histories were noncontributory and the general and extraoral examinations were within normal limits and not suggestive of any syndrome or metabolic disorder.

A panoramic radiograph (Fig. 2) showed that the mesially inclined tooth on lower left side was the third molar. The mandibular second molar was deeply impacted and horizontally placed. Distal cusp of the first molar was at the level of the occlusal surface which was in infraocclusion and revealed resorbed roots. The third molar lay above and parallel to the second molar (Fig. 3). The roots of the first molar were resorbed due to the presence of the horizontally impacted second molar. All the remaining third molars were impacted.

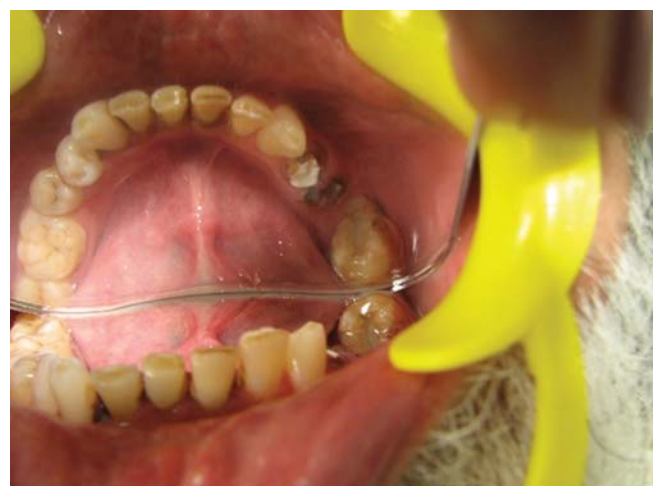

Fig. 1: Intraoral view of impacted molar

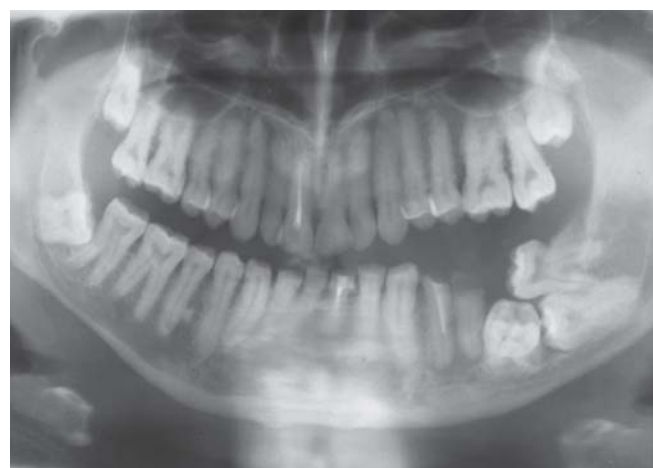


Fig. 2: Panoramic view of impacted molar

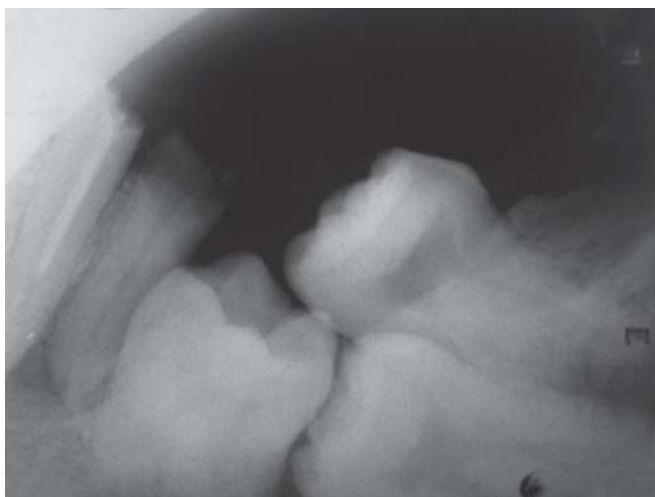


Fig. 3: IOPAR of impacted molar

Periapical radiolucency was seen in relation to the roots of the lower left premolars. The obturation of first premolar was short and had to be repeated. Both first and second premolars were given crowns following root canal treatment.

Since, the patient had no functional problems and did not wish to get any treatment, therefore, no particular treatment was given for impacted teeth and follow-up continues.

DISCUSSION

Process of tooth eruption involves complex interaction between osteoblasts, osteoclasts and dental follicular cell lines associated with the tooth germ which result in coordinated alveolar bone resorption and emergence of tooth within the oral cavity. Teeth may fail to erupt either as a result of mechanical obstruction, be it idiopathic or pathological in origin or because of disruption to the eruptive mechanism itself. The terms 'impaction' and 'retention' are often used synonymously for eruption failure but actually they are separate pathologies with different etiology and treatment approaches.²

The term impaction originates from a Latin word *impactus*. It is defined as a cessation of eruption of a tooth caused by a clinically or radiographically detectable physical barrier in the eruption path or by an ectopic position of the tooth.³ Common causes contributing to impaction are lack of space or crowding of dental arches, premature loss of the primary teeth with subsequent partial closure of the area, rotation of tooth buds, supernumerary teeth, odontoma or cyst in the path of eruption.

An impacted tooth is one that is unable to fully erupt in its proper location because it is blocked by tissue, bone or another tooth. Sometimes an impacted tooth manages to erupt in the position of another tooth. A tooth that erupts in this manner is called, *ectopic*, meaning that it is displaced or incorrectly positioned. Ectopic eruption is a developmental disturbance in eruption pattern of permanent

dentition. Often, an ectopic tooth is caused by trauma, larger width of permanent tooth, abnormal angulation of eruption of molar or delayed calcification of affected molars. The affected permanent molar may erupt at an angle to the normal eruption path, thereby ceasing the eruption and causing the resorption of the neighboring deciduous tooth. The permanent tooth may erupt, get locked in this position leading to irreversible ectopic eruption or correct without treatment and erupt into normal position. This is classified as reversible ectopic eruption⁴ Bjerklin and Kurok concluded that the type of ectopic eruption can be reliably predicted between 7 and 8 years of age. Treatment for irreversible ectopic eruption are movement of the permanent molar distally in order to regain space and correction of the mesial tipping of the permanent molar to allow normal eruption.⁵ Cross-arch anchorage may be necessary to prevent loss of Leeway space.⁶ Numerous simple techniques, such as brass ligatures, separating elastics, springs, band and spring can also be used.

Long axis of a clinically visible impacted tooth is always angulated when compared to that of neighboring teeth and may cause root resorption of adjacent teeth. Various explanations have been described in the literature, one of which is that the secretion of cytokines by the reduced enamel epithelium and dental follicle of the impacted tooth may result in osteoclast recruitment and connective tissue destruction and root resorption.⁷

Most commonly impacted teeth are third molars followed by canines. Impaction of first and second molars is rare. Multiple impacted teeth may be related to syndromes (cleidocranial dysostosis, Gardner syndrome, Yunis-Varon syndrome)^{8,9} and metabolic disorders (mucopolysaccharidoses).¹⁰ In the present case, dental history and radiographic examination excluded partial anodontia and medical, family history and extraoral examination were not suggestive of any syndrome or metabolic disorders.

According to the classification by Andreasen and Kurok the failure of eruption of the second molar can be classified into three events etiologically, clinically and radiographically:

- *Impaction*: Caused by a physical obstacle, basically due to lack of space, and which could provoke a collision between the follicles of the second and third molar. Ectopic eruption of the tooth germ and obstacles in eruptive path (extra teeth, odontomas, tumors, cysts, giant cell fibromatosis, etc.) cause impaction.¹¹
- *Primary retention* (unerupted and embedded teeth) is defined as a cessation of eruption before gingival emergence without a recognizable physical barrier in the eruption path or ectopic eruption. This kind of eruption failure is sometimes associated with syndromes where osteoclastic activity is compromised.¹² Generally, all teeth distal to the affected tooth also fail to erupt.

- *Secondary retention* (submerged, reimpaction, ankylosis) is termed as cessation of the eruption after emergence, without evidence of a physical barrier either in eruption path or as a result of an abnormal position. Clinically, secondary retention is suspected when tooth is in infraocclusion at an age when tooth would normally be in occlusion. Radiographically, a focal obliteration of periodontal space or resorption of root surface is found. Secondary retention is more common than primary retention and is caused by a small area of ankylosis especially in inter-radicular zone.¹³ The origin of ankylosis has been associated with genetic¹⁴ and systemic factors.

The present case seems to be a combination of all three entities. Lower left second molar is horizontally placed (Figs 2 and 3) and may have primarily failed to erupt leading to horizontal impaction of third molar and secondary retention of first molar. All remaining third molars seem to be impacted.

Treatment can be instituted on the basis of etiology. In case of impaction, early removal of physical barrier increases the chances of spontaneous eruption followed by orthodontic uprighting if required. In case of primary retention, involved teeth tend to ankylose if orthodontic force is applied. Unerupted tooth can be surgically repositioned following segment alveolar osteotomy. Prosthetic replacement of missing (unerupted) tooth is the last resort.¹⁵

In case of secondary retention, luxation of exposed tooth sometimes promotes eruption.¹⁶ If secondary retention develops prior to growth spurt, immediate removal of affected molar followed by orthodontic alignment of neighboring teeth can be done. Autotransplantation of third molar into the space created by missing teeth can be done.

Our treatment plan included interdisciplinary approach requiring surgical extraction of left mandibular third molar and orthodontic uprighting of the second molar but since the patient had no functional abnormalities, he did not wish to get any treatment.

CONCLUSION

Clinical absence of posterior teeth is generally discovered during a dental examination. This implies a late diagnosis of the abnormality and a poor prognosis. In order to prevent this situation, a radiographic examination (ideally during the early mixed dentition period) for early diagnosis of eruption disturbances of permanent teeth is recommended, particularly when considering that these abnormalities are associated with high rate of occlusal disturbances that require orthodontic correction. Also complete understanding of impaction, primary retention and secondary retention is necessary for differential diagnosis.

REFERENCES

1. Varpio M, Wellfelt B. Disturbed eruption of the lower second molar: Clinical appearance, prevalence and etiology. *ASDC J Dent Child* 1988;55:114-18.
2. Raghoobar GM, Boering G, Vissink A, Stegenga B. Eruption disturbances of permanent molars: A review. *J Oral Pathol Med* 1991;20:159-66.
3. Durbeck WE. General considerations. The impacted lower third molar. Great Britain: Dental items of interest publishing company 1945:1-18.
4. Young DH. Ectopic eruption of first permanent molar. *J Dent Child* 1957;24:153-62.
5. Bjerklin K, Kurol J. Treatment of children with ectopic eruption of the maxillary first permanent molar by cervical traction. *Am J Orthod* 1984;86:483-92.
6. McDonald RE, Avery DR, Dean JA (Eds). *Dentistry for the Child and adolescent* (8th ed). St. Louis, Mo: Mosby; 2004:631-68.
7. Nemcovsky CE, Tal H, Pitaru S. Effect of nonerupted third molars on roots of approximal teeth. A radiographic, clinical and histologic study. *J Oral Path Med* 1997;26:464-69.
8. Kirson LE, Scheiber RE, Tomaro AJ. Multiple impacted teeth in cleidocranial dysostosis. *Oral Surg Oral Med Oral Pathol* 1982;54:604.
9. Bradley JF, Orłowski WA. Multiple osteomas, impacted teeth and odontomas—a case report of Gardner's syndrome. *JNJ Dent Assoc* 1977;48:32-33.
10. Nakamura T, Miwa K, Kanda S, Nonaka K, Anan H, Higash S, et al. Rosette formation of impacted molar teeth in mucopolysaccharidoses and related disorders. *Dentomaxillofac Radiol* 1992;21:45-49.
11. Andreasen JO, Kurol J. The impacted first and second molar. In: Andreasen JO, Petersen JK LD (Eds). *Textbook and color atlas of tooth impactions*. Copenhagen: Munksgaard 1977;197-218.
12. Oliver RG, Richmond S, Hunter B. Submerged permanent molars: Four case reports. *Br Dent J* 1986;160:128-30.
13. Raghoobar GM, Boering G, Jansen HW, Vissink A. Secondary retention of permanent molars: A histologic study. *J Oral Pathol Med* 1989;18:427-31.
14. Reid DJ. Incomplete eruption of the first permanent molar in two generations of the same family. *Br Dent J* 1954;96:272-73.
15. Proffit WR, Katherine WLV. Primary failure of eruption: A possible cause of posterior open bite. *Am J Orthod* 1981;80:173-90.
16. Kaban LB, Needleman HL, Hertzberg J. Idiopathic failure of eruption of permanent molar teeth. *Oral Surg Oral Med Oral Pathol* 1976;42:155-63.

ABOUT THE AUTHORS

Manjot Kaur

Lecturer, Department of Public Health Dentistry, Dr Harvansh Singh Judge Institute of Dental Sciences and Hospital, Punjab University Chandigarh, India

Correspondence Address: H.No-99, Sector-18A, Chandigarh, India
Phone: +91-9815979918, e-mail: manjotkaur99@yahoo.com

Singla Shefali

Reader, Department of Prosthodontics, Dr Harvansh Singh Judge Institute of Dental Sciences and Hospital, Punjab University Chandigarh, India