

The effects of Stanozolol and high protein diet on Colon Anastomosis

Yigit Mehmet Ozgun¹, Emre Ergul², Samet Yalcin³, Birol Korukluoglu³, Gonca Ozgun⁴, Vildan Fidanci⁵, Aytun Kilinc⁵

From,¹Department of Gastroenterological Surgery, ³Department of General Surgery, Ankara City Hospital, Turkey
³Department of General Surgery Balikesir Hospital, Turkey, ⁴Department of Biochemistry, Ankara Training and Research Hospital, Ankara, Turkey.

Correspondence to: Dr. Yigit Mehmet Ozgun, Department of Gastroenterological Surgery, TC Saglik Bakanligi Ankara Training and Research Hospital, Ankara, Turkey. Email ID- dryigitozgun@gmail.com

Received -5 April 2019

Initial Review – 22 May 2019

Accepted–25 May 2019

ABSTRACT

Background: Anastomotic leakage after colonic resection and anastomosis are serious complications with high morbidity and mortality. Collagen synthesis is an essential feature of anastomotic healing. **Objective:** Our study aimed to investigate individual and combined effects of high protein diet and stanozolol on the intestinal anastomosis in rats. **Methods:** Total of 48 Wistar-albino rats were divided into four groups. Group C: Control group; Group P: high protein diet (4mg/day) administered by gavage; Group A: group to which stanozolol was administered intramuscularly (i.m) (2mg/kg/day); Group A+P: group to which both stanozolol (2mg/kg/day) i.m and high protein diet (4mg/day by gavage) were administered. In each group, half of the animals underwent surgery on the 3rd postoperative (PO) day and the other half on the 7th PO day for analysis procedures. Bursting pressures of each anastomotic segment, tissue hydroxyproline levels, and histologic tissue repair process were evaluated. **Results:** On 7th PO day, group A+P had statistically and significantly higher bursting pressures than the control group. Hydroxyproline levels at the anastomotic segment on both 3rd and 7th PO days were also significantly higher in group A+P. **Conclusion:** A high protein diet and stanozolol do not significantly impact the anastomotic healing when used separately. We concluded that high protein diet and stanozolol can be used after colorectal surgery in humans but requires further research.

Key words: Colon anastomosis, Stanozolol, Hydroxyproline, anastomotic healing

Anastomotic leakage after the colorectal surgery is one of the most devastating complications even today. In published series, the anastomosis leak rate is 0-12% and in some series, it decreases to 3-6% [1,2]. For a safe colonic anastomosis, some criteria are needed, such as- good exposure, adequate blood supply, preventing from sepsis or gross fecal contamination, a good approximation of all layers of the colon, especially submucosa, no tension of the anastomosis, patient's adequate nutritional status, and prevention of distal obstruction [3]. The experimental and clinical studies have shown that nutrition is an important factor in wound healing and malnutrition causes negative effects on healing

while replacement of the required nutrients causes an improvement of recovery [4,5].

Anabolic steroids that are testosterone derivatives are used either clinically for increasing protein synthesis or by athletes for their muscle mass-building effects. Although it is controversial, many athletes use anabolic steroids to improve their performance and muscle strength [6]. Stanozolol is one of the anabolic steroids which are exogenous androgens commonly misused by athletes [7]. It has an extensive anabolic effect and begins within hours [8,9]. Athletes should take enough protein to provide the necessary amino acids to initiate protein synthesis [10,11].

At this experimental study, we investigated the individual and combined effects of anabolic steroid (stanozolol) and high protein diet that athletes used on the healing of colon anastomosis in rats.

METHODS

The procedures followed in this study were in accordance with the Guide for the care and use of laboratory animals of the National Institutes of Health (Bethesda, MD, USA) and were approved by the Animal Ethics Committee. This study has been reported in accordance with the Animals in Research; Reporting In Vivo Experiments (ARRIVE) guidelines. Our study was approved by the ethics committee of the Faculty of medicine of Gazi University, with the number of G.Ü.ET-09.058. Total of 48 Albino Wistar rats with weight ranging from 180 to 220 gram, were divided randomly into four groups. Group 1: control (C), Group 2: high protein-fed group (P), Group 3: group which was given anabolics (A), Group 4: group which was given both anabolic and high protein (A + P).

Rats were fed with a normal daily diet (3 - 6 g / protein, 40 kcal) per day [12]. Rats from Group 2 and 4 received an extra 4 gram protein and their daily protein intake was doubled. All animals had free access to water after surgery, while the rats in Group C who went under surgery were on a normal diet. In group P, we added 4/g/day of protein powder (Protein Plus Genrise®) to the rats' normal diet by gavage by mixing it with 1.5 ml of water, after the surgical procedure. In group A, we administered 2mg/kg/day intramuscular (im) stanozolol after the surgical procedure. In group A+P we performed both additions of 4/g/day of protein powder (Protein Plus Genrise®) and 2mg/kg/day of im stanozolol after the surgical procedure.

After 8 hours of fasting, rats were anesthetized with im ketamine hydrochloride (Ketalar®, Eczacıbası, Istanbul) 40mg/kg and Xylazine (Rompun®, Bayer Ag, Germany) 5 mg/kg. The abdomen was shaved and the skin was disinfected with 10% povidone-iodine. Following a 4-cm midline incision, the left colon was transected (without any resection) 4 cm, proximally to the peritoneal reflection. The bowel was restored by end-to-end anastomosis with six interrupted inverting sutures of 6/0 Propylene (Dogsan, Turkey). Then, the peritoneum and fascia were closed with a running 3/ 0 Propylene (Dogsan, Turkey) suture. In all groups, rats were selected randomly and divided into two

equal groups. The seventh postoperative day was the final time point for bursting pressure measurements and third day was the assessment time point of early anastomosis [13-15]. The first group was re-operated on the third day and the remaining groups were re-operated on the seventh day. Anastomotic colon segment was resected with the surrounding tissue; the rat was sacrificed by intracardiac phlebotomy. Anastomotic healing was evaluated with bursting pressure, hydroxyproline measurement and histopathological examination.

We inserted a tube of a manometer to the proximal part of the anastomotic bowl segment which was secured with a suture. Distally from the anastomosis, a clamp was placed just above the peritoneal reflection. Subsequently, this segment was placed in a beaker filled with water and the air pressure was gradually increased. The bursting pressure was defined as the maximum pressure readout on the manometer before bubbles appeared after which the rats were sacrificed. The anastomotic region was resected and divided into two vertical parts. One was fixed in 4.0% formaldehyde for 24 h after which the specimens were embedded in paraffin, and the other one was dried and stored at -800C for hydroxyproline measurement.

Tissue hydroxyproline levels of groups were measured by two researchers blindly by the method described by Jamall et al. [16]. This method was based on alkaline hydrolysis of the tissue homogenate and subsequent determination of the free hydroxyproline in hydrolyzates. 50mg colonic tissue was placed in glass tubes, 1 ml of 6 NHCl added. The tissue was hydrolyzed in the autoclave at 150°C for one hour. Aliquots of 10 µl of tissue hydrolysate were added to separate vials followed by evaporation and drying at room temperature. Chloramine T 0.5 ml, after 10 minutes at room temperature, was added to 1 ml of Ehrlich and mixed well. Tubes were placed at 50°C for 90 minutes, and hydroxyproline levels were recorded on a spectrophotometer at 558 nm.

At the end of the following process, specimens were embedded in paraffin. From each tissue two pairs of 4 µm thick tissue sections were prepared. One was stained with Haematoxylin-Eosin (H-E) and the other was stained with Trikrom and both were examined under a light microscope. The histological investigations were done according to normal bowl wall. All histological assessments of groups were performed by an experienced pathologist blindly. Preparations were evaluated by, epithelization, inflammatory cell infiltration, amount of

fibroblast, neovascularization and collagen deposition. Histopathological staging of anastomosis line was performed according to Ehrlich-Hunt model [17,18].

All data were expressed as mean \pm standard deviation. Nonparametric Kruskal-Wallis test was used in statistical analysis and $P < 0.05$ was considered to be significant. Subsequent comparisons between the groups were made by Mann-Whitney U test by adjusting the probability level downward, and $P < 0.05$ was assumed to be significant. For statistical analysis, SPSS release 10.0 for Windows (SPSS Inc., Chicago, IL) statistical program was used.

RESULTS

None of the animals in any groups died during the experimental study. Histopathological data is tabulated in Tale 1. We did not observe wound infection, anastomosis leakage or any another complication, in the study groups. Anastomotic bursting pressures, hydroxyproline measurements and histopathological evaluation results of the 3rd day and the 7th day are demonstrated at Table-2 and Table-3, respectively.

Table-1: Erlich-Hunt Model

Grade	Inflammatory cells / Fibroblasts / Neovascularisation/Collagen deposition
0	No
1	Low density and separated
2	Low density and in all places
3	High density but separated
4	High density and in all places

On the 3rd day of assessment, we found significantly higher hydroxyproline levels and collagen amounts at group A than group C ($p=0.013$). There was no difference between these two groups on the 7th day. Group A had higher bursting pressures than group C, both on 3rd and the 7th days, which was statistically insignificant ($p>0.05$). According to these results, we conclude that using stanazolol on the first postoperative days, which has been adequate protein in the anastomotic field, results in an increase of collagen synthesis. In the following days, the difference could not be observed since inadequate protein exists in the anastomotic field. Similarly, on the 3rd day when there has been adequate protein in the field, there was no significant difference in collagen synthesis between group A and group A+P ($p>0.05$). Even though group A+P had higher hydroxyproline levels than both group A and

group P. This was statistically insignificant ($p>0.05$). On the 3rd day of assessment of bursting pressures between all groups, we could not observe any statistically significant differences ($p>0.05$).

On the 7th day, group A+P had significantly higher collagen deposit compared to other groups ($p<0.05$). According to these findings, we thought that usage of stanazolol individually has an effect of increasing collagen synthesis on early postoperative days but requires the addition of protein on subsequent days for adequate collagen synthesis. Collagen production was superior in the experimental group (A+P) in the same week than in the control group histopathologically (Figure 1 and 2).

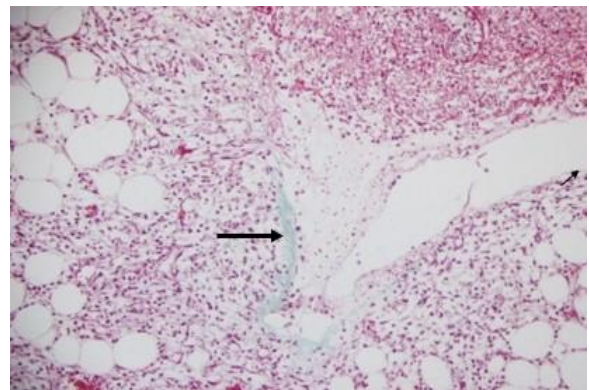


Figure 1: Trikrom staining at the control group at postoperative 7th day

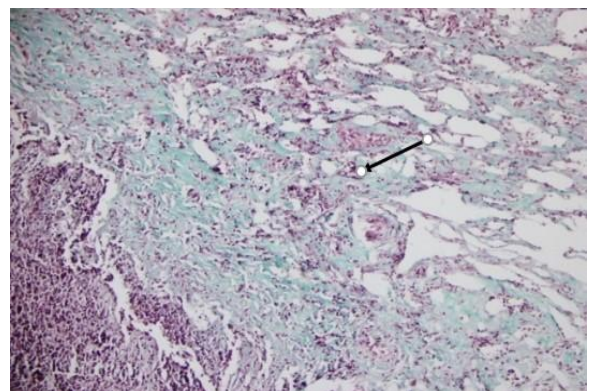


Figure 2: Trikrom staining at Stanazolol and high protein group at postoperative 7th day

Group A+P had a statistically significantly higher value of both hydroxyproline and bursting pressure levels than group C ($p<0.05$). Group A+P had statistically insignificant ($p<0.05$). But the group had higher hydroxyproline and bursting pressure levels than both

group A and group P. We found hydroxyproline levels and collagen depositions significantly higher in group A+P than group C at 7th day ($p=0.006$). Group A+P had statistically significant ($p>0.05$) higher levels of collagen deposition, epithelisation and fibroblast intensity than all groups.

DISCUSSION

We know that submucosa is the strongest layer of the colon providing the mechanical force and acts as a skeleton of the anastomosis [3,19,20]. The submucosa consists almost entirely of collagen and most

of the collagen at colon exists in submucosal layer [13].

Collagen has a critical role in wound healing, providing the strength of wound tension and construction of extracellular matrix in healing. Fibroblasts have a high density of anabolic steroid receptors on their surface. Anabolic steroids can stimulate protein synthesis by enhancing the cellular uptake of amino acids [21,22]. Hydroxyproline and vitamin C are the main substances in collagen synthesis. We know that hydroxyproline levels indicate the amount of collagen in tissues required for anastomotic healing [15].

Table-2: The comparison of bursting pressures, hydroxyproline and histopathological values of all groups on the third day

Parameters	GR C	GR A	GR P	GR A+P	p value
Bursting pressure (mmHg)	50.17±8.84 (35-60)	59.80±11.89 (50-78)	52.50±12.00 (35-70)	66.20±9.34 (56-80)	ND
Hydroxyproline (mg/g wet tissue)	1.54±0.55 (0.46-1.99)	2.19±0.22 (1.84-2.41)	1.95±0.05 (1.08-2.41)	2.47±0.35(2.19-2.95)	GR C-GR A=0.013 GR C- GR A+P=0.006
Epithelisation ^a	1.17±0.41 (1-2)	2.00±0.00 (2-2)	1.67±0.52 (1-2)	2.80±0.45(2-3)	GR C-GR A=0.017 GR C-GR A+P=0.004 GR A-GR A+P=0.014 GR P-GR A+P=0.010
Inflammatory cells ^a	2.17±0.75 (1-3)	2.40±0.55 (2-3)	1.33±0.52 (1-2)	3.60±0.55 (3-4)	GR A-GR P=0.018 GR C-GR A+P=0.017 GR A-GR A+P=0.020 GR P- GR A+P=0.004
Fibroblasts ^a	1.50±0.55 (1-2)	1.60±0.55 (1-2)	2.00±0.00 (2-2)	3.20±0.45 (3-4)	GR C-GR A+P=0.004 GR A-GR A+P=0.006 GR P-GR A+P=0.002
Neovascu-larisation ^a	1.33±0.51 (1-2)	1.60±0.55 (1-2)	1.17±0.41 (1-2)	3.20±0.45 (3-4)	GR C-GR A+P=0.004 GR A-GR A+P=0.006 GR P-GR A+P=0.003
Collagen deposition ^a	1.67±0.52 (1-2)	2.40±0.55 (2-3)	2.00±0.00 (2-2)	2.80±0.50 (3-4)	GR C-GR A+P=0.010 GR P-GR A+P=0.009

Data: Mean ± (min-max), No Difference (ND): No statistically meaningful difference ($p<0.05$); a: According to the histological Erlich-Hunt grading scale

Yarimkaya et al. studied the effects of nandrolone phenylpropionate on the healing of ischemic colon anastomosis. They administered im 2mg/kg nandrolone phenylpropionate 15 days before the surgical procedure. They have found statistically significant improvement of anastomotic healing in the group that received nandrolone phenylpropionate from the both i.e. the control group and the untreated ischemic anastomosis group [23]. An experimental study showed that the effect of nandrolone phenylpropionate on mRNA synthesis starts on 7-14th days after the administration [24]. Since nandrolone

phenylpropionate dissolves in the lipid, it is timed-release and its effects start in a long time. In our experiment, we used stanozolol that has an anabolic effect of 30 times more than testosterone [25]. Almost all anabolic steroids dissolve in oil, but 17-alpha-methyl testosterone derivated stanozolol dissolves in water. Therefore its effect begins within hours. Stanozolol has both intramuscular and oral forms which can be used every day. Stanozolol is particularly used by athletes for fast muscle gaining [11,25,26]. Athletes also increase their daily protein intake to gain more muscle mass. Our study is the first

experimental study which used stanozolol and high protein diet individually and as a combination in rats.

Feldkoren et al. reported that the optimal dose for maximum binding to the receptor is 1-2.5 mg/kg in experimental models. In our study, we administered 2 mg/kg/day im stanozolol as in the literature [23,27]. We increased rats' daily protein intake two times by giving protein powder (Protein Plus Genrise®), which is usually used by athletes. We administered 4gr/ day protein powder to the rats through gavage by diluting it in water. During the first postoperative days, anastomotic strength was low and anastomotic collagen levels changed massively. Martens and Hendriks reported that collagen synthesis is

enhanced very quickly after wounding. Incorporation of hydroxyproline levels gets high 48 hours after operation [20]. Therefore we decided to study all groups' collagen synthesis on the third day for early postoperative assessment and seventh day for late assessment. Falanga et al. reported that anabolic steroid Stanozolol increases collagen synthesis. A large part of this effect is due to the increasing TGF- β 1. Due to their experimental study on human dermal fibroblasts, the mRNA levels of TGF- β 1 increased as early as 2 hours after exposure of fibroblasts to stanozolol. Also, they showed that since Stanozolol is testosterone derived with high anabolic/androgenic ratio, it results in dramatic healing when used for ischemic ulcerations [28].

Table 3: The comparison of bursting pressures, hydroxyproline and histopathological values of all groups on seventh day

Parameters	GR C	GR A	GR P	GR A+P	p value
Bursting pressure (mmHg)	166.50 \pm 12.71 (150-180)	178.20 \pm 14.90 (158-200)	175.67 \pm 26.28 (140-200)	195.00 \pm 10.00 (180-210)	GR C-GR A+P=0.006
Hydroxyproline (mg/g wet tissue)	1.88 \pm 0.30 (1.39-2.13)	2.19 \pm 0.34 (1.84-2.72)	2.11 \pm 0.52 (1.18-2.56)	2.70 \pm 0.53 (2.16-3.54)	GR C-GR A+P=0.025
Epithelisation ^a	2.83 \pm 0.41 (2-3)	2.67 \pm 0.52(2-3)	2.50 \pm 0.55 (2-3)	3.60 \pm 0.49 (3-4)	GR C-GR A+P=0.043 GR A-GR A+P=0.030 GR P-GR A+P=0.019
Inflammatory cells ^a	3.00 \pm 0.00(3-3)	2.17 \pm 0.75 (1-3)	2.50 \pm 0.55 (2-3)	2.60 \pm 0.80 (2-4)	ND
Fibroblasts ^a	2.67 \pm 0.52 (2-3)	2.67 \pm 0.52(2-3)	2.83 \pm 0.41 (2-3)	4.00 \pm 0.00 (4-4)	GR C-GR A+P=0.001 GR A- GR A+P=0.006 GR P-GR A+P=0.006
Neovascularisation ^a	1.33 \pm 0.51 (1-2)	2.30 \pm 0.82 (1-3)	2.50 \pm 0.55 (2-3)	2.67 \pm 0.52 (2-3)	ND
Collagen deposition ^a	3.00 \pm 0.00 (3-3)	3.00 \pm 0.63(2-4)	2.83 \pm 0.41 (2-3)	4.00 \pm 0.00 (4-4)	GR C- GR A+P=0.001 GR A-GR A+P=0.006 GR P-GR A+P=0.001

Data: Mean \pm (min-max), No Difference (ND): No statistically meaningful difference ($p < 0.05$); a: According to the histological Erlich-Hunt grading scale

When we evaluate only the protein-administrated group P, both hydroxyproline levels and bursting pressure values were a little higher than group C but the difference was statistically insignificant ($p > 0.05$). There were similar results between the two groups at histopathological values ($p > 0.05$). In our study, the increasing individual protein uptake had no significant effects on colon anastomosis. The anabolic process of protein synthesis, with new tissue formation, requires the action of anabolic hormones [4]. The amount of protein intake suggested for the general population is 0.8-1 gr protein / per kg / day [11,29]. On the other hand, athletes require 1.2-2 gr/kg/day protein. According to literature, we performed both additions of 4/g/day of protein powder (Protein Plus Genrise®) and

2mg/kg/day im stanozolol to the rats in group A+P after the surgical procedure.

On the 3rd day, we could not observe any statistically significant differences of bursting pressures between all groups. This could be due to the fact that early anastomotic strength depends on suture holding a capacity of existing collagen fibrils and that newly formed synthesized collagen fibrils need to bridge the gap and restore the original strength of the bowel wall [20,30]. If we assess fibroblast proliferation, we can see group A+P is significantly better than the other groups on both 3rd and 7th days. Group A has not a significant effect on fibroblast proliferation, but the increased hydroxyproline levels were

similar to the literature [28]. The effect of stanozolol on fibroblast proliferation can be evaluated with further studies in the cell cultures by adding protein, as we did in our study.

Group A+P had statistically significant ($p>0.05$) higher levels of collagen deposition, epithelisation and fibroblast intensity than all groups at 7th day. As a result, we can say that using stanozolol and high protein diet combination makes a significant recovery in colon anastomosis in rats by increasing the synthesis of collagen. We observed that the thickness of colon segments of rats in group A+P, were more than the rats in other groups. We analyzed this result during the process of allocation of colonic segments for histopathologic and biochemical examinations.

CONCLUSION

Using stanozolol and high protein diet combination which is used by athletes for muscle growth enhances the recovery of experimental colon anastomosis. On this basis, using Stanozolol and high protein diet combination clinically, after colon surgeries, would be a positive contribution to improve the colon anastomosis and accelerate the healing process. An advantageous effect of starting the Stanozolol within hours enables usage of this combination at an early postoperative time. That means we can use this combination in unscheduled cases like emergency resections. It can reduce anastomotic leakage, morbidity, and mortality. We suggest that after further clinical investigations, stanozolol and high protein diet combination can be included in the treatment of colon resections especially in emergency cases or in cases of patients with high risks for anastomosis.

REFERENCES

1. Kingham TP, Pachter HL. Colonic anastomotic leak: risk factors, diagnosis, and treatment. *J Am Coll Surg.* 2009; 208(2):269-78.
2. Chua CL. Colonic anastomosis with suture less biofragmentable rings. *Singapore Med J.* 1993;34(6): 541-4.
3. Bielecki K, Gajda A. The Causes and Prevention of Anastomotic Leak After Colorectal Surgery *KlinickaOnkologie.* 1999;12:25-30.
4. Demling RH. The role of anabolic hormones for wound healing in catabolic states. *J Burns Wounds.* 2005;4:e2.
5. Pickleman J, Watson W, Cunningham J, et al. The failed gastrointestinal anastomosis: an inevitable catastrophe? *J Am Coll Surg.* 1999; 188(5):473-82.
6. Haupt HA, Rovere GD. Anabolic steroids: a review of the literature. *Am J Sports Med.* 1984;12(6):469-84.
7. Acevedo P, Jorge JC, Cruz-Sánchez A, et al. A ten-year assessment of anabolic steroid misuse among competitive athletes in Puerto Rico, *West Indian Med J.* 2011 Oct;60(5):531-5.
8. Reiter M, Pfaffl MW, Schönfelder M, et al. Gene expression in hair follicle dermal papilla cells after treatment with stanozolol. *Biomark Insights.* 2008;4:1-8
9. Konerding MA, Ziebart T, Wolloscheck T, et al. Impact of single-dose application of TGF- β , copper peptide, stanozolol and ascorbic acid in hydrogel on midline laparotomy wound healing in a diabetic mouse model. *Int J Mol Med.* 2012;30(2):271-6
10. Lambert CP, Frank LL, and Evans WJ. Macronutrient considerations for the sport of bodybuilding. *Sports Med.* 2004; 34(5):317-27.
11. William N. Taylor MD. *Anabolic Steroids and The Athlete.* Second ed. 2002, Mc Farland Company Inc.: North Carolina.
12. Karahasanoglu T, Altınlı E, Hamzaoglu İ, et al. Effect of growth hormone treatment on the healing of left colonic anastomoses in protein-malnourished rats. *Br J Surg.* 1998;85(7):931-3.
13. Hendriks T. Mastboom WJ. Healing of experimental intestinal anastomoses. Parameters for repair. *Dis Colon Rectum.* 1990; 33(10): 891-901.
14. Rolandelli RH, Koruda MJ, Settle SG, et al. Effects of intraluminal infusion of short-chain fatty acids on the healing of colonic anastomosis in the rat. *Surgery.* 1986; 100(2):198-204.
15. E Ergul, YM Ozgun, G Kiyak, et al. Does Low Molecular Weight Heparin Impair Anastomotic Wound Healing? *J Gastrointest Surg.* 2009;13:798–803.
16. Jamall IS, Finelli VN, and Que Hee SS. A simple method to determine nanogram levels of 4-hydroxyproline in biological tissues. *Anal Biochem.* 1981;112(1):70-5.
17. Giuratrabocchetta S, Rinaldi M, Cuccia F, et al. Protection of intestinal anastomosis with biological glues: an experimental randomized controlled trial. *Techniques in Coloproctology.* 2011;15(12):153-158.
18. Phillips JD, Kim CS, Fonkalsrud EW, et al. Effects of chronic corticosteroids and vitamin A on the healing of intestinal anastomoses. *Am J Surg.* 1992;163(1):71-7.
19. Haukipuro K, Melkko J, Risteli L, et al. Synthesis of type I collagen in healing wounds in humans. *Ann Surg.* 1991; 213(1):75-80.
20. Martens MF, Hendriks T. Postoperative changes in collagen synthesis in intestinal anastomoses of the rat: differences between small and large bowel. *Gut.* 1991; 32(12):1482-7.

21. Saggars, G. C. ; Allison, G. M. ; Levinson, H. ; Kramer, T. ; Mackay, Donald ; Ehrlich, H. P. / The Influence of the Anabolic Agent, Oxandrolone, upon the Expression of Procollagen Types I and III mRNA in Human Fibroblasts Cultured on Collagen or Plastic. In: Wounds. 2000;13(2):66-71.
22. Martens MF, CM Huyben, and Hendriks T. Collagen synthesis in fibroblasts from human colon: regulatory aspects and differences with skin fibroblasts. Gut. 1992; 33(12):1664-70.
23. Yarimkaya A, Apaydin B, Unal E, et al. Effects of recombinant human growth hormone and nandrolone phenylpropionate on the healing of ischemic colon anastomosis in rats. Dis Colon Rectum. 2003;46(12): 1690-7.
24. Cen Y, Li K, Liu XX. Effect of nandrolone phenylpropionate on expression of hepatic albumin-mRNA and androgen receptor in burned rats. Zhongguo Xiu Fu Chong Jian Wai Ke Za Zhi. 2003;17(6): 439-41.
25. Kuhn CM. Anabolic steroids. Recent Prog Horm Res. 2002;57:411-34.
26. Donald G. Barceloux, Medical Toxicology of Drug Abuse: Synthesized Chemicals and Psychoactive Plants, Wiley, JohnWiley and sons copyright 2012;15:286.
27. Feldkoren BI, Andersson S. Anabolic-androgenic steroid interaction with rat androgen receptor in vivo and in vitro: a comparative study. J Steroid Biochem Mol Biol. 2005; 94(5):481-7.
28. Falanga V, Greenberg AS, Zhou L, et al. Stimulation of collagen synthesis by the anabolic steroid stanozolol. J Invest Dermatol. 1998;111(6):1193-7.
29. Lemon PW, Tarnopolsky MA, MacDougall JD, et al. Protein requirements and muscle mass/strength changes during intensive training in novice bodybuilders, J. Appl Physiol. 1992;73(2):767-75.
30. Foster, M.E, Laycock JR, Silver IA et al., Hypovolaemia and healing in colonic anastomoses. Br J Surg, 1985. 72(10): 831-4.

Funding: None; Conflict of Interest: None Stated.

How to cite this article: Ozgun MY, Ergul E, Yalcin S, Korukluoglu B, Ozgun G, Fidanci V, et al. Non small cell Carcinoma- Lung: Distribution and spectrum of mutations among patients in Eastern India. Eastern J Med Sci. 2019;4(2):88-94.
DOI: 10.32677/EJMS.2019.v04.i02.007