

## Griscelli syndrome type 2: The first reported case of compound heterozygous mutation in RAB 27 A gene from India

Nishad Dhakate<sup>1</sup>, Manjit Rajput<sup>2</sup>

From <sup>1</sup>Consultant Hematology, <sup>2</sup>Consultant Pathologist, Department of Hematology and Bone Marrow Transplant, HCG NCHRI Cancer Center, Nagpur Maharashtra, India.

**Correspondence to:** Dr. Nishad Dhakate, Department of Hematology and BMT, HCG NCHRI Cancer Centre, Near Automotive Square, Kalamna Ring Road, Nagpur - 440026, Maharashtra, India. E-mail: [dr.nishad.dhakate@gmail.com](mailto:dr.nishad.dhakate@gmail.com)

Received - 03 October 2019

Initial Review - 21 October 2019

Accepted - 30 November 2019

### ABSTRACT

Griscelli syndrome (GS) is a rare autosomal recessive disorder resulting in pigmentary dilution of the skin and hair with variable phenotypes depending upon the underlying genetic mutation. Mutations in 3 distinct genes *MYO5A*, *RAB27A*, *MLPH* are responsible for 3 subtypes (GS1, GS2, and GS3) of GS respectively. Griscelli syndrome type 2 (GS-2) is a rare autosomal recessive disease. It commonly presents with hemophagocytic lymphohistiocytosis (HLH) and recurrent infections due to immunodeficiency. We describe a 3-year-old female with pyrexia, silvery hair, lymphadenopathy, hepatosplenomegaly, and hemophagocytosis. We found a novel compound heterozygous mutation in the *RAB 27A* gene. She succumbed despite being on dexamethasone and septran prophylaxis. This case spreads awareness about this rare potentially fatal disease, as a high index of suspicion is required for prompt diagnosis and treatment. Early bone marrow transplant is the only curative treatment for GS-2.

**Keywords:** *Griscelli syndrome, Hemophagocytosis, RAB 27 A gene, Silvery gray hair.*

Griscelli syndrome (GS), a rare autosomal recessive disorder is characterized by partial albinism, along with immunologic abnormalities or severe neurological impairment or both [1]. Only 14 cases have been reported from India, the last reported in 2017 [2]. Mutation in 3 distinct genes *MYO5A*, *RAB27A*, *MLPH* is responsible for 3 subtypes (GS1, GS2, and GS3) of GS respectively [1-4]. Most of the patients with GS-2 display the hemophagocytic syndrome and have mutations in *RAB27A* gene [2]. A high index of suspicion is required for the prompt diagnosis and treatment of this potentially fatal disease and prevent complications. Chemotherapy followed by bone marrow transplant is the only curative treatment.

### CASE REPORT

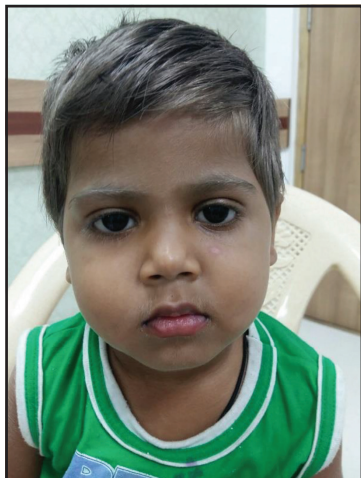A 3-year-old girl born of non-consanguineous parentage presented with a history of high-grade fever without chills and rigors since 2.5 months. She had a history of painless right-sided neck swelling, around 3x 4 cm in size a few months back which lasted for 15 days until she underwent a right cervical lymph node biopsy. She was admitted to a hospital 2 months back for these complaints.

On examination, she had pallor. Her abdominal examination revealed splenomegaly of 3 cm and the liver was palpable 2 cm below the costal margin. Her complete blood count showed pancytopenia with hemoglobin of 6.0 gm/dl, white blood cells  $3.2 \times 10^9/L$  (L - 62%, P - 30%) and platelet count was  $90,000/mm^3$ .

Her lactate dehydrogenase (LDH) was significantly elevated at 1948 U/L. Chest X-ray showed left-sided infiltrates. Her lymph node biopsy showed reactive lymphocytes. It did not reveal any granulomas. There was no increase in blasts, immunohistochemistry (IHC) for a cluster of differentiation (CD) 20 and CD 30 was negative. Ziehl Neelsen and Gomori Methenamine-Silver (GMS) were negative. Bone marrow aspiration and biopsy revealed a cellular marrow with increased macrophages and hemophagocytosis. There was no increase in blasts. Her parents refused chemotherapy, so, she was started on anti-tubercular therapy (ATT), since tuberculosis was a close differential. They stopped ATT after 5 days in view of persistent fever and mistrust.

At presentation, she was afebrile since 4 days. She had lost 3 kg weight in the last 2 months. Her father denied any history of bleeding manifestations, bony pains and night sweats. She had a very characteristic silvery hair of the scalp, body, eyelashes and eyebrows (Fig. 1). The skin and iris had normal pigmentation. She had pallor. Abdominal examination revealed a just palpable spleen and hepatomegaly 3 cm. Other systems were normal.

Her investigations at our hospital showed a hemoglobin of 10 gm/dl, WBC count of  $7.18 \times 10^9/L$  and platelet count  $313,000/mm^3$ . Peripheral smear showed microcytic hypochromic anemia. Polymorphs lacked the hallmark giant granules of Chediak Higashi syndrome. LDH was within normal limits at 556 U/L. Serum ferritin was raised 252.78 ng/ml. Serum Triglyceride was normal at 184.0 mg/dl.



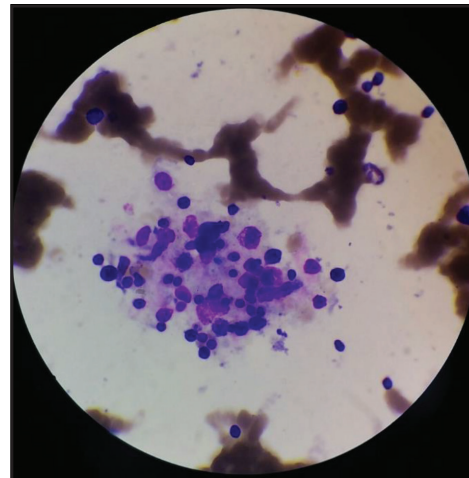
**Figure 1:** Silvery-gray hair of the scalp, eyebrows, and eyelashes in the indexed case.

She was advised admission and chemotherapy for further management, however father refused admission despite explaining the life threatening nature of the disease. She was started on Dexamethasone 10 mg once a day and Septran prophylaxis (single strength twice a day every Monday and Friday) for 1 month.

Bone marrow aspiration slides were reviewed later which showed profound hemophagocytic activity (Fig. 2). The genetic test for familial hemophagocytic lymphohistiocytosis (HLH) was positive for a compound heterozygous mutation in the *RAB27A* gene. A heterozygous c.550C>T nonsense variation in exon 6 of the *RAB27A* gene that results in a stop codon was detected. Another, heterozygous 5' splice site variation in intron 3 of the *RAB27A* gene that affects the invariant GT donor splice-site downstream of exon 3 (c.239+1G>T) was detected (Fig. 3). This confirmed Griscelli syndrome type 2. As per telephonic conversation, she was afebrile for 3 weeks, but became acutely sick with sudden enlargement of the cervical lymphnodes and succumbed.

**DISCUSSION**

Claude Griscelli first described two unrelated patients with partial albinism, frequent pyogenic infections and acute episodes of fever, neutropenia and thrombocytopenia in 1978 [1]. GS is a rare autosomal recessive disorder caused by mutations in *MYO5A* (Myosin VA), *RAB27A* (Ras related protein Rab-27A) and *MLPH* (melanophilin) genes which are responsible for the varied manifestations of type 1, 2, and 3 respectively [2-4]. GS 1 usually manifests with primary dysfunction of the central nervous system without immunological involvement. However, Yair Anikster



**Figure 2:** Bone marrow aspiration showing hemophagocytosis of hematopoietic cells suggestive of HLH.

conjectured that GS 1 with primary neurological involvement caused by mutations in *MYO5A* is synonymous with Elejalde syndrome [5]. GS 2 is characterized by HLH and recurrent infections while GS 3 manifests with only partial albinism. GS 2 is often fatal; therefore, early recognition of patients with GS-2 and prompt intervention with bone marrow transplant is critical [6].

GS2 is a rare primary immunodeficiency disease with the characteristic silvery gray hair of the scalp and body. Microscopic examination of hair reveals uneven clusters of aggregated melanin pigment, accumulated mainly in the medullary area of the shaft [7]. Skin biopsy shows increased deposition of melanosomes in the melanocytes contrasting with poorly pigmented adjacent keratinocytes. The immunodeficiency seen in GS2 is due to impairment of T-cell and natural killer cytotoxic activity, resulting in susceptibility to repeated infections. Bone marrow aspiration and biopsy show HLH in most of the cases of GS2.

Our patient presented with a constellation of fever, silvery gray hair, cytopenias, splenomegaly and hemophagocytosis. The peripheral smear did not reveal the characteristic coarse granules in the neutrophils excluding the possibility of Chediak-Higashi syndrome. A genetic test for Familial HLH demonstrated a novel compound heterozygous mutation in *RAB27A* gene. A heterozygous nonsense variation in exon 6 of the *RAB27A* gene that results in a stop codon and premature truncation of the protein at codon 184 (p.Arg184) was detected. This signifies C550T leading to R184X mutation. Another, heterozygous 5' splice site variation in intron 3 of the *RAB27A* gene that affects the invariant GT donor splice-site downstream of exon 3 (c.239+1G>T) was detected.

These genetic mutations have been independently reported as homozygous mutations in case reports. This is the first case report of such a compound heterozygous mutation from India leading to GS. A homozygous C550T leading to R184X mutation (X is a stop mutation) in *RAB27A* gene was identified in two case reports from India [8,9]. In another case report from India homozygous splice site mutation in c239+1 G-T in intron 3 was reported in a 1-year old child presenting with seizures and neurodevelopmental regression. The parents were heterozygous for the said mutation [10,11]. Compound heterozygous mutations have been reported

RESULTS						
LIKELY PATHOGENIC VARIANT CAUSATIVE OF THE REPORTED PHENOTYPE WAS IDENTIFIED						
Gene (Transcript)*	Location	Variant	Zygosity	Disease (OMIM)	Inheritance	Classification
<i>RAB27A</i> (-) (ENST00000396307)	Exon 6	c.550C>T (p.Arg184Ter)	Heterozygous	Griscelli syndrome type 2	Autosomal recessive	Likely Pathogenic
	Intron 3	c.239+1G>T (5' splice site)	Heterozygous			

**Figure 3:** The genetic test for familial HLH.

**Table1: Original: Cases of Griscelli syndrome from India with their salient clinical features.**

Serial Number	Age and Sex	Type Of Griscelli	Seizures	Silvery grey hair	Splenohepatomegaly	Pancytopenia Bicytopenia	Mutation	Outcome at the time of case report
1	20 m Male	Subtype 2	no	+	+	+	Not documented	Alive
2	12 m Female	Subtype 2	yes	+	+	+	Homozygous RAB 27 A	Died
3	13 day Male	Subtype 2	No	+	No	No	Homozygous RAB 27 A	Alive
4	22 m Male	Subtype 2	Yes	+	+	+	Not documented	Died
5	30 m Male	Subtype 2	no	+	+	+	Homozygous RAB 27 A	Alive
6	4 yr male	Subtype 2	No	+	+	+	Not documented	Alive
7	5 yr Male	Subtype 2	No	+	+	+	Homozygous RAB 27 A	Alive
8	9 yr male	Subtype 3	No	+	No	No	Not documented	Alive
9	11 m male	Subtype 2	Yes	+	No	+	Not documented	Alive
10	1 year male	Subtype 2	no	+	+	+	Not documented	Alive
11	2.5 year	Subtype 2	no	+	+	+	Homozygous RAB 27 A	Alive
12	7 year female	Subtype 2	no	+	No	No	Not documented	Alive
13	1 year male	Subtype 2	no	+	+	+	Not documented	Alive

earlier from a Swedish family. Table 1 gives a list of cases reported from India with their salient clinical features.

## CONCLUSION

Griscelli syndrome subtype 2 is a rare primary immunodeficiency disease with the characteristic silvery gray hair of the scalp and body. Griscelli syndrome is a spot diagnosis due to the characteristic silvery hair over the entire body. It is a fatal disorder if not recognized and treated timely. The only curative treatment is a stem cell transplant.

## REFERENCE

- Griscelli C, Durandy A, Guy-Grand D, Daguillard F, herzog C, Prunieras M. A syndrome associating partial albinism and immunodeficiency. *Am J Med.* 1978;65:691-702.
- Minocha P, Choudhary R, Agrawal A, Sitaraman S. Griscelli syndrome subtype 2 with hemophagocytic lympho-histiocytosis: A case report and review of literature. *Intractable Rare Dis Res.* 2017;6:76-9.
- Ménasché G, Pastural E, Feldmann J, Certain S, Ersoy F, Dupuis S, *et al.* Mutations in RAB27A cause Griscelli syndrome associated with haemophagocytic syndrome. *Nat Genet.* 2000;25:173-6.
- Ménasché G, Ho CH, Sanal O, Feldmann J, Tezcan I, Ersoy F, *et al.* Griscelli syndrome restricted to hypopigmentation results from a melanophilin defect (GS3) or a MYO5A F-exon deletion (GS1). *J Clin Invest.* 2003;112:450-6.
- Pastural E, Barrat FJ, Dufourcq-Lagelouse R, Certain S, Sanal O, Jabado N, *et al.* Griscelli disease maps to chromosome 15q21 and is associated with mutations in the myosin-Va gene. *Nat Genet.* 1997;16:289-92
- Anikster Y, Huizing M, Anderson PD, Fitzpatrick DL, Klar A, Gross-Kieselstein E, *et al.* Evidence that Griscelli Syndrome with Neurological Involvement Is Caused by Mutations in RAB27A, Not MYO5A. *Am. J. Hum. Genet.* 2002;71:407-14.
- Schneider LC, Berman RS, Shea CR, Perez-Atayde AR, Weinstein H, Geha RS. Bone marrow transplantation (BMT) for the syndrome of pigmentary dilution and lymphohistiocytosis (Griscelli's syndrome). *J Clin Immunol.* 1990;10:146-53.
- Klein C, Philippe N, Le Deist F, Fraïtag S, Prost C, Durandy A, *et al.* Partial albinism with immunodeficiency (Griscelli syndrome). *J Pediatr.* 1994;125:886-95.
- Sheela SR, Latha M, Injody SJ. Griscelli syndrome: Rab 27a mutation. *Indian Pediatr.* 2004;41:944-7.
- Singh A, Garg A, Kapoor S, Khurana N, Entesarian M, Tesi B. An Indian Boy with Griscelli Syndrome Type 2: Case Report and Review of Literature. *Indian J Dermatol.* 2014;59: 394-7.
- Panigrahi I, Suthar R, Rawat A, Behera B. Seizure as the Presenting Manifestation in Griscelli Syndrome Type 2 *Pediatr Neurol.* 2015;52: 535-8

Funding: None; Conflict of Interest: None Stated.

**How to cite this article:** Dhakate N, Rajput M. Griscelli syndrome type 2: the first reported case of compound heterozygous mutation in RAB 27 A gene from India. *Indian J Case Reports.* 2019;5(6):512-514.

Doi: 10.32677/IJCR.2019.v05.i06.002