

A rare case of term viable abdominal pregnancy with review of literature

Manika Agarwal¹, Nalini Sharma², Vinayak Jante³, Subrat Panda¹

From ¹Associate Professor, ²Assistant Professor, ³Post Graduate Trainee, Department of Obstetrics Gynecology, North Eastern Indira Gandhi Regional Institute of Health and Medical Sciences, Shillong, Meghalaya, India.

Correspondence to: Dr. Nalini Sharma, Department of Obstetrics and Gynecology, B 1 D, North Eastern Indira Gandhi Regional Institute of Health and Medical Sciences, Shillong - 793018, Meghalaya, India. E-mail: nalinisharma100@rediffmail.com

Received - 20 October 2019

Initial Review - 05 November 2019

Accepted - 20 November 2019

ABSTRACT

Abdominal pregnancies are rare types of ectopic pregnancies with high rates of maternal and perinatal morbidity and mortality. Abdominal pregnancy accounts for up to 1.4% of ectopic pregnancies. We report a case of term live abdominal pregnancy without malformation with implantation of the placenta into the uterus and anterior abdominal wall, discovered during a planned obstetric hysterectomy indicated for placenta accreta. Abdominal pregnancy is a serious and potential life-threatening condition. Diagnosis and management can be difficult especially in developing countries. A high index of suspicion is key for timely diagnosis and intervention to prevent life-threatening complications.

Keywords: Abdominal pregnancy, Ectopic pregnancy, Haemorrhage, Maternal Mortality.

Abdominal pregnancy is defined as pregnancy anywhere within the peritoneal cavity, exclusive of tubal, ovarian, or broad ligament locations [1]. Abdominal pregnancies are rare types of ectopic pregnancies with high rates of maternal and perinatal morbidity and mortality. Abdominal pregnancy accounts for up to 1.4% of ectopic pregnancies [2]. The incidence of abdominal pregnancy ranges between 1:10000 pregnancies and 1:30,000 pregnancies [3]. Maternal mortality is approximately 7.7 times that of other locations of ectopic pregnancy and 90 times that of intrauterine pregnancy [4]. The Pouch of Douglas is the most common location of abdominal pregnancy followed by the mesosalpinx and omentum. Though, implantation on other abdominal organs such as the spleen, liver, and appendix is also documented [5,6,7]. Abdominal pregnancy is not only rare but it is associated with poor maternal and or perinatal outcomes.

Hence, we report a rare case of term, live abdominal pregnancy without malformation with implantation of the placenta into the uterus and anterior abdominal wall, discovered during a planned obstetric hysterectomy indicated for placenta accreta.

CASE REPORT

A 32-year-old female G₁₀P₆L₆A₃ presented to our tertiary care center at 35weeks+2days of gestation with complaint of lower abdominal pain which was dull aching, generalized, off and on, not referred or radiating anywhere, not associated with nausea or vomiting or with fetal movement and with no bleeding per vagina or leaking per vagina, perceiving adequate fetal movement. The patient had only two antenatal visits before at primary health center and she did not undergo any ultrasound. She had 4 spontaneous

vaginal deliveries and the last two caesarean section deliveries in view of oligohydramnios and previous one caesarean section.

On examination, the patient was conscious, oriented and vitals were within normal limits with no pallor or edema. Her cardiovascular and respiratory system did not reveal any abnormalities. On abdominal examination, a vertical scar was noted below umbilicus with fundal height corresponding to 36 weeks of gestation and the uterus was relaxed. The presentation was cephalic with a regular fetal heart rate (140 beats/min). Per speculum examination revealed no leaking or bleeding per vagina. On per vaginal examination, the cervix was parous, soft, long, and posterior. Her hemoglobin was 9.6gm%. Other routine investigation were- packed cell volume (PCV) 28%, total leucocyte count (TLC) 8200 cells/mm³, differential leucocyte count (DLC) N85%, L10%, M3%, E2%, and Platelet were 2.8lacs/mm³. Erythrocyte sedimentation rate (ESR) was 20 mm/1hr, and random blood sugar was 122mg/dl. Her liver and renal function tests were normal. Thyroid-stimulating hormone was 0.93miu/ml and FreeT4 was 0.86ng/dl.

After admission, obstetrics ultrasonography was done. It was found single live intrauterine fetus at 36weeks+5days of gestational age, 2.8kg with central anterior placenta previa with adequate liquor. As it was a case of central placenta previa with the previous 2 caesarean sections, ultrasonography was repeated to rule out or confirm placental accrete syndromes and it was found to placenta accreta.

The patient was planned for an elective caesarean hysterectomy at 36 weeks of gestation by her date after cross-matching adequate blood and blood product. The abdomen was opened by vertical incision. There were dense adhesions present

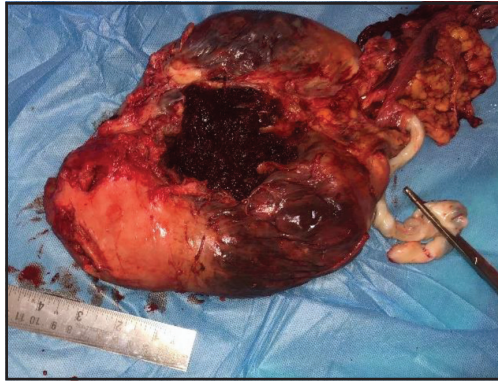


Figure 1: Placenta attached outside the 8 weeks size Uterus.

between the omentum and anterior abdominal wall. The placenta was attached to the uterus and anterior wall of the abdomen. The baby was lying in the peritoneal cavity behind the uterus, a live female baby of 2.7 Kg extracted by the breech. Bilateral tubes and ovaries were within normal limits. Uterus was 8 weeks size. Resection of the placenta was done which was attached to anterior abdominal wall and uterus (Fig. 1). Hence, subtotal hysterectomy was performed. The abdominal viscera were free from adhesions.

The diagnosis of full-term abdominal pregnancy, with implantation of the placenta into the uterus was retained. Intraoperative blood loss was about 3 liters. Intraoperatively, she received 4 packed red blood cells along with 4 fresh frozen plasma and 4 platelets. In immediate postoperative period, her hemoglobin was 5.2 gm %. Postoperatively, she received two more units of blood transfusion. Her postoperative period was uneventful and the patient discharged in a healthy condition with a healthy baby on the postoperative day 9 with hemoglobin 8.2 g/dl. After discharge, the patient did not come for follow-up.

DISCUSSION

Abdominal pregnancies are quite rare. Cases of primary advanced live abdominal pregnancies are even rarer. The present case was a term live abdominal pregnancy without malformation. The maternal mortality rate is 0.5 to 8%, and perinatal mortality ranges between 40% and 95% in abdominal pregnancies [8]. Abdominal pregnancies are either primary or secondary, primary peritoneal implantation remains an uncommon possibility and secondary being commoner. In secondary abdominal pregnancy, pregnancy primarily implanted in the tubes or, the ovaries and reimplanted in the peritoneum after tubal abortion or rupture where the embryo continues to grow. For the diagnosis of primary abdominal pregnancy, Studdiford's criteria should be present. These are: (a) normal bilateral fallopian tubes and ovaries; (b) the absence of utero-peritoneal fistula; and (c) pregnancy-related exclusively to the peritoneal surface and early enough to abolish the prospect of secondary implantation following a primary nidation elsewhere like in the tube [9]. In our case, both the tubes, ovaries and uterus were intact.

Advanced abdominal defined as when pregnancy grows beyond 20 weeks of gestation with signs of a fetus lived and developed in the mother's peritoneal cavity. In the presence of following signs, the clinician should consider the diagnosis:

abdominal pain with intestinal movement, abdominal pain with fetal movement, abnormal contour of the abdomen due to an abnormal presentation, palpation of the fetal parts under the maternal abdominal wall, cervix deviated under pubis symphysis and failure to induction of labor. But most of these signs only appear during already advanced abdominal pregnancies. The patient can be asymptomatic in many cases as in our case. Correct diagnosis, therefore, calls for a high index of suspicion.

First-trimester ultrasound scan is vital because the chances of missing the diagnosis are more in the second and third trimesters. Ultrasound diagnostic error is anticipated at 50–90 % in several case series [4]. A classic feature of absent myometrium between the maternal bladder and the fetus guides the ultrasound diagnosis of abdominal pregnancy [10]. Other diagnostic features comprise an empty uterus, an ill-defined placenta, oligohydramnios and an abnormal fetal lie [11]. Magnetic Resonance Imaging (MRI) provides added information in cases of uncertainty and can assist to define the degree of abdominal and pelvic organ invasion by the placenta [12]. The location of the placental site can assist to decide whether or not to continue the pregnancy, and facilitate to develop a comparatively safe and rational treatment option and surgical planning [12]. In spite of advances in diagnostic imaging, preoperative diagnosis remains a challenge with only 20–40 % of cases diagnosed pre-operatively [13]. Many of these cases, diagnosed on the basis of the following complications such as intraperitoneal hemorrhage and abdominal pain.

Abdominal pregnancy is an intra-operative finding in 40 to 50% of cases as in the present case [14]. It is a consensus that pregnancy should be terminated if it is diagnosed before 20 weeks. Conservative management can be considered if it is diagnosed after 20 weeks of gestation and delivery planned at 34 weeks of gestation [15]. This choice is only possible where a patient is well aware of the risks and benefits, is clinically stable and is under close observation [16]. She must be hospitalized with 24 hours access to anesthesia, surgery and blood products. Growth restriction and congenital anomalies should be ruled out and the placental implantation should be in the only lower abdomen in the uterus [4].

Depends on the gestational age and the physical state of the patient, various pregnancy termination options in early pregnancy are, laparoscopic or open surgery, arterial embolization, and intracapsular injection of potassium chloride into the abdominal gestational sac; systemic methotrexate. Though different complications arise to various degrees, with hemorrhage is the most frequent complication. Irrespective of fetal viability, open surgery is the main means of treatment in advanced abdominal pregnancies. With uterine artery embolization, injection of potassium chloride into the abdominal pregnancy sac, and other conservative treatment options can cause a higher occurrence of infection, late bleeding and fistula formation during the fetus ossification process as the dead fetus cannot be absorbed entirely [15].

Preoperative arterial embolization decreases blood loss. Placental vascular embolization also facilitates the resorption of placenta that is left in situ [17]. During laparotomy, bleeding from the placental implantation site is the most life-threatening complication. The decision to remove the placenta or to left in

situ can be an influential factor for the survival of the patient and this judgment should be based on the expertise of the surgeon and on the individual case. Placenta in situ will undergo spontaneous resorption. Methotrexate therapy can be used to accelerate the process. Leaving the placenta in situ decreases the risk of bleeding but there will be an increased risk of necrosis, pelvic abscess and wound dehiscence [18]. This decision should, however, be individualized depending on the placental site. If the placenta was left in situ, then it is recommended that follow-up should be done with human chorionic gonadotropin levels and serial ultrasonography [18]. In the present case, the placenta was implanted on the uterus mainly and anterior abdominal wall hence with subtotal hysterectomy placenta was removed completely. In these pregnancies, fetus died before the term.

Overall, the chance of having a live birth in a case of abdominal pregnancy is estimated at 10–20% [4]. One more challenge for babies of these pregnancies is a very high occurrence of congenital malformations. About 21% of babies born after an abdominal pregnancy have birth defects, most probably due to an absence of the amniotic fluid cushion leading to compression of the fetus. Characteristics deformities are limb defects, facial and cranial asymmetry, pulmonary hypoplasia, joint abnormalities and central nervous system malformation [19]. Abnormal placental colonization site leads to poorer blood supply as compared to a normal intrauterine pregnancy; hence, neonatal growth restriction is comparatively common. Abdominal pregnancy at term with a healthy viable fetus is, therefore, an exceptionally rare situation and only a few similar cases have been mentioned [20]. In the present case, the baby neither had growth restriction nor congenital malformation.

CONCLUSION

Abdominal pregnancy is a serious and potentially life-threatening condition for the mother as well as the fetus. Diagnosis and management can be difficult especially in developing countries. A high index of suspicion is the key for timely diagnosis and intervention to prevent life-threatening complications.

REFERENCES

1. Worley KC, Hnat MD, Cunningham FG. Advanced extrauterine pregnancy: diagnostic and therapeutic challenges. *Am J Obstet Gynecol.* 2008;198:297.1-7.

2. Dover RW, Powell MC. Management of a primary abdominal pregnancy. *Am J Obstet Gynecol.* 1995;172:1603-4
3. Nwobodo EI. Abdominal pregnancy .A case Report. *Anna Afri Med.* 2004;3:195-6
4. Kun KY, Wong PY, Ho MW, Tai CM, Ng TK. Abdominal pregnancy presenting as a missed abortion at 16 weeks' gestation. *Hong Kong Med J.* 2000;6:425-7.
5. Nama V, Gyampoh B, Karoshi M, McRae R, Opemuyi I. Secondary abdominal appendicular ectopic pregnancy. *J Minim Invasive Gynecol.* 2007;14:516-7.
6. Chui AK, Lo KW, Choi PC, Sung MC, Lau JW. Primary Hepatic pregnancy. *ANZ J Surg.* 2001;71:260-1.
7. Yagil Y, Beck-Razi N, Amit A, Kerner H, Gaitini D. Splenic pregnancy: the role of abdominal imaging. *J Ultrasound Med.* 2007;26:1629-32.
8. Martin JN Jr, Sessums JK, Martin RW, Pryor JA, Morrison JC. Abdominal pregnancy: current concepts of management. *Obstet Gynecol.* 1988;71:549-57.
9. King M, Bewes PC, Cairns J, Thornton J, eds. *Abdominal pregnancy in primary surgery.* 2014. Chapter 8.
10. Varma R, Mascarenhas L, James D. Successful outcome of advanced abdominal pregnancy with exclusive omental insertion. *Ultrasound Obstet Gynaecol.* 2003;21:192-4.
11. Allibone GW, Fagan CJ, Porter SC. The sonographic features of intrabdominal pregnancy. *J Clin Ultrasound.* 1981;9:383-7.
12. Lockhat F, Corr P, Ramphal S, Moodley J. The value of magnetic resonance imaging in the diagnosis and management of extra-uterine abdominal pregnancy. *Clin Radiol.* 2006;61:264-9.
13. Costa SD, Presley J, Bastert G. Advanced abdominal pregnancy. *Obstet Gynaecol Surv.* 1991;46:515-25.
14. Bhandary A, Thirunavukkarasu S, Ballal P, Shedde D, Rai S. A rare case of term viable secondary abdominal pregnancy following rupture of a rudimentary horn: a case report *J Med Case Reports.* 2009;38:1-3
15. Huan K, Song Lei, Wang L, Gao Z, Meng Y, Lu Y. Advanced abdominal pregnancy: an increasingly challenging clinical concern for obstetricians. *Int J Clin Exp Pathol.* 2014;7:5461-72.
16. Brewster EM Sr, Braithwaite EA, Brewster EM Jr. Advanced abdominal pregnancy: a case report of good maternal and perinatal outcome. *West Indian Med J.* 2011;60:587-9.
17. Cardosi RJ, Nackey AC, Londono J, Hoffman MS. Embolization for advanced abdominal pregnancy with a retained placenta. A case report. *J Reprod Med.* 2002;7:861-3.
18. Voedisch AJ, Frederick CE, Nicosia AF, Stovall TG. Early pregnancy Loss and Ectopic Pregnancy. *Berek And Novak's Gynecology Fifteenth edition Wolter Kluwer.* 2012;p619-51
19. Stevens CA. Malformations and deformations in abdominal pregnancy. *Am J Med Genet.* 1993;47:1189-95.
20. Baffoe P, Fofie C, Gandau BN. Term Abdominal Pregnancy with Healthy Newborn: A Case Report. *Ghana Medic J.* 2011;45:81-3.

Funding: None; Conflict of Interest: None Stated.

How to cite this article: Agarwal M, Sharma N, Jante V, Panda S. A rare case of term viable abdominal pregnancy with review of literature. *Indian J Case Reports.* 2019;5(6):548-550.

Doi: 10.32677/IJCR.2019.v05.i06.014