

Case Report

A rare case report of spontaneous frothy secretion from intact skin: Role of fungal allergic disease

Yateendra Dinker¹, Loknandini Sharma², Harshita³, Innayath Kabir⁴

From ¹Medical Specialist, Department of Medicine, ²Dermatologist, Department of Dermatology, 9 Air Force Hospital, Halwara, Ludhiana, ³Microbiologist, Department of Microbiology, KG Hospital, Coimbatore, Tamilnadu, ⁴MD Specialist, Department of Hospital Administration, 6 Air Force Hospital, Coimbatore, Tamilnadu, India.

Correspondence to: Dr. Yateendra Dinker, Department of Medicine, 9 Air Force Hospital, Halwara, Ludhiana - 141106, Punjab, India. E-mail: yateendradinker@gmail.com

Received - 30 September 2019

Initial Review - 18 October 2019

Accepted - 05 November 2019

ABSTRACT

Fungi are common aeroallergens which form a major part of bioaerosol. About 2-6% of the general population is allergic to fungi belonging to genera *Aspergillus*, *Penicillium*, *Alternaria* and *Fusarium* in developed countries. Here, we report a case series of 8 school going children of age 8 to 9 years who simultaneously reported with chief complaints of spontaneous mysterious white frothy secretion oozing from the surface of the intact skin while they were attending their classes. The role of fungal allergic reaction was suspected and skin secretions were sent for fungal as well as bacterial culture. Fungal culture done on air sampling plates was found positive for *Aspergillus* species. Cutaneous manifestations in the form of urticaria, angioedema have been reported in the previous literature, this case report shows a rare phenomenon of spontaneous oozing frothy white secretion which has not been reported in the literature so far.

Keywords: Allergy, Colonies, Fungi, Spores.

Fungi are common aeroallergens that form a major part of bioaerosol [1, 2]. Fungi belong to three major phyla: Zygomycota, Ascomycota and Deuteromycota. Mycelium of Zygomycetes is multinucleated and reproduces sexually as well as vegetatively, Ascomycetes have septate hyphae and they reproduce sexually, producing bags of spores while Deuteromycetes are asexual fungi [3]. Fungi reside within the remnants of animals and plants within the soil and thrive in high humidity over 70%, at temperatures of 6-35°C [4].

About 2-6% of the general population is allergic to fungi belonging to genera *Aspergillus*, *Penicillium*, *Alternaria* and *Fusarium* in developed countries [5] and this manifest in form of hypersensitivity reactions. IgE-mediated type I reactions are seen in the case of atopic individuals and manifests itself as urticaria, or atopic dermatitis. Type II hypersensitivity reaction occurs in response to the cell wall mannan – polysaccharide component of *aspergillus* and *candida* species. Rarely, it can be type III hypersensitivity reaction known as allergic alveolitis and bronchopulmonary aspergillosis (ABPA) [5].

Our report deals with a series of 8 cases which manifested in the form of spontaneous frothy secretion; there were no other systemic complaints or symptoms however related to fungal invasion.

CASE REPORT

In the mid-summer and rainy season of July in a school of Southern India, 8 school-going children out of which 5 girls and 3 boys

belonging to the age group of 8-9 years were brought by parents and school authorities to us with a chief complaint of spontaneous white secretion oozing from the surface of the intact skin. The nature of secretion was watery, frothy and non-foul smelling. The episodes of spontaneous secretions were mainly noticed over the dorsum of the hands, nape of the neck and under the school shirts thereby wetting the uniform (Fig. 1). The secretions were mainly noticed between 11 am to 1 pm in the school going children and were considered a strange never seen and never heard occurrence which created panic among parents as well as school authorities. The role of an allergic reaction due to bacteria or fungi was suspected and the case was also discussed with a dermatologist.

On further interrogation, it was found that the school was undergoing major renovation, as a result, the classrooms were

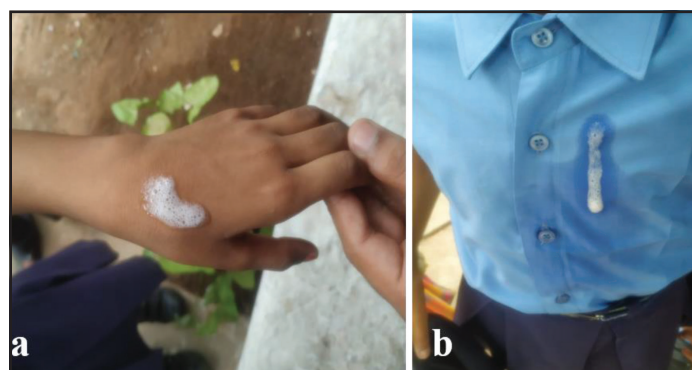


Figure 1: Spontaneous frothy secretion oozing from the intact skin and under surface of clothes.

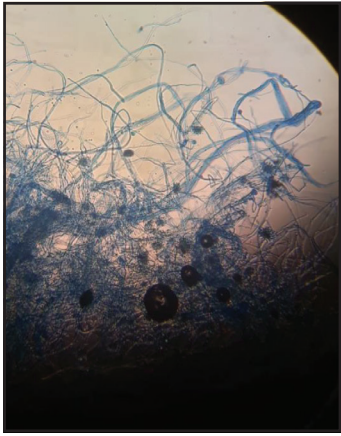


Figure 2: Fungal smear showing septate hyphae.

shifted to an otherwise abandoned and vacant place which was lying closed and unoccupied from months. The walls were found to be damp with a musty odour and the room had false roofing. Thirty-four children belonging to the good socioeconomic conditions were accommodated in a classroom and were studying in that classroom from the past 5 to 6 months. Considering the nature of ambiance, a strong suspicion of fungal contamination was suspected.

Air samples were obtained on agar plates from the room and were sent for bacterial and fungal cultures. Smear was taken from the frothy secretion oozing out from the skin surface for microbiological assessment. All 8 children (none were siblings, all unrelated) were isolated, detained and examined thoroughly for any attention-seeking behavior other skin manifestations. A history of atopy, the possibility of dermatitis artefacta, topical application of any irritant and oral intake of any substance was ruled out by the dermatologist. There were no other cutaneous manifestations in the form of urticaria, angioedema, redness, itching, flushing, etc. None of the teachers or other school staff was found affected.

Detailed clinical examination and hematological investigations were carried out. All other students of the class were also thoroughly clinically examined for any complaints or signs and symptoms and were followed up for the next 2-3 days. Systemic examination was unremarkable. Complete blood count, absolute eosinophil and serum IgE levels of all children were within normal limits. Chest examination revealed clear lung fields on auscultation as well as on chest X-ray. A trial of oral amox-clav at 25mg/kg/day and cetirizine 10mg once a day along with topical steroid was given for a period of 3 days but there was no response. Oral antifungal was not started and reserved by a dermatologist until the reports of smear investigations and air plate culture were available.

Smear examination confirmed the presence of multiple intertwining and overlapping septate, filamentous hyphae and multiple sporulating conidiospores along with gram-positive and gram-negative commensals. Fungal culture report of air plate samples showed more than 180 colonies per 1000cc of air and spores of aspergillus species were visible when stained

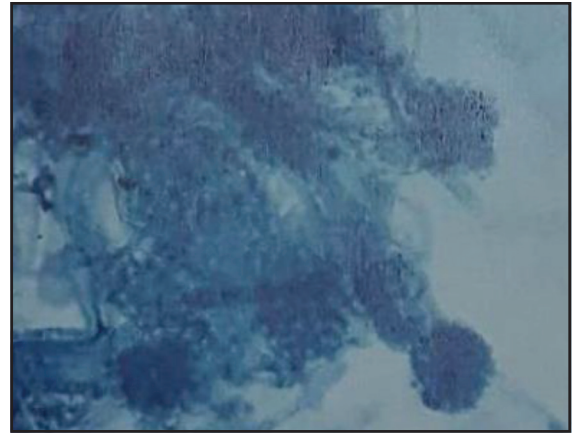


Figure 3: Spores of aspergillus species stained with lactophenol cotton blue.

with lactophenol cotton blue (Fig. 2 and 3). The role of allergic fungal disease was established and oral Itraconazole was started in the dose of 5mg/kg bodyweight for a period of 15 days. The spontaneous white frothy secretions stopped within a week of starting the medicine and were never reported thereafter till date.

DISCUSSION

Air space is occupied with allergens of various indoor residing fungi almost all through the year but their growth is aggravated by poor light and airflow. Some studies have shown that the number of spores may even exceed 250,000 per cubic meter of household room-air [6]. This is mainly seen in kitchens, bathrooms, basements. An outbreak of moulds has been detected in wet wallpapers and roofings of ill-ventilated rooms. In our case report, *Aspergillus* species was found to be the main component of the room air detected on microbiological samples of the air obtained on agar plates. Fungal colonies are seen as brown and black spots, which may give a clue of invasion by fungi of genus *Penicillium* or *Aspergillus*. These fungi release toxins known as mycotoxins which are notorious of causing “sick building” (sick building syndrome – SBS) [7,8].

Pathogenic fungi like *Aspergillus niger* is responsible for skin infections. These dermatophytes reside in keratin protein of skin epidermis due to their high affinity for them. Colonies of fungal hyphae form matted mycelium by thriving on keratin as their food and release spores and few species are known for producing mycotoxins. The fungal cell wall component acts as foreign antigens and mounts immunological response causing inflammation thereby damaging anatomical structures of the skin [9]. Cross-reactions predominantly autoimmune in nature have been reported owing to the homology of human skin protein to fungal antigens [10].

In our case report since there were no signs of inflammation or any other systemic symptoms in terms of fever, malaise, hypotension or shock, so it is a possibility that the response to colonizing fungal antigens can be explained due to partial sharing and cross-reaction of fungal and skin proteins. Since the phenomenon was observed in a few children and the rest of the children as well as adults

were spared, the role of nascent immunity among few children can be suggested. The spontaneous nature of secretions was seen predominantly on the exposed parts of the body and the clothes while the flexures and closed parts of the body were spared, this could be explained on the ease of colonization of fungus on the exposed parts and daily wearable school uniform of children.

CONCLUSION

There has been a rise in the number of allergy cases on exposure to moulds and more commonly among the immunocompromised patients. A number of antigens have been recognized as allergens but the role and pathomechanism remain unknown. The case reported belongs to this category where more studies need to be carried out regarding molecular mechanism and the new phenomenon of spontaneous frothy oozing of secretions from intact skin remain domain untouched and unanswered.

REFERENCES

1. Gniadek A, Macura AB. The presence of fungi in the environment of social welfare homes and the threat of mycotoxins. *Annales UMCS, section D*, 2003;58:160-5.
2. Ejdys E. Influence of ambient air quality of bioaerosol in the school premises during the spring and autumn – mycological assessment. *Ochrona Środowiska Zasobów Naturalnych*. 2009;41:142-50.
3. Gregova G, Kmetova M, Kmet V, Venglovsky J, Feher A. Antibiotic resistance of *Escherichia coli* isolated from a poultry slaughterhouse. *Ann Agric Environ Med*. 2012;19:75-7.
4. Miklaszewska B, Grajewski J. Pathogenic and allergenic fungi in the environment of man. *Alergia*. 2005;24:45-50.
5. Bogacka E, Matkowski K. Effect of fungi on human health. *Mikologia Lekarska*. 2001;8:175-8.
6. Gąska-Jedruch U, Dudzińska MR. Microbial contaminants in indoor air. Conference materials of Third National Congress of Environmental Engineering. Lublin, 13-17.09. 2009;31-40.
7. Brunekef B. Dump housing and adult respiratory symptoms. *Allergy*. 1992;47:498-502.
8. Coolay JD, Wong WC, Jumper CA, Straus DC. Correlation between the presence of certain fungi and sick building syndrome. *Occup Environ Med*. 1998;55:579-84.
9. Mungan D, Bavbek S, Peksari V, Celik G, Gügey E, Misirligil Z. Trichophyton sensitivity in allergic and nonallergic asthma. *Allergy*. 2001;56:558-62.
10. Semik-Orzech A, Barczyk A, Pierzchała W. The effect of the presence of hypersensitivity to fungal allergens on the development and course of allergic diseases of the respiratory system. *Pneumonol Alergol Pol*. 2008;1: 29-36.

Funding: None; Conflict of Interest: None Stated.

How to cite this article: Dinker Y, Sharma L, Harshita, Kabir I. A rare case report of spontaneous frothy secretion from intact skin: Role of fungal allergic disease. *Indian J Case Reports*. 2019;5(6):509-511.

Doi: 10.32677/IJCR.2019.v05.i06.001