

Case Report

Rheumatoid arthritis 1st time presenting with bilateral pleural effusion- A rare presentation

Sayan Malakar¹, Kailash Nath Sharma², Abhinav Rana³, Katyayni¹, Tarun Sharma⁴

From ¹3rd Year Junior Resident, ²Professor, ³Senior Resident, ⁴Assistant Professor, Department of Medicine, Dr. Rajendra Prasad Government Medical College & Hospital Tanda, Kangra, Himachal Pradesh, India.

Correspondence to: Dr. Tarun Sharma, Department of Medicine, Dr. Rajendra Prasad Government Medical College & Hospital Tanda, Kangra - 176001, Himachal Pradesh, India. E-mail: tarunpgi@gmail.com

Received - 26 July 2019

Initial Review - 13 August 2019

Accepted - 22 August 2019

ABSTRACT

Rheumatoid arthritis is the most common chronic autoimmune disorder involving joints and extra-axial system. Varied presentations have been described in the literature. Pulmonary involvement is also common. Inflammatory pleural effusions are an uncommon complication and are rarely seen in about 2% to 5% of patients with rheumatoid arthritis. Here, we present an interesting case where the patient presented with bilateral pleural effusion early in the disease. On further evaluation of the patient and the pleural fluid, it was found to be consistent with pleural effusion secondary to rheumatoid arthritis. The patient responded to oral non-steroidal anti-inflammatory drugs along with disease-modifying agents.

Keywords: *Extrarticular, Pleural effusion, Rheumatoid arthritis.*

Rheumatoid arthritis (RA) is a chronic autoimmune disorder characterized by chronic symmetrical inflammatory polyarthritis along with other systemic manifestations. It is the most common form of chronic inflammatory polyarthritis and often complicates with joint damage and deformities. RA may present with different extra-articular manifestations like constitutional features such as malaise, fatigue, fever and organ-specific involvement of lung, heart, central and peripheral nervous system, eyes, skin, and heart [1,2]. Among pulmonary manifestations, pleuritis is the most common presentation [3-5]. Apart from pleuritic, interstitial lung disease (ILD), pleural effusion, pulmonary nodule and, pulmonary hypertension are the other manifestations of RA in the lung [5,6].

Inflammatory pleural effusions are an uncommon complication seen in about 2% to 5% of patients with RA [7-10]. Effusion usually occurs during the evolution of established RA, but occasionally they are seen contemporaneously with the onset of arthritic symptoms. Rheumatoid effusions are seldom seen in the absence of arthritic disease. Here, we present a rare and unusual presentation of RA patient with bilateral pleural effusions without significant joint involvement and disease activity.

CASE REPORT

A 62-year-old male patient presented with complaints of bilateral symmetrical joint pain involving metacarpophalangeal and proximal interphalangeal joints for the last 2 months and pleuritic chest pain for the last 8 days. Joint pain was associated with increased local warmth and swelling and pain drastically

improved after taking naproxen tablets for 2 days. Presently, when the patient reported to our medicine outpatient department, he was pain-free. The patient also complained of morning stiffness in bilateral hands lasting for around 2 hours every day after getting up from the bed. The patient did not complain of pain in eyes, redness, or decreased vision. There was no history of skin lesion, burning micturition or frequency of micturition.

On examination, his vitals were stable. His blood pressure was 126/78mmHg, pulse rate was 76/min regular and respiratory rate of 18/min. General physical examination was inconclusive. Presently, there were no tender swollen joints or any subcutaneous nodule. Respiratory examination revealed decreased bilateral air entry in infra-scapular and infra axillary area with stony dullness on percussion and fine end-inspiratory crackles.

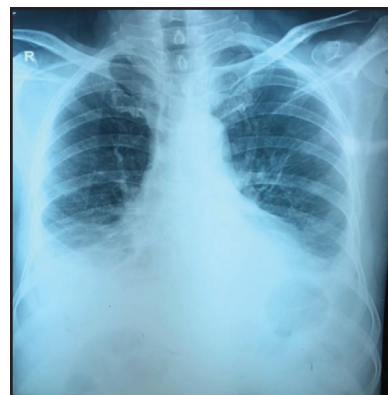

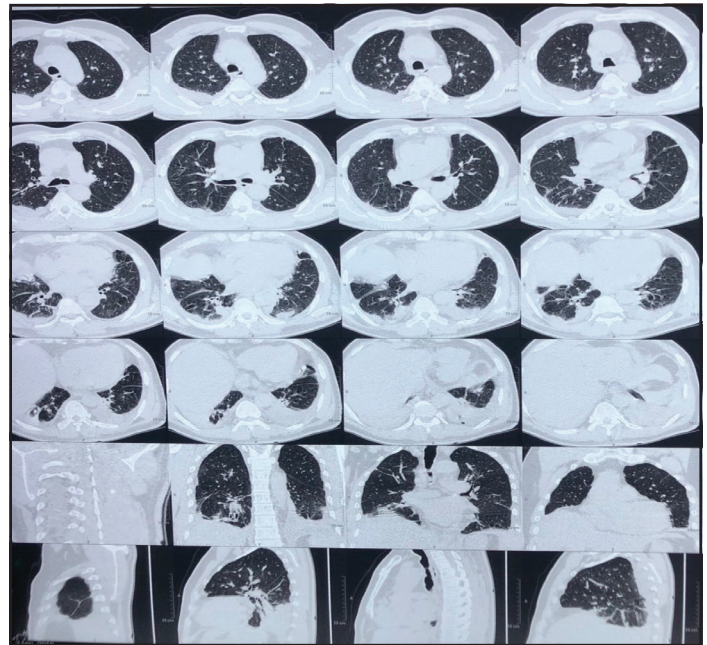
Figure 1: X-ray chest showing bilateral blunting of costophrenic angle.

Table 1: The biochemical parameters of the patient

Parameters	Right side	Left side	Serum (concomitant)
Total protein (g/dL)	5.4	5.0	7.7
Albumin (g/dL)	3	3.1	3.3
Lactate Dehydrogenase (U/L)	834	540	262
Glucose (mg/dL)	36	21	93
WBC (per mm ³)	2520	1990	-
Differential leukocyte count	N 68% L 32%	N 71% L 29%	-
RA factor	Positive	Positive (15.5) (normal 10)	-
C3 (mg/dL)	52.42 (low)	32.5 (low)	-
C4 (mg/dL)	6 (low)	4.3 (low)	-
Brain natriuretic peptide (BNP)	Negative	Negative	110pg/mL
Adenosine deaminase (ADA) (U/L)	32	32	11
Malignant cells	Negative	Negative	-
Catridge-based nucleic acid amplification test (CBNAAT)	Negative	Negative	-
Culture acid-fast bacilli (AFB)	Negative	Negative	-
Gram-stain CS	Sterile	Sterile	-
Cholesterol (mg/dL)	93.4	102.1	193
pH	7.15	7.04	-

Chest X-ray was done which showed bilateral blunting of costophrenic angle with a normal cardiac silhouette and normal cardiothoracic ratio (Fig. 1). An ultrasonography-guided diagnostic pleural tap was done. There was no evidence of fluid overload, anasarca or systemic diseases like chronic liver disease (CLD), heart failure or nephrotic syndrome. In view of joint pain and pleural effusion RA factor, anti-nuclear antibody (ANA) by hep2 and anti-citrullinated cyclic peptide was sent along with routine investigation. His hemoglobin was 12.6 gm /dL, total leukocyte count was 4690/mm³, platelets were 202000/mm³ and erythrocyte sedimentation rate (ESR) was 54 mm in 1st hour. Quantitative C-reactive protein (CRP) was high (77.6 mg /L). Other investigations were given in Table 1.

Based on the American College of Rheumatology and European League against Rheumatism criteria, a diagnosis of rheumatoid arthritis was made with a disease activity score of 28 and CRP score of 2.06. Serum ANA by hep2 method was negative and other serum markers of connective tissue disorders also came out to be negative including U1Ribonucleo protein. Anti-Sjogren syndrome-related antibody (anti-SSB), C3 and C4 were negative. The patient had no clinical manifestations suggestive of systemic lupus erythematosus (SLE) as per the Systemic Lupus International Collaborating Clinics (SLICCS) classification criteria. Anti-CCP was 108u/ml which was strongly positive. Thus, the possibility of mixed connective tissue disorder

**Figure 2: CECT chest showing bilateral effusion with right lower lobe consolidation.**

(MCTD) or overlap syndromes were ruled out and rheumatoid arthritis was kept. Creatine phosphokinase (CPK) was normal. The pleural fluid analysis was suggestive of exudative neutrophil predominant effusion. Adenosine deaminase (ADA) was 22. Contrast-Enhanced Computed Tomography (CECT) Chest was suggestive of bilateral pleural effusion along with right lower lobe consolidation (Fig. 2).

The patient was treated with naproxen for two weeks and concomitantly started on once a week methotrexate 7.5 mg along with folic acid and sulphasalazine 500 mg bd and followed-up in OPD. Symptoms of the patient improved drastically over the next one month and follow-up chest X-ray was clear with no residual pleural effusion at one month.

DISCUSSION

Pulmonary manifestation is very common in connective tissue disorders. All components of pulmonary tissue can be affected [10]. This includes the respiratory muscles, the pleura, the lung parenchyma, the small airways, the interstitium, and the pulmonary vessels [11]. The pulmonary manifestations of RA are varied, the most common being pleural abnormalities and ILD, while in scleroderma, the interstitial fibrosis and pulmonary hypertension are the most common pulmonary manifestations [12]. In our case also, pleural involvement was there and the patient presented to the hospital with bilateral pleural effusion. Postmortem series suggest that RA-associated pleural disease may occur in between 38 and 73% of patients over a lifetime. Pleural effusions are usually exudate with mixed cell counts and high protein concentration [13-15]. In our case also, the pleural fluid was exudative with mixed cell counts.

The development of the pleural disease may occur along with or even precede the initial signs of joint involvement and may have a genetic predisposition just like other connective tissue diseases [16-

18]. Our patient presented to the medicine OPD with concomitant joint pains and pleuritic chest pain. Thus in our case, the pleural involvement occurred along with musculoskeletal involvement.

Pleural fluid in RA is usually exudative, non-odorous, and often turbid with a low pH (7.3) and glucose level (50 mg/dL or 2.8 mmol/L), whereas more long-standing effusions may become chylous [19,20]. Our case had normal pleural fluid sugars. Rheumatoid factor was positive in pleural fluid in our case. The presence of rheumatoid factor in pleural fluid reflects serum levels and is highly suggestive of an RA-associated etiology, whereas the cytological appearance may be characteristic [21,22]. Evaluation of pleural fluid from both sides was consistent with pleural involvement of RA. Cytological and biochemical profile of the pleural fluid of our patient was consistent with pleural effusion occurring in RA. Cholesterol level in pleural effusion was also elevated which is also consistent with RA as was in our case. In the acute phase of effusion up to 7 to 10 days, pleural fluid may have neutrophil predominance which over time may convert into lymphocytic effusion which also explains the scenario in our patient.

Though multinucleated giant cells are highly specific; however, these are seen in fewer than 50% of the cases [23-26]. It wasn't seen in our patient, the reason of which may attribute to early presentation with pleuritis and pleural effusion.

CONCLUSION

Bilateral pleural effusion in the presence of inflammatory polyarthritis should prompt the clinician to look for connective tissue disorder. Simultaneously, other causes are to be ruled out. RA factor positivity and low complement level in pleural fluid is very consistent with RA associated pleural effusion.

REFERENCES

- Tureson C, Matterson EL. Management of extra-articular disease manifestations in rheumatoid arthritis. *Curr Opin Rheumatol.* 2004;16:206-11.
- Mielants H, Van den Bosch F. Extra-articular manifestations. *Clin Exp Rheumatol.* 2009;27(4 Suppl 55):S56-61.
- Tanoue LT. Pulmonary manifestations of rheumatoid arthritis. *Clin Chest Med.* 1998;19:667-85.
- Habib HM, Eisa AA, Arafat WR, Marie MA. Pulmonary involvement in early rheumatoid arthritis patients. *Clin Rheumatol.* 2011;30:217-21
- King TE. Connective tissue disease. In: Schwarz MI, King TE, editors. *Interstitial Lung Disease.* 3rd edition. Hamilton, Ontario: BC Decker Inc. 1998;451-505.
- Light R. Pleural disease due to collagen vascular disease. In: *Pleural Diseases.* 2nd edition. Philadelphia: Lea and Febiger. 1990;205-15.
- Shiel WO, Prete PE. Pleuro-pulmonary manifestations of rheumatoid arthritis. *Sem Arthritis Rheum.* 1982;58:187
- Naylor B. The pathognomonic cytologic picture of rheumatoid pleuritis. *Acta Cytol.* 1990;34:465-73.
- Walker WC, Wright V. Rheumatoid pleuritis. *Ann Rheum Dis.* 1967;26:467-74.
- Joseph J, Sahn SA. Connective tissue diseases and the pleura. *Chest.* 1993;104:262-70.
- Corcoran JP, Ahmad M, Mukherjee R, Redmond KC. Pleuro-pulmonary complications of rheumatoid arthritis. *Respir Care.* 2014;59:e55-9
- Helmert R, Galvin J, Hunninghake GW. Pulmonary manifestations associated with rheumatoid arthritis. *Chest.* 1991;100:235-8.
- Schwartz MI. Pulmonary manifestations of the collagen vascular diseases. In: Fishman AP, Elias JA, Fishman JA, Grippi MA, Kaiser LR, Senior RM, editors. *Fishman's Pulmonary Diseases and Disorders.* New York: McGraw-Hill. 1998;1115-32.
- Maini RV, Zuaifley N. Rheumatoid arthritis and other synovial disorders. In: Klipped JH, Dieppe PA, editors. *Rheumatology.* 2nd edition. London: Mosby. 1998;215-220.
- Toyoshima H, Kusaba T, Yamaguchi M. Cause of death in autopsied RA patients. *Ryumachi.* 1993;33:209-14.
- Rosenberg EF, Baggenstoss AH, Hensch PS. The causes of death in thirty cases of rheumatoid arthritis. *Ann Intern Med.* 1944;20:903-19.
- Talbott JA, Calkins E. Pulmonary involvement in rheumatoid arthritis. *JAMA.* 1964;189:911-13.
- Horler AR, Thompson M. The pleural and pulmonary complications of rheumatoid arthritis. *Ann Intern Med.* 1959;51:1179-203.
- Walker WC, Wright V. Rheumatoid pleuritis. *Ann Rheum Dis.* 1967;26:467-74.
- Hakala M, Tiilikainen A, Hämeenkorpi R, Ilonen J, Jalava S, Ruuska P, *et al.* Rheumatoid arthritis with pleural effusion includes a subgroup with autoimmune features and HLA-B8, Dw3 association. *Scand J Rheumatol.* 1986;15:290-6.
- Lillington GA, Carr DT, Mayne JG. Rheumatoid pleurisy with effusion. *Arch Intern Med.* 1971;128:764-8.
- Hunder GG, McDuffie FC, Hepper NG. Pleural fluid complement in systemic lupus erythematosus and rheumatoid arthritis. *Ann Intern Med.* 1972;76:357-63.
- Halla JT, Schrohenloher RE, Volanakis JE. Immune complexes and other laboratory features of pleural effusions: a comparison of rheumatoid arthritis, systemic lupus erythematosus, and other diseases. *Ann Intern Med.* 1980;92:748-52.
- Naylor B. The pathognomonic cytologic picture of rheumatoid pleuritis: the 1989 Maurice Goldblatt Cytology award lecture. *Acta Cytol.* 1990;34:465-73.
- Dawson JK, Fewins HE, Desmond J, Lynch MP, Graham DR. Fibrosing alveolitis in patients with rheumatoid arthritis as assessed by high resolution computed tomography, chest radiography, and pulmonary function tests. *Thorax.* 2001;56:622-7.
- Kim EJ, Collard HR, King TE Jr. Rheumatoid arthritis-associated interstitial lung disease: the relevance of histopathologic and radiographic pattern. *Chest.* 2009;136:1397-405.

Funding: None; Conflict of Interest: None Stated.

How to cite this article: Malakar S, Sharma KN, Rana A, Katyayni, Sharma T. Rheumatoid arthritis 1st time presenting with bilateral pleural effusion- a rare presentation. *Indian J Case Reports.* 2019;5(5):404-406.

Doi: 10.32677/IJCR.2019.v05.i05.002