

Case Report

Mucosal prolapse polyp masquerading as malignancy: A rare case report

Aravinth Subramaniam¹, Anandvijai Natesan², Palanivelu Chinnusamy³, Divya Gnanasekaran⁴, Bharathi Bhushan Chittawadagi⁴

From ¹Consultant, Department of Pathology, ²Consultant, ³HOD, Department of Surgical Gastroenterology, ⁴Junior Consultant, Department of Pathology, GEM Hospital and Research Centre, Ramanathapuram, Coimbatore, India.

Correspondence to: Dr Aravinth Subramaniam, Consultant Pathologist, Department of Pathology, 45-A, Pankaja Mill Road, Ramanathapuram, Coimbatore- 641 045, India. E-mail: aravinths1984@yahoo.com.

Received - 4 June 2019

Initial Review - 30 June 2019

Accepted - 25 July 2019

ABSTRACT

Mucosal prolapse polyp is a variant of mucosal prolapse syndrome which comprises of various clinical and histopathological entities, with mucosal prolapse as the underlying pathogenic mechanism. We present the case of a 17-year-old male with a history of mucous discharge per rectum. Colonoscopy revealed ulceroproliferative polypoid growth in distal rectum at 18cm from the anal verge. Polypectomy was done which showed polypoid rectal mucosa with branching and distortion of crypts. Splaying of muscle fibers into lamina propria, mixed inflammatory cell infiltrate and fibrosis was noted. After review of clinical history and histopathology, the patient was diagnosed to have mucosal prolapse polyp, a variant of mucosal prolapse syndrome. Here, we present this rare case to enlighten the importance of identifying mucosal prolapse syndrome as the treatment plan completely changes.

Keywords: Malignant polyp, Mucosal prolapse, Polyps.

Mucosal prolapse polyps are benign polyps which endoscopically mimics malignancy due to ulceration and distorted appearance [1]. Macroscopically, they resemble inflammatory polyps, adenomatous polyps or carcinoma. Microscopically, these lesions are characterized by hyperplastic distended glands with an extension of muscle fibers into lamina propria, surface ulceration, and regenerative changes [2,3]. We present a rare case of mucosal prolapse polyp since this lesion closely resembled malignant lesion both endoscopically and in gross examination.

CASE REPORT

A 17-year-old male presented with complaints of mucous discharge per rectum for two years. He gave a history of mass descending per rectum for one month which was reducible. Episodes of bleeding per rectum were present for the last five days. There were no complaints on the loss of weight, appetite or family history of colorectal cancer.

On examination, the patient was comfortable, afebrile and no generalized lymphadenopathy was present. The patient neither had anemia nor jaundice. The pulse rate was 82/min and blood pressure was 110/70mm Hg. The abdomen was soft with no palpable mass. On rectal examination, multiple rectal polyps were present.

Colonoscopy done at our institution showed an ulceroproliferative growth involving distal rectum. Blood

investigation showed hemoglobin of 11g/dl and other laboratory investigations were not contributory. Ultrasound abdomen showed mid-rectal wall thickening. Computerized tomography (CT) abdomen showed circumferential rectal wall thickening. No lymph nodes were identified. For better visualization of the polyp under spinal anesthesia, the patient was placed in a lithotomy position. Retractor placed and the anal canal was visualized. Multiple crowded polyps were seen in the rectum starting at the dentate line and extending proximally beyond 10cm as shown in Fig. 1. Polyps were excised at the base with harmonic scalpel and hemostasis was achieved.

Gross examination showed multiple polyps ranging from 1-4cm in diameter. They were tan-brown in color. Histopathological examination showed polypoid fragments of rectal mucosa with surface ulceration, branching and distortion

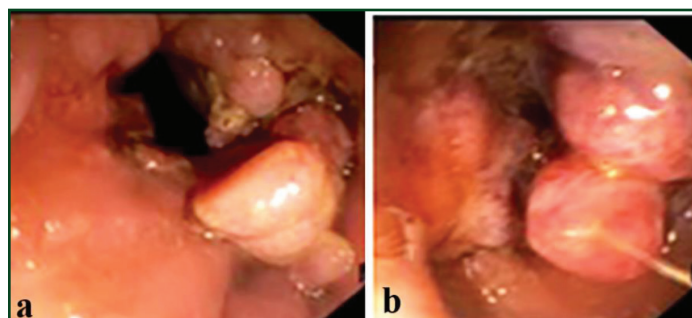


Figure 1: Colonoscopy picture showing multiple ulceroproliferative polypoid lesion.

Table 1: Mucosal prolapse polyps presenting as polyps

	Age (year)	Gender	No of Polyps	Histology	Histopathological differential diagnosis
Tendler <i>et al</i> ⁴	33	M	2	NS	NS
Tendler <i>et al</i> ⁴	45	M	6	NS	NS
Tendler <i>et al</i> ⁴	54	M	5	NS	NS
Tendler <i>et al</i> ⁴	46	M	6	NS	NS
Tendler <i>et al</i> ⁴	60	F	3	NS	NS
Tendler <i>et al</i> ⁴	61	F	3	NS	NS
Tendler <i>et al</i> ⁴	71	M	4	NS	NS
Chetty <i>et al</i> ⁶	48	M	30	Inflammatory cap polyps & inflammatory myoglandular polyps	NS
Jansen <i>et al</i> ¹⁹			NS	NS	Peutz-Jeghers polyp
Daniel <i>et al</i> ²⁰	14	M	Multiple	Inflammatory (cap) polyps	Inflammatory/ juvenile/ hamartomatous polyposis
Daniel <i>et al</i> ²⁰	13	M	Multiple	Inflammatory pseudopolyps	Adenomatous/ hyperplastic polyposis
Brossens <i>et al</i> ²¹	51	F	70	Inflammatory myoglandular polyps	Adenomatous/ hyperplastic polyposis
Present paper	17	M	Multiple	Mucosal prolapse polyp	Adenomatous polyposis

NS: not stated

of crypts as shown in Fig. 2. Strands of smooth muscle fibers lying perpendicular to the colonic crypts, infiltrates of neutrophils, lymphocytes, plasma cells and areas of fibrosis are seen (Fig. 3). Correlating the clinical and histopathologic features including a history of reducible mass per rectum, polyps in rectum, lamina propria smooth muscle proliferation and absence of malignant changes, these polyps were diagnosed as mucosal prolapse polyp.

DISCUSSION

Mucosal prolapse syndrome includes various pathological disease of the rectum with mucosal prolapse being the underlying pathogenesis for all these diseases. It includes rectal prolapse, solitary rectal ulcer syndrome (SRUS), proctitis cystica profunda, inflammatory cloacogenic polyps and inflammatory myoglandular polyps [4-7]. Histopathological features depend on their varying stages of development. Separate categorization of these entities is difficult [6]. Hence, it was proposed that these terminologies can be grouped under the term mucosal prolapse syndrome.

Mucosal prolapse syndrome/ Solitary Rectal Ulcer Syndrome (SRUS) present as an ulcerative, polypoidal or flat lesion [1].

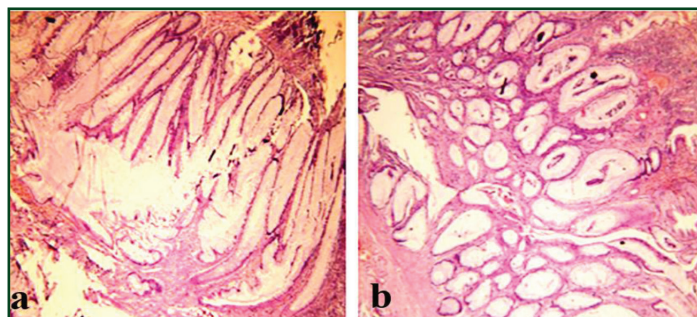


Figure 2: Low power view 10X of (a) hypermucinous appearance with villous configuration; (b) distended crypts

There are only a few cases of rectal mucosal prolapse presenting as polyposis (Table. 1). A study conducted by Martin *et al* found that only 35% of SRUS present as solitary ulceration, 25% with broad-based polyps, 22% with multiple ulcers and 18% with patchy granular hyperemic rectal mucosa [8]. Tjandar *et al* described that 44% of cases presented as polypoid SRUS [9]. They are more common in young females. Patients generally present with mucous or blood in stools, pain or discomfort during defecation, alternating diarrhea and constipation [10]. Approximately, 30% of patients had constipation and they acknowledge rectal digitation [11]. Our patient had mucous followed by blood in the stool.

Pathogenesis of mucosal prolapse syndrome is a malfunction of the puborectalis muscle which leads to excessive straining during defecation [12]. Straining leads to mucosal prolapse that ultimately may ulcerate and form polypoidal masses. Endoscopically, these polypoid lesions mimic carcinoma [12,13,14]. The characteristic findings are fibromuscular hyperplasia of the lamina propria, splaying of smooth muscle fibers which are seen perpendicular to the colonic crypts [10]. Lamina propria can be edematous and show an increased number of fibroblasts [15,16]. Surface epithelium can be inflamed and ulcerated. Ischemic injury leads to pseudomembrane formation [17].

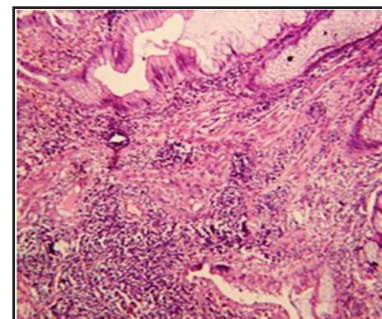


Figure 3: High power view (40X) showing smooth muscle lying perpendicular to colonic crypts

Mucosal prolapse polyp closely mimics adenoma. In polypoid cases, mucosa assumes a villiform configuration that can look similar to a villous adenoma [16]. Serration and hyperplastic changes of the mucosa, crypt branching, hypermucinous appearance of the epithelium have been reported in all cases of mucosal prolapse. These regenerative hyperplastic changes are seen in a polypoid variant of SRUS [18]. Careful examination is needed to differentiate the two. Hence Pathologist should determine whether the cytological changes are reactive or dysplastic. Peutz Jeghers polyp also pretends to be SRUS. The former shows branching or arborizing architecture and the later shows smooth muscle proliferation [19]. Inflammatory bowel disease (IBD) forms a differential diagnosis for ulcerated SRUS. Presence of smooth muscle between the crypts helps to differentiate from IBD [10].

CONCLUSION

To conclude, we present a case of mucosal prolapse polyp, a variant of mucosal prolapse syndrome which clinically and endoscopically mimicked malignancy. However, a detailed history and histopathological examination of multiple sections can rule out the possibility of malignancy. Therefore, despite mucosal prolapse polyp being a rare entity, it should be definitely considered in the differential diagnosis of polypoid rectal masses of young patients as the management of these benign lesions majorly differs from other lesions.

REFERENCES

1. Libanio D, Meireles C, Afonso LP, Henriqueb R, Pimentel-Nunesa P, Dinis-Ribeiroa M. Mucosal prolapse Polyp mimicking rectal malignancy: A Case Report. *GE Port J Gastroenterol.* 2016;23:214-7.
2. Bogomoletz WV. Solitary rectal ulcer syndrome. *Mucosal prolapse syndrome.* *Pathol Annu.* 1992;27:75-86.
3. Franzin G, Fratton A, Manfrini C. Polypoid associated with diverticular disease of the sigmoid colon. *Gastrointest Endosc.* 1985;31:196-9.
4. Tendler DA, Aboudola S, Zacks JF, O'Brien MJ, Kelly CP. Prolapsing mucosal polyps: an under-recognized form of colonic polyp- a clinicopathologic study of 15 cases. *Am J Gastroenterol.* 2002;97:370-6.

5. du Boulay CE, Fairbrother J, Isaacson PG. Mucosal Prolapse syndrome- a unifying concept for solitary rectal ulcer syndrome and related disorders. *J Clin Pathol.* 1983;36:1264-8.
6. Chetty R, Bhathal PS, Slavin JL. Prolapse – induced inflammatory polyps of the colorectum and anal transitional zone. *Histopathology.* 1993;23:63-7.
7. Bhathal PS, Chetty R, Slavin JL. Myoglandular polyps. *Am J Surg Pathol.* 1993;17:852-3.
8. Martin CJ, Parks TG, Biggart JD. Solitary Rectal Ulcer Syndrome in Northern Ireland. 1971-1980. *Br J Surg.* 1981;68:744-7.
9. Tjandra JJ, Fazio VW, Church JM, Lavery IC, Oakley JR, Milsom JW. Clinical conundrum of solitary rectal ulcer. *Dis Colon Rectum.* 1992;35:227-34.
10. Robert D, Odze, John R Goldblum. *Surgical Pathology of the GI Tract, Liver, Biliary Tract and Pancreas Saunders Elsevier.* 2009;392-3.
11. Chiang JM, Changchien CR, Chen JR, Solitary rectal ulcer syndrome, an endoscopic and histopathological presentation and literature review. *Int J Colorectal Dis.* 2006;21:348-56.
12. Madigan MR, Morson BC. Solitary ulcer of the rectum. *GUT.* 1969;10:871-81.
13. Rutter KR, Riddell RH. The solitary ulcer syndrome of the rectum. *Clin Gastroenterol.* 1975;4:505-30.
14. Edden Y, Shih SS, Wexner SD. Solitary rectal ulcer syndrome and stercoral ulcers. *Gastroenterol Clin North Am.* 2009;38:541-5.
15. Ball CG, Dupre MP, Falck V, Hui S, Kirkpatrick AW, Gao ZH. Sessile serrated polyp mimicry in patients with solitary rectal ulcer syndrome: is there evidence of preneoplastic change? *Arch Pathol LAB Med.* 2005;129:1037-40.
16. Mathialagan R, Turner MJ, Gorard DA. Inflammatory cloacogenic polyp mimicking anorectal malignancy. *Eur J Gastroenterol Hepatol.* 2000;12:247-50.
17. B Singh, NJ Mc C Mortensen, BF Warren. Histopathological mimicry in mucosal prolapse. *Histopathology.* 2007;50:97-102.
18. Yamagiwa H. Protruded variants in solitary rectal ulcer syndrome of the rectum. *Acta Pathol J.* 1988;38:471-8.
19. Jansen M, de Leng WW, Baas AF, Myoshi H, Mathus-Vliegen L, Taketo MM, *et al.* Mucosal prolapse in the pathogenesis of Peutz-Jeghers polyposis. *GUT.* 2006;55:1-5.
20. Daniel F, El Braks R, Grandjouan S, Villet R, Lechaux JP, Vuong PN, *et al.* Recto-sigmoid polyposis revealing rectal prolapse in two young patients. *Int J Colorectal Dis.* 2006;21:192-4.
21. Brosens LAA, Montgomery EA, Bhagavan BS, Offerhaus GJA, Giardiello FM. Mucosal prolapse syndrome presenting as rectal polyposis. *J Clin Pathol.* 2009;62:1034-6.

Funding: None; Conflict of Interest: None Stated.

How to cite this article: Subramaniam A, Natesan A, Chinnusamy P, Gnanasekaran D, Chittawadagi BB. Mucosal prolapse polyp masquerading as malignancy: A rare case report. *Indian J Case Reports.* 2019;5(4):360-362.

Doi: 10.32677/IJCR.2019.v05.i04.022