

## Congenital epidermoid cyst of penis with hypospadias: A case report

Akhilesh Kumar Patel<sup>1</sup>, Nakul Kumar Rathore<sup>1</sup>, Ankur Deshwali<sup>1</sup>, Abhishek Singh<sup>1</sup>, Manoj Kela<sup>2</sup>, Rajesh Sharma<sup>2</sup>, Sanjay Prasad<sup>3</sup>, Advait Prakash<sup>4</sup>

From <sup>1</sup>Resident, <sup>2</sup>Professor, <sup>3</sup>Associate Professor, Department of Surgery, <sup>4</sup>Associate Professor, Department of Paediatric Surgery, S.A.I.M.S. Medical College, Indore, Madhya Pradesh, India.

**Correspondence to:** Dr. Akhilesh Kumar Patel, Department of Surgery, Room No -16, Siddhant Hostel, Saims Campus, Indore - 453555, Madhya Pradesh, India. E-mail: [dr.akhi007@gmail.com](mailto:dr.akhi007@gmail.com)

Received - 29 March 2019

Initial Review - 15 April 2019

Accepted - 21 June 2019

### ABSTRACT

The epidermoid cysts are the most common cutaneous cysts and may develop from any parts of the human body. Primary epidermoid cyst with hypospadias in the penis is very rare. Here, we present the case of a slow growing, mobilized; non-tender frenulum of the penis mass in a 44-year-old male patient. Complete excision of the cyst was performed under spinal anesthesia. Histopathological examination confirmed the mass to be an epidermoid cyst. Care must be given during examination to rule out another entity. If there is any indication, complete excision and hypospadias repair is the best treatment.

**Keywords:** *Coronal hypospadias, Epidermoid cyst, Median raphe cyst.*

The epidermoid cysts are the most common cutaneous cysts and may develop from any parts of the human body. However, the occurrence of epidermoid cyst in the penis is uncommon and only a small number of cases have been reported. In fact, only a few cases of penile localization have been reported in the literature so far, the vast majority being congenital or idiopathic lesions diagnosed during childhood [1]. Therefore, it has been suggested they develop from abnormal closure of the median raphe during embryogenesis [2,3].

We presented the case of a slow-growing penile epidermoid cyst located on frenulum of the penis with coronal hypospadias that developed over many years period. From our knowledge, this

is the first documented case of the penile epidermoid cyst with hypospadias in India.

### CASE REPORT

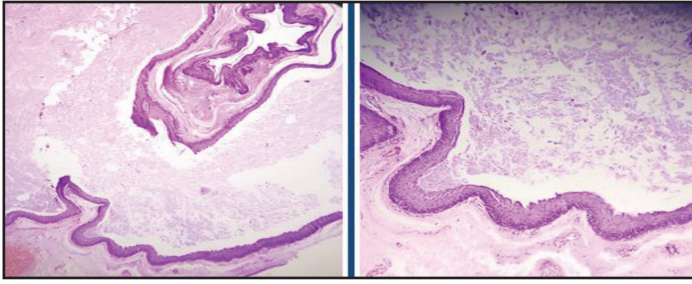
A 44-year-old man came to the surgery clinic with a complaint of slow-growing penile swelling. The penile mass was noticed at the age of 6 years by the parents during bathing. The subcoronal hypospadias was also present since birth. The patient was married and has 2 children. The medical history including urinary tract infection, dysuria, hematuria, trauma was otherwise unremarkable.

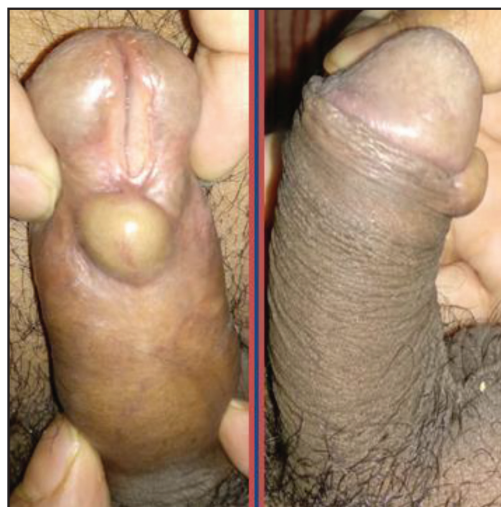

Figure 1: Preoperative image showing a mobile, painless mass on the ventral aspect of the frenulum of the penis with coronal hypospadias.

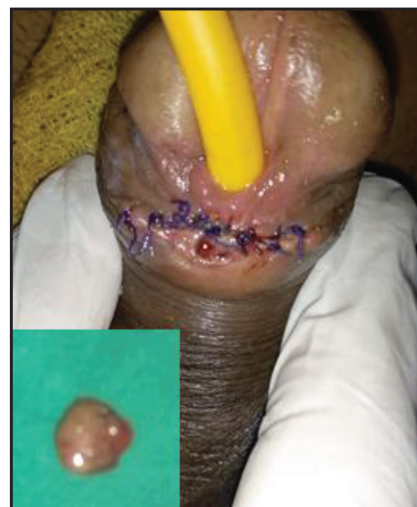

Figure 2: Complete excision of the cyst was performed under spinal anesthesia (Gross appearance of the cyst).



**Figure 3: Histopathology of the mass shows that the lining of the cyst is composed of an epithelium which is flattened and contains a granular layer of keratohyaline granules.**

On examination, the vitals were stable. Thorough physical examination of the systems was unremarkable except for the penile swelling and no chordae. Local examination of the lesion revealed a mobile, painless mass on the ventral aspect of the frenulum of the penis with coronal hypospadias (Fig. 1).

Blood investigations such as complete blood counts, hemoglobin were normal. Blood examination for liver (total bilirubin, aspartate aminotransferase, alanine aminotransferase, alkaline phosphatase and albumin) and kidney function (urea, creatinine) were otherwise normal, as well as a urinalysis. Penile ultrasound revealed the existence of a well-defined cystic appearance which was around 2 cm in diameter. Moreover, the cyst was shown to be separated from the erectile tissue as well as urethra.

Complete excision of the cyst was performed under spinal anesthesia and was continued with circumcision under the patient's agreement (Fig. 2). Circumcision without repair of hypospadias was performed. Grossly, the cyst showed a clear jelly-like material. The histopathology report of the specimen revealed subcutaneous cyst lined by stratified squamous epithelium (Fig. 3). Based on the clinical examination and histopathological reports, a final diagnosis of the penile epidermoid cyst was made. The patient was recalled after 1 month for follow-up and on a subsequent follow-up visit, the patient was found asymptomatic.

## DISCUSSION

The epidermoid cyst has been used interchangeably with epidermal cyst and epidermal inclusion cyst [4]. Even though the cause of penile epidermoid cyst is still unknown, previous studies have reported that this cyst may emerge from abnormal closure of the median raphe during embryo or could be acquired following implantation of the external entity, such as injection of epidermal fragments [5]. Some articles reported that median raphe cyst is a different entity from the epidermoid cyst. Moreover, they believe that median raphe cysts are the sequelae of a fault during embryologic development, particularly in male genitalia [6].

Considering the location, the lesion in our report comes from the median raphe.

Epidermoid cysts in the penis may occur in different size and diameter. They usually appear solitary; however, they could also be having multiple appearances [7]. The differential diagnosis of penile epidermoid cyst includes steatocystoma, dermoid cyst, teratoma, urethro-cutaneous fistula, and urethral diverticula [6]. Although rare, the extension of the cyst into the pelvis has been reported [8]. No malignancy has been reported so far involving the penile epidermoid cyst. A thorough physical examination, as well as ultrasonography examination, are necessary to establish the diagnosis and eliminate other entities. The indications of treatment for this lesion include urinary tract obstruction, secondary infection, and pain during intercourse, or cosmetic consideration [6]. The best treatment for this lesion is hypospadias repair with complete excision as aspiration, simple drainage, or even partial excision may lead to the risk of recurrence [6].

## CONCLUSION

The occurrence of primary epidermoid cyst over the ventral aspect of the penis is extremely rare. Most of the reported cases occurred in children, thus suggesting the etiology of 'primary' penile epidermoid cysts being embryonic developmental defects, particularly abnormal closure of the median raphe. To the best of our literature knowledge; this is the first case of the primary penile epidermoid cyst with hypospadias in India.

## REFERENCES

1. Suwa M, Takeda M, Bilim V, Takahashi K: Epidermoid cyst of the penis: a case report and review of the literature. *Int J Urol.* 2000;7:431-433.
2. López-Ríos F, Rodríguez-Peralto JL, Castaño E, Benito A: Squamous cell carcinoma arising in a cutaneous epidermal cyst: case report and literature review. *Am J Dermatopathol.* 1999;21:174-177.
3. Rattan J, Rattan S, Gupta DK: Epidermoid cyst of the penis with extension into the pelvis. *J Urol.* 1997;158:593.
4. Kumaraguru V, Prabhu R, Kannan NS. Penile epidermal cyst: a case report. *J Clin Diagn Res.* 2016;10:PD05-6.
5. Khanna S. Epidermoid cyst of the glans penis. *Eur Urol.* 1991;19:176-177.
6. Aslan Y, Balci M, Atan A. Idiopathic penile epidermoid cyst in a young patient: three year follow up. *Eur J Surg Sci.* 2011;2:16-18.
7. Okumura A, Takagawa K, Fuse H. Penile epidermoid cyst consisted of multiple foci: a case report. *J Cosmetics Dermatol Sci Appl.* 2012;2:214-215.
8. Salder B, Greenfield SP, Wan J, Glick PL. Intrascrotal epidermoid cyst of with extension into the pelvis. *J Urol.* 1995;153:1265-1266.

*Funding: None; Conflict of Interest: None Stated.*

**How to cite this article:** Patel AK, Rathore NK, Deshwali A, Singh A, Kela M, Sharma R. *et al.* Congenital Epidermoid Cyst of Penis with Hypospadias: A Case Report. *Indian J Case Reports.* 2019;5(4):315-316.

Doi: 10.32677/IJCR.2019.v05.i04.005