

Case Report

Emphysematous cholecystitis with perforation and biliary peritonitis

Awaji Qasem Al-Nami, Liaqat Ali Khan, Husain Al-Gasser, Said Samir Said Qeshta, Rashid Abdul-Manan, Yahya Atlawy, Musa Tumaihi, Essa Ibrahim Zakri

Department of General and Laparoscopic Surgery, Sabya General Hospital, Jazan, Saudi Arabia

Correspondence to: Dr Liaqat Ali Khan, Department of General & Laparoscopic Surgery, Sabya General Hospital Jazan, Kingdom of Saudi Arabia. E-mail: drliaqatalikhan@yahoo.com.

Received - 13 March 2019

Initial Review - 28 March 2019

Accepted - 19 April 2019

ABSTRACT

Emphysematous cholecystitis (EC), uncommon but potentially fatal sequelae of acute cholecystitis mainly seen in old-aged patients with high mortality rate, caused by secondary infection of gall bladder with gas-forming enteric organisms. Herein, we report a case of emphysematous gangrenous cholecystitis with perforation and biliary peritonitis in a 76-years-old non-diabetic lady that was successfully managed by surgical intervention coupled with medical. The report of this case highlights the risk of missing this extremely rare but potentially fatal condition once the patient presents in late-stage with concurrent complications like perforation and peritonitis. Therefore, prompt diagnosis and early surgical intervention is imperative are imperative to avoid undesired outcomes.

Keywords: Biliary, Emphysematous cholecystitis, Gall bladder, Peritonitis.

Emphysematous cholecystitis (EC) is an uncommon but life-threatening form of acute cholecystitis characterized by the presence of intramural and/or intraluminal gas caused by gas-forming enteric organisms in the gall bladder (GB) that may develop into gangrene or perforation of the GB. Approximately, 1-3% of individuals with acute cholecystitis (AC) may develop EC. More susceptible individuals include men (male: female ratio is 7:3), older age, recurrent gallstones and cholecystitis, co-existing conditions like diabetes mellitus (30-75%), cardiovascular diseases, and weak immune system [1, 2]. The etiology of the emphysematous cholecystitis is controversial, but it is considered to be due to ischemia of the gallbladder from primary vascular compromise, with a secondary proliferation of gas-forming enteric bacteria [3].

Herein, we report the case of a 76-years-old non-diabetic elderly patient with potentially fatal combinations of emphysematous gangrenous cholecystitis with perforation and concomitant peritonitis. The patient's relevant history with signs and symptoms, coupled with radiological findings of gas in GB lumen with impending perforation, necessitates for prompt surgical intervention as to avoid the undesired outcome of GB perforation and peritonitis as seen in the case.

CASE REPORT

A 76-years-old native Arabian lady presented to our emergency department (ED) with a 4 days history of dull abdominal pain, fever, and vomiting. The patient's history was suggestive of endoscopic retrograde cholangiopancreatography (ERCP) for

common bile duct (CBD) stone two months ago in a private hospital, which were removed successfully as per procedure notes. She has a medical history of hypertension (HTN) and ischemic heart disease (IHD) taking antihypertensives and cardioprotective medications but no history of diabetes.

Clinical examination revealed a toxic, pyrexial patient (Temp.39°C) with icterus and signs of peritoneal irritations. Her vitals showed the pulse rate of 96 beats/min, blood pressure of 105/65 mmHg, and respiratory rate of 28/min.

Primary laboratory workup shows; Total leukocyte count (TLC) $29 \times 10^3/\mu\text{L}$, Haemoglobin 8.7g/dL, Haematocrit 28.5%, Platelets $786 \times 10^3/\mu\text{L}$, Glucose 6.4mg/dL, blood urea nitrogen (BUN) 11.38mg/dL, Creatinine 69.8mg/dL, Sodium (Na) 149.3mEq/L, Potassium (K) 4.56mEq/L, alkaline phosphatase (ALP) 198U/L, aspartate aminotransferase (AST) 55U/L, alanine aminotransferase (ALT) 27U/L, TBil 19.4mg/dL, DBil 6.2mg/dL. Ultrasonography of the abdomen shows thick walled gall bladder (GB) measuring 8X4.4cm with a mild amount of mud and multiple stones. Common bile duct (CBD) measuring 8.4mm but the wall of CBD appears thick. Intrahepatic Biliary Radicals (IHBR) were normal.

Non-contrast computed tomography (CT) findings suggests localized sizable heterogeneous ill-defined lesion of mixed fluid attenuation with thick irregular wall, measuring about 6.6x6 cm noted in the expected area of GB and GB bed associated with multiple intraluminal variable sizes hyper-dense stones (Figure 1 - green circle), intraluminal gas (orange arrow), thick wall GB (blue arrow) and focal disruption of GB wall at 3 to 6 o'clock position consistent with impending rupture (Figure 2 - yellow

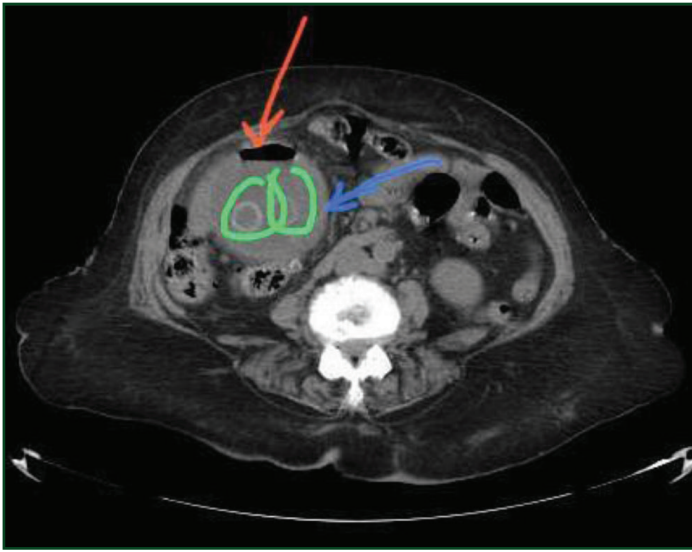


Figure 1: Non-contrast CT image showing orange arrow gas in GB lumen, green circle gall stones and blue arrows shows thicker GB wall.

circle) with focal sub-hepatic fat stranding and fine irregularity of GB-liver borders. These findings are highly suggestive of GB abscess due to acute calculous cholecystitis or ascending inflammation with a mild extension of the inflammatory process to near liver parenchyma and sub-hepatic mesenteric fat.

The patient was prepared and exploratory laparotomy initiated. Intraoperative findings were; perforated gangrenous GB with multiple gall stones inside it. Pus, (about 400-500ml) in abdomen, prehepatic, Morison pouch and pelvis was present, suggestive of preoperative perforation. Phlegmon area at the level of cystic duct was also seen. Sub-total cholecystectomy via open procedure was performed with removal of ≥ 300 stones of different sizes (Figure-3). Bile and pus culture from peritoneal cavity taken intra-operatively demonstrates *Clostridium Perfringens*.

Pre and Post-operatively, the patient was managed as per surgical unit protocol. The patient did well during the hospital stay and discharged on the 12th postoperative day with a week



Figure 3: More than 300 stones of different sizes removed from GB via open cholecystectomy

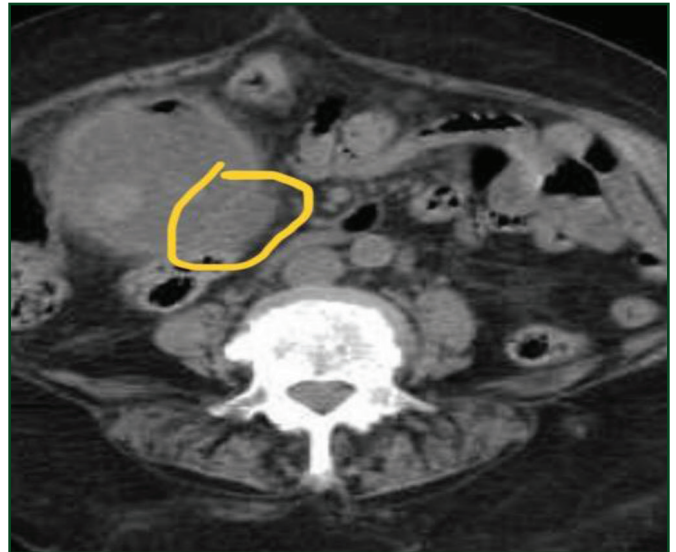


Figure 2: Non-contrast CT image showing yellow circle at this slice shows focal disruption of wall at 3 to 6 o'clock position consistent with impending rupture.

later follow-up. The patient was asymptomatic having a healthy surgical wound and soft abdomen.

DISCUSSION

EC is a life-threatening condition characterized by the presence of gas in the GB and/or biliary tree caused by gas-forming enteric organisms. In 1901, Stolz [4] reported the first case at autopsy and described EC as the presence of air within the GB and/or biliary tree while having no biliary system communication with the gastrointestinal tract (GIT). Deręowska-Cylke M *et al.* recently reported a case of EC associated with retroperitoneal gas gangrene and emphysematous pancreatitis, which may be due to spread of infection both to the peritoneal cavity and retroperitoneum [5]. Pneumoperitoneum and retropneumoperitonum may be seen in EC with or without macroscopic GB perforation and considered an extensive infectious form of EC [6, 7].

Most common microorganisms cultured in EC are *Clostridium perfringens* and *Escherichia coli*, although others such as *Proteus vulgaris*, *Aerobacter aerogenes*, *Staphylococcus*, *Streptococcus*, *Klebsiella*, and *Bacteroides fragilis* have been involved [8, 9]. Based on the air distribution in GB and/or the biliary system, EC is staged as stage 1 (intraluminal air in the GB), stage 2 (Intramural air in the GB), stage 3 (air in the pericholecystic tissue) [10].

Commonly affected patients are diabetic, aged 50-70 years and more commonly having peripheral vascular disease [11] and more often males than females. Approximately, 40% of patients with EC have gall stones, compared to 90% in acute cholecystitis [12], while our patient was non-diabetic and having ≥ 300 stones of different sizes. The patient may present with, nausea, vomiting, fever and right upper quadrant pain. Radiography, ultrasonography, and computed tomography of the abdomen can provide much information for early diagnosis of this condition [8]. The mortality rate of uncomplicated AC is approximately

1.4%, while that of EC is 15-20% due to the increased incidence of gallbladder wall gangrene and perforation [13].

The differential diagnosis of gas in GB include hepatic abscess, overlying bowel gas, incompetent sphincter of Oddi, cholangitis, retroperitoneal air, focal biliary lipomatosis, enterobiliary surgical anastomosis, and spontaneous internal biliary fistula [7,10,14].

Treatment options include conservative management, hyperbaric oxygen therapy, percutaneous and laparoscopic cholecystectomy [12,13,15]. Conservative management is usually opted for the milder condition while minimally invasive approach as laparoscopic cholecystectomy is controversial, as some consider it to be a safe procedure in stable patients while others do not prefer the procedure due to GB wall instability [16,17]. Percutaneous drainage may be opted in an older, critically ill and unstable patient with a calculous cholecystitis [17].

The patient presenting to an emergency department (ED) with signs of peritoneal irritation is mostly in an unstable state and need emergency exploratory laparotomy, as the first treatment of choice, followed by cholecystectomy under a correct intra-operative diagnosis, as opted for our patient.

CONCLUSION

Patients with complications of EC such as GB perforation and biliary peritonitis is seldom reported in the literature as our case is unique in this regard with combinations of such potentially fatal complications. Surgeons must be vigilant, as there is a greater risk of missing this horrendous condition once the patient presents in late stage and early diagnosis and prompt surgical intervention is imperative to avoid undesired outcomes.

REFERENCES

1. Mentzer RM, Golden GT, Chandler JG, *et al.* A comparative appraisal of emphysematous cholecystitis. *Am J Surg* 1975;129:10-5.
2. Ogawa A, Shikata K, Uchida HA, *et al.* Case of emphysematous cholecystitis in a patient with type 2 diabetes mellitus associated with schizophrenia. *J Diabetes Invest* 2012;3:534-5.
3. Chiu HH, Chen CM, Mo LR. Emphysematous cholecystitis. *Am J Surg* 2004;188:325-6.

4. Stolz A. Ubergasbildung in derGollinweger. *Arch Pathol Anat* 1901;165: 90-123.
5. Deręowska-Cylke M, Palczewski P, Pacholczyk M, Jonas M, Cylke R, Kosieradzki M *et al* "A deceptive case of emphysematous cholecystitis complicated with retroperitoneal gangrene and emphysematous pancreatitis: clinical and computed tomography features." *Polish Journal of Radiology* 2019;84:41-5.
6. Yagi Y, Sasaki S, Terada I, Yoshikawa A, Fukushima W, Kitagawa H, Fujimura T, Izumi R, Saito K. Massive pneumoretroperitoneum arising from emphysematous cholecystitis: a case report and the literature review. *BMC Gastroenterol* 2015;15:114.
7. Miyahara H, Shida D, Matsunaga H, Takahama Y, Miyamoto S. Emphysematous cholecystitis with massive gas in the abdominal cavity. *World J Gastroenterol* 2013;19:604-6.
8. Sunnapwar A, Raut AA, Nagar AM, Katre R. Emphysematous cholecystitis: imaging findings in nine patients. *Indian J Radiol Imaging* 2011;21:142-6.
9. Papavramidis TS, Michalopoulos A, Papadopoulos VN, *et al*: Emphysematous cholecystitis: a case report. *Cases J* 2008;1:73.
10. Gill KS, Chapman HA, Weston MJ. Changing face of emphysematous cholecystitis. *Br J Radiol* 1997;70:986-91.
11. Choi HS, Lee YS, Park SB, *et al.* Simultaneous emphysematous cholecystitis and emphysematous pancreatitis: a case report. *Clin Imaging* 2010;34: 239-41.
12. Moanna A, Bajaj R, del Rio C: Emphysematous cholecystitis due to salmonella derby. *Lancet Infectious Dis* 2006;6:118-120.
13. Wu JM, Lee CY, Wu YM. Emphysematous cholecystitis. *Am J Surg* 2010;200:53-4.
14. Grayson DE, Abbott RM, Levy AD *et al.* Emphysematous infections of the abdomen and pelvis: A pictorial review. *Radiographics* 2002;22:543-61.
15. Katagiri H, Yoshinaga Y, Kanda Y, Mizokami K, Mizokami K. Emphysematous cholecystitis successfully treated by laparoscopic surgery. *J Surg Case Rep* 2014;4:rju027.
16. Bouras G, Lunca S, Vix M, Marescaux J: A case of emphysematous cholecystitis managed by laparoscopic surgery. *J Soc Laparoendoscopic Surg* 2005;9:478-480.
17. Safioleas M, Stamatakos M, Kanakis M, *et al*: Soft tissue gas gangrene: a severe complication of emphysematous cholecystitis. *Tohoku J Exp Med* 2007;213:323-8.

Funding: None; Conflict of Interest: None Stated.

How to cite this article: Al-Nami AQ, Khan LA, Al-Gasser H, Qeshta SS, Abdul-Manan R, Atlawy Y, Tumaihi M, Zakri EI. Emphysematous cholecystitis with perforation and biliary peritonitis. *Indian J Case Reports*. 2019;5(3): 222-224.

Doi: 10.32677/IJCR.2019.v05.i03.008