

## Case Report

# Hyperacute gastric perforation: A rare presentation in the post-operative period

Shailesh Kumar<sup>1</sup>, Mohammad Sarwar Alam<sup>2</sup>, Shazid Akbal<sup>3</sup>, Tayod Kumar Chaudhary<sup>3</sup>

From <sup>1</sup>Professor, <sup>2</sup>Senior Resident, <sup>3</sup>Junior Resident, Department of Surgery, Dr. Ram Manohar Lohia Hospital and Post Graduate Institute of Medical Education and Research, New Delhi, Delhi, India

**Correspondence to:** Dr. Mohammad Sarwar Alam, Room No. 101A, Office of H.O.D, Department of Surgery, 1<sup>st</sup> Floor, OPD Building, Dr. Ram Manohar Lohia Hospital and Post Graduate Institute of Medical Education and Research, New Delhi- 110001, Delhi, India. E-mail: sarwar1331@gmail.com

Received - 10 March 2019

Initial Review - 26 March 2019

Accepted - 13 April 2019

### ABSTRACT

Stress-related gastric ulceration and their perforation have become history because of the research and development of highly effective anti-ulcer drug and their affordability and availability across our country. We present an interesting and thought-provoking case of a 46-year-old female, with stress-related gastric perforation who developed the complication in a span of only 2 days of physiological insult.

**Keywords:** gastric ulceration, perforation, Stress.

**S**tress-related gastric ulceration and their perforation have become history because of the research and development of highly effective anti-ulcer drug and their affordability and availability across our country [1]. It had been documented to occur after many major physiologic insults including major operative procedures, major burns, CNS injury, during critical illness and while on steroidal therapy a decade earlier [2].

Stress ulcer is stress induced gastritis or gastropathy where the gastric and sometimes esophageal or duodenal mucosal barrier is disrupted secondary to severe acute illness [3]. Its presentation varies from asymptomatic superficial erosive gastritis to overt clinically significant gastrointestinal (GI) bleeding and perforation [4]. Perforation induced peritonitis is a known common surgical emergency all over the world that occurs in about 2% - 14% of patients [5, 6]. We present an interesting and thought-provoking a case of stress-related gastric perforation who developed the complication in a span of only two days of physiological insult.

### CASE REPORT

A 46-year female was admitted in the ENT department for swelling of size 3x3 cm in the left parotid region. The swelling was firm, non-tender, non-mobile with normal overlying skin. On examination, her pulse rate was- 84/min, B.P- 120/80 mmHg, the chest was bilateral clear, S1- S2 were audible on auscultation with no added sounds, the abdomen was soft on per abdomen examination and bowel sounds were present. The patient had no history of non-steroidal anti-inflammatory drugs (NSAID) intake, smoking, and alcohol intake. The fine needle aspiration and cytology (FNAC) of the swelling revealed pleomorphic adenoma with mild cystic changes. Contrast-enhanced computed tomography (CECT) of the neck showed mildly enhancing lobulated mass lesion of 3.7x2.8x1.8 cm in the substance of parotid

gland involving superficial and deep lobe suggestive of neoplastic etiology. The patient underwent total parotidectomy under general anesthesia and has advised antibiotics and proton pump inhibitor (PPI) pantoprazole 40 mg intravenous per day, post-operatively.

On the 2<sup>nd</sup> postoperative day, the patient complained of pain in the abdomen with features suggestive of peritonitis. On clinical examination, pulse was rapid 120/min; BP was 90/60 mm Hg with cold and clammy skin. Per abdominal test showed abdominal distension with guarding and rigidity and generalized tenderness. Bowel sounds were absent on auscultation. Per rectal examination revealed normal anal tone with empty rectal mucosa.

X-ray of the abdomen erect revealed gas under the right dome of the diaphragm while the ultrasound (USG) of the abdomen suggested bowel perforation. Laboratory findings showed mild

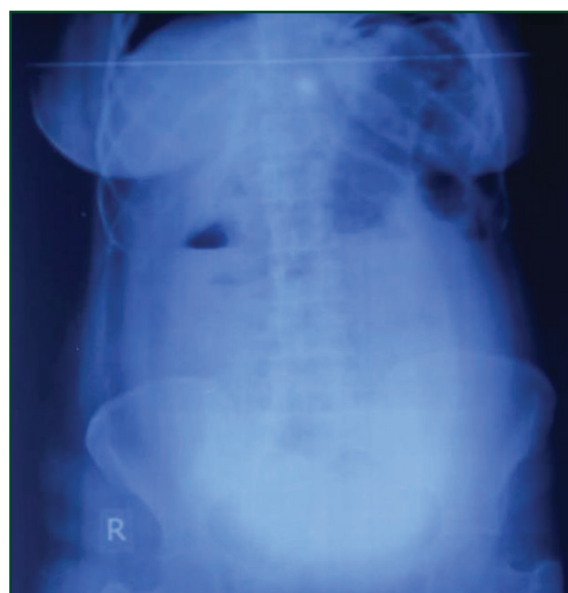


Figure 1

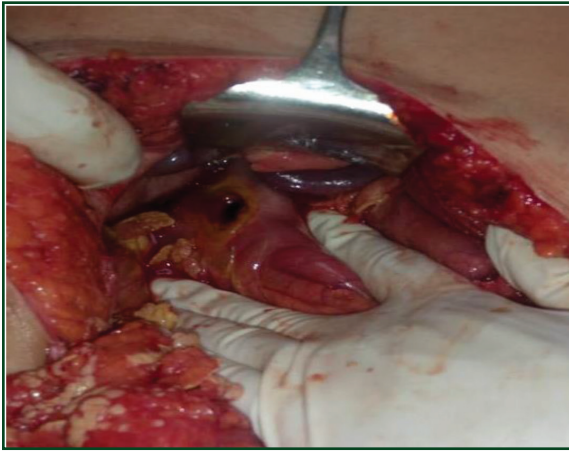

Figure 2

anemia 11 gm/dl, serum electrolytes were slightly deranged with sodium (Na)/ potassium (K) - 130/2.9 mEq/L, liver function test & kidney function test were within normal limit.

The patient was shifted to the emergency operation theater for exploratory laparotomy. Intra-operative one gastric perforation was identified in the antrum of the stomach, close to the lesser curvature. Repair of the perforation with truncal vagotomy with posterior gastro-jejunostomy was done. Histopathology report showed features of chronic inflammation and was negative for *Helicobacter pylori*. Post-operative hospital stay was uneventful and the patient was discharged in the good state of health.

## DISCUSSION

Stress-related gastric mucosal damage or stress ulceration has been documented to occur after many major physiologic insults including trauma, major operative procedures, burn injury, CNS

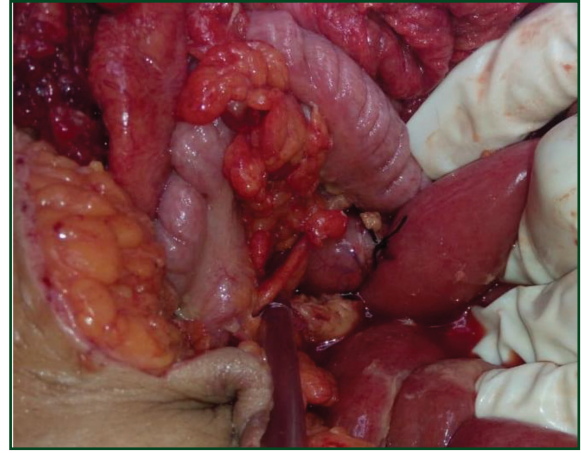


Figure 3

injury, and during critical illness [3]. Depending on the patient's disease and severity of illness, ulceration can be demonstrated in 70 - 100 % of critically ill patients if followed by serial endoscopic examination [7, 8]. The most common presentation of stress ulceration is in the form of upper gastrointestinal bleeding (1.5 - 15%) depending on whether or not patients received stress ulcer prophylaxis [9]. In rare incidences, < 1% of stress ulcer can cause perforation and perforation related complication.

The major risk for the development of stress ulceration includes international normalized ratio (INR) >1.5, sepsis or septic shock, use of vasopressors, use of high dose of systemic corticosteroids, burn >30% of total body surface area and head trauma [10]. The precise mechanism by which gastric stress ulceration develops remains a matter of controversy. Excessive gastric acid production is probably not the principal factor leading to its development, as a pH greater than 3.5-4.0 is evident in 20-60% of critically ill patients [11].

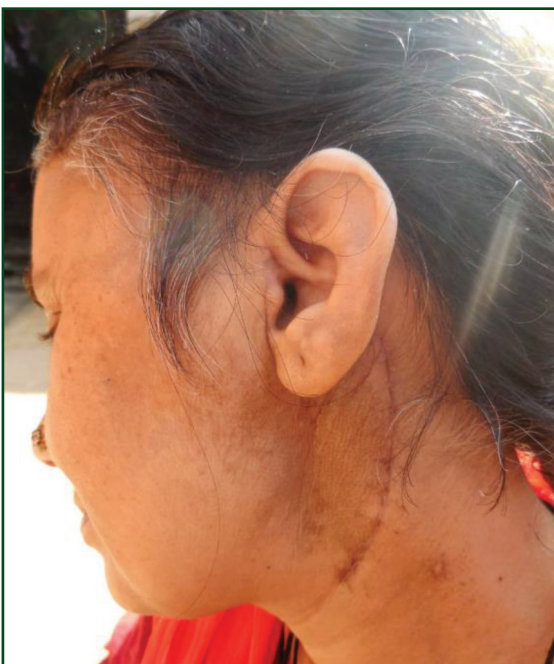

Figure 4

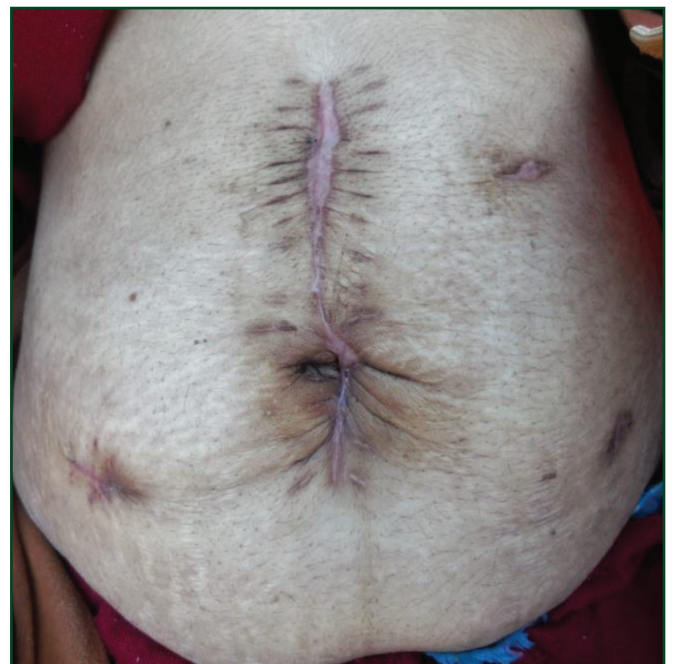


Figure 5

Further, there appears to be a relatively poor relationship between occult upper GI bleeding and gastric pH. In view of these data, an acute loss of mucosal barrier protection is probably the most important factor leading to ulceration. In turn, the loss of barrier protection is probably related to a marked reduction in perfusion of the gastric submucosa during critical illness. Splanchnic vasoconstriction represents an early response to a reduction in global oxygen delivery as blood is diverted to the vital organs such as the heart and brain. The reduction in splanchnic blood volume is disproportionately greater than that seen in other vascular beds [12]. Recognition of this phenomenon and more aggressive and timely resuscitation has probably led to the reduction in the overall incidence of stress ulceration over the last two decades [13].

Our patient, who had gone through total parotidectomy, should have been assessed before any surgical procedure for such possible complications. The Patient had a long-standing chronic gastric ulcer which gave to frank perforation, her surgery is the stress factor. Prophylactic measures could have been taken to reduce the risk of perforation.

The high mortality and morbidity associated with the development of bleeding from stress ulceration have resulted in a variety of strategies, designed to prevent its occurrence [14]. The earliest prophylactic regimens consisted of antacids administered via nasogastric tube and titrated to maintain an intragastric pH > 3.5. Some of the side effects of this regimen include the risk of aspiration, diarrhea, hypophosphatemia, hypermagnesemia or metabolic alkalosis [15].

The introduction of Histamine (H<sub>2</sub>) receptor antagonists greatly simplified stress ulcer prophylaxis. Ranitidine has a far better safety profile, with the most significant adverse effect being thrombocytopenia. This favorable safety profile combined with its profound inhibitory effect on gastric acid secretion has made this H<sub>2</sub> antagonist exceedingly popular for use as an agent for stress ulcer prophylaxis. Proton-pump inhibitors such as pantoprazole, omeprazole with clinical efficacy in chronic acid-peptic disorders, are the best agent for stress ulcer prophylaxis [1, 16].

Sucralfate is an orally administered aluminum salt of sucrose and octasulfate that exerts its effects through several mechanisms by acting as direct barrier to diffusion of hydrogen ions, increases release of cytoprotective prostaglandin E<sub>2</sub> from the gastric mucosa, increases mucus output and enhances the mucosal proliferative zone in areas of ulceration through its binding of angiogenic factors and growth factors. However, a large trial revealed its inferiority to H<sub>2</sub> receptor antagonist, so that an acid suppressive medication is preferred [17].

## CONCLUSION

Any patient undergoing a major operative procedure should be investigated beforehand for indolent peptic ulcer disease, as surgical stress might lead to exaggeration of ulcers and its

complications. Our patient got into a similar situation after going through total parotidectomy when her previous chronic gastric ulcer perforated leading to generalized peritonitis. We emphasize to evaluate suspicious cases of gastric ulcer in the pre-operative period, to prevent future complications.

## REFERENCES

1. Alhazzani W, *et al.* Proton pump inhibitors versus histamine 2 receptor antagonists for stress ulcer prophylaxis in critically ill patients: a systematic review and meta-analysis. *Critical care medicine* 2013;41:693-705.
2. Kim Y, *et al.* "Endoscopic and clinical features of gastric ulcers in Japanese patients with or without Helicobacter pylori infection who were using NSAIDs or low-dose aspirin. *Journal of Gastroenterology* 2012;47: 904-11.
3. Najm WI. Peptic ulcer disease. *Primary Care: Clinics in Office Practice* 2011;38:383-94.
4. Bulut O, Rasmussen C, and Fischer A. Acute surgical treatment of complicated peptic ulcers with special reference to the elderly. *World journal of surgery* 1996;20:574-7.
5. Bertleff MJ, and Lange JF. Perforated peptic ulcer disease: a review of history and treatment. *Digestive surgery* 2010;27:161-9.
6. Lau JY, *et al.* Systematic review of the epidemiology of complicated peptic ulcer disease: incidence, recurrence, risk factors, and mortality. *Digestion* 2011;84:102-13.
7. Miller TA., Tornwall MS., and Moody FG. Stress erosive gastritis. *Current problems in surgery* 1991;28:459-509.
8. Martin LF. "Stress ulcers are common after aortic surgery. Endoscopic evaluation of prophylactic therapy. *The American surgeon* 1994;60: 169-74.
9. Cook DJ., *et al.* Risk factors for gastrointestinal bleeding in critically ill patients. *New England journal of medicine* 1994;330:377-81.
10. Bardou M, Quenot JP, and Barkun A. Stress-related mucosal disease in the critically ill patient. *Nature reviews Gastroenterology & hepatology* 2015;12:98-107.
11. Baghaie AA., *et al.* Comparison of the effect of intermittent administration and continuous infusion of famotidine on gastric pH in critically ill patients: results of a prospective, randomized, crossover study. *Critical care medicine* 1995;23:687-91.
12. Bailey RW, Bulkley GB, Hamilton SR, Morris JB, & Smith GW. Pathogenesis of nonocclusive ischemic colitis. *Annals of surgery*, 1986;203:590-9.
13. Porter JM., and Ivatury RR. In search of the optimal end points of resuscitation in trauma patients: a review. *Journal of Trauma and Acute Care Surgery* 1998;44:908-14.
14. Cook DJ., *et al.* Stress ulcer prophylaxis in the critically III: a meta-analysis. *The American journal of medicine* 1991;91:519-27.
15. Tryba M., and Cook DJ. Gastric alkalization, pneumonia, and systemic infections: the controversy. *Scandinavian Journal of Gastroenterology* 1995;30:53-9.
16. Lin PC, *et al.* The efficacy and safety of proton pump inhibitors vs histamine-2 receptor antagonists for stress ulcer bleeding prophylaxis among critical care patients: a meta-analysis. *Critical care medicine* 2010;38:1197-205.
17. Cook D, *et al.* A comparison of sucralfate and ranitidine for the prevention of upper gastrointestinal bleeding in patients requiring mechanical ventilation. *New England Journal of Medicine* 1998;338:791-7.

*Funding: None; Conflict of Interest: None Stated.*

**How to cite this article:** Kumar S, Alam MS, Akbal S, Chaudhary TK. Hyperacute gastric perforation: A rare presentation in the post-operative period. *Indian J Case Reports*. 2019;5(2):181-183.

Doi: 10.32677/IJCR.2019.v05.i02.029