

Case Report

Traumatic pseudoaneurysm of the superficial temporal artery

Pradeep Balineni¹, Muthukumaran G², Shifa Zareena¹, Ruban Kumar¹, Touzeen Hussain³,
Keerthana Shivaji⁴

From ¹Postgraduate Student, ²Professor, ³Assistant Professor, ⁴Intern, Department of General Surgery, Saveetha Medical College, Thandalam, Chennai, India

Correspondence to: Dr. Pradeep Balineni, Department of General Surgery, Plot No. 112, Revenue Colony, Near S.S.N. Degree College, M.M. Donka, Ongole - 523002, Andhra Pradesh, India. E-mail: Pradeep052191@gmail.com

Received - 01 February 2019

Initial Review - 18 February 2019

Accepted - 04 March 2019

ABSTRACT

Pseudoaneurysm is deficit of all the 3 layers of the blood vessel. Superficial temporal artery due to its course is more prone for trauma and 95% of the pseudoaneurysm of the superficial artery is due to trauma. Here, we report the case of a traumatic pseudoaneurysm of the superficial temporal artery in a 19-year-old patient. The patient came with the complaints of swelling in the left side of the forehead for 3 days and a history of trauma 3 days back by a cricket ball. A duplex scan showed a pseudoaneurysm of the superficial temporal artery. Surgical excision of the aneurysm was done after ligating proximal and distal pedicles. Digital subtraction angiography is the gold standard investigation, but duplex would be enough in most of the cases for diagnosing and surgical excision after ligating the proximal and distal pedicles is the treatment of choice.

Key words: Post-traumatic, Pseudoaneurysm, Superficial temporal artery, Surgical excision

Aneurysms are unusual dilatation of a part of the artery. Based on the shape, they are classified as fusiform or saccular and based on wall layers, they are classified as true and false aneurysms. True aneurysm contains all the three layers of the blood vessel, whereas, pseudoaneurysm or false aneurysms are a deficit of all three layers. Pseudoaneurysm accounts for 1% of total aneurysms [1]. Superficial temporal artery aneurysms are rare. Most commonly they occur due to trauma because of its superficial course. We report the case of a traumatic pseudoaneurysm of the superficial temporal artery in a 19-year-old male.

CASE REPORT

A 19-year-old male patient presented to OPD with complaints of swelling over the left side of forehead since 3 days which was non-progressive in size. There was no associated history of pain, headache, loss of consciousness, seizures, nausea. The patient also revealed a history of trauma to that region by a cricket ball 3 days back but there was no immediate swelling.

On examination, the vitals were stable. There was 3×2 cms solitary, pulsatile, compressible and smooth swelling over the left temporal region (Fig. 1). The swelling was immobile, non-tender and had minimal warmth. A duplex ultrasound scan showed a pseudoaneurysm of the superficial temporal artery (Fig. 2).

Under general anesthesia, surgical exploration was carried out. Temporal skin flaps were raised and pseudoaneurysm was dissected all around. Proximal and distal ends of pseudoaneurysm were ligated and cut (Fig. 3).

Postoperative biopsy showed pseudoaneurysm with a thrombus formation in the luminal wall. On follow-up after 1 month, the patient was comfortable and asymptomatic.

DISCUSSION

Pseudoaneurysm of superficial temporal artery was first described by Bartholin in 1740 [1–3] and from then, there were more than 200 reported cases [2,3] of superficial temporal artery pseudoaneurysms.

External carotid gives off three anterior, three posterior and two terminal branches. Superficial temporal artery is one of the terminal branches and it supplies the scalp [4]. The superficial temporal artery after crossing parotid lies directly over the periosteum of the superior temporal line of the temporal bone and is more prone for trauma in this part. Pseudoaneurysm of the superficial temporal artery may be caused by spontaneous or non-spontaneous factors. Spontaneous factors responsible for pseudoaneurysm are arteriosclerosis, vasculitis, arteriopathy and non-spontaneous factors are sports injury, gunshot wound, falls, road traffic accidents and iatrogenic [5]. Approximately, 95% of cases of superficial temporal artery aneurysms are post-traumatic [3], similar to our case. Most of the cases are solitary pseudoaneurysm but there are also reported cases with multiple pseudoaneurysms in post-craniotomy patients [2].

After trauma to the vessel, extra-arterial hematomas occur due to complete or partial disruption of the internal wall or by contusion and necrosis of the intimal wall layer which leads

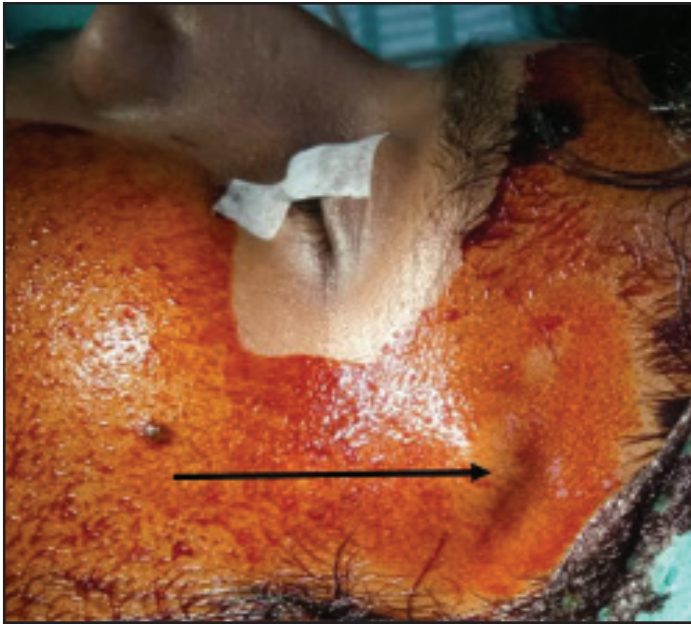


Figure 1: Preoperative picture of swelling

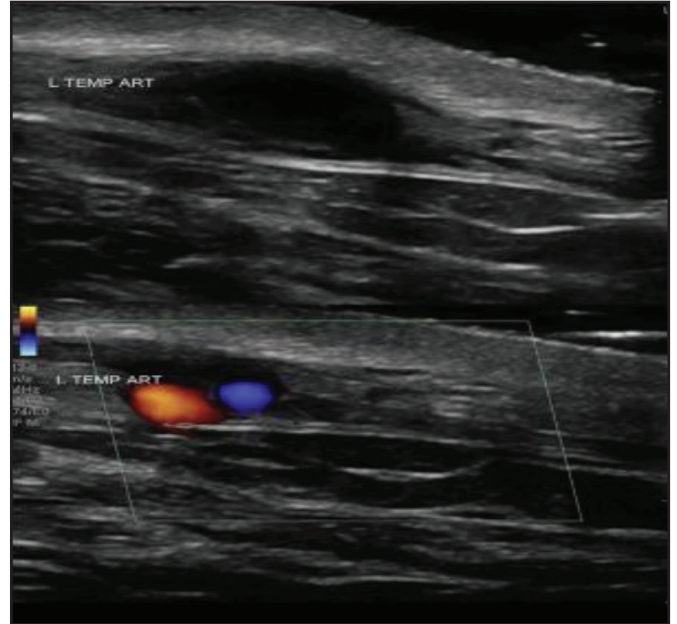


Figure 2: Duplex scan showing aneurysm

to extravasation of blood [3]. A capsule then forms around the hematoma which grows bigger while the hematoma resorption occurs leading to vascular flow and a pulsatile pseudoaneurysm. These patients present with a single painless, pulsatile mass, the pulsation may decrease by applying pressure over the proximal course of the artery [6,7]. They may also present with throbbing headaches, earache, hemorrhage, dizziness, facial nerve palsy and a palpable thrill [1,8]. Almost 1–3% of pseudoaneurysm of the superficial temporal artery may throw an embolus [9].

Duplex ultrasound is a reliable and safe investigation to confirm diagnosis which shows a fusiform dilatation [3,4,10] of the artery, whereas, Digital subtraction angiography is the Gold standard investigation [5]. Computed tomography (CT) angiography can also be done. X-ray and ECHO-Doppler can be

done to rule out fractures and arteriovenous (AV) malformations respectively [1]. A careful examination and investigation should be done prior to intervention to differentiate from other conditions like an abscess, hematoma, neuroma, foreign body granuloma, angiofibroma, AV malformation, lipoma and epidermal cyst [5].

Superficial temporal artery pseudoaneurysm can be treated by manual compressions, thrombin glue injections, coil embolization and surgery [5]. Thrombin glue injection has an 80% success rate but these can embolize into the external carotid artery [4]. Surgery has a 100% cure rate though it leaves a scar. Surgery also reduces the risk of hemorrhage, relieves pain and headache and resolves any cosmetic defects [5]. Hence, surgery is the better treatment of choice with long term result.

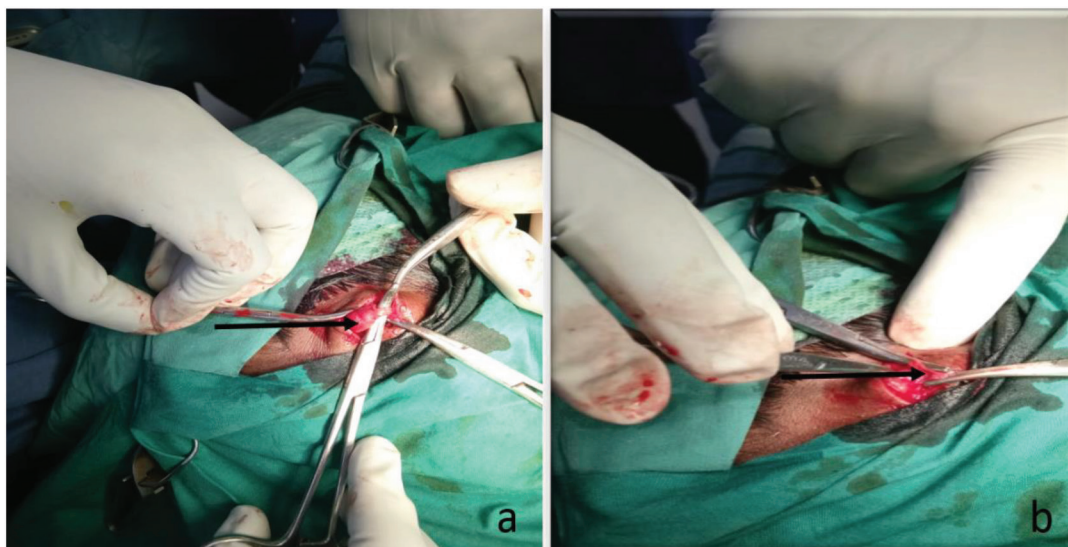


Figure 3: (a) Distal pedicle; (b) Proximal pedicle

CONCLUSION

Though superficial temporal artery pseudoaneurysms are rare, physicians should always rule out pseudoaneurysm of superficial temporal artery in cases of temporal swellings.

REFERENCES

1. Sardana V, Sundar I, Jaiswal M, Gupta P, Chopra S. Traumatic pseudoaneurysm of the superficial temporal artery: A case report and review of literature. *Indian J Neurotrauma* 2012;9:56-8.
2. Walker MT, Liu BP, Salehi SA, Badve S, Batjer HH. Superficial temporal artery pseudoaneurysm: Diagnosis and preoperative planning with CT angiography. *AJNR Am J Neuroradiol* 2003;24:147-50.
3. Shenoy SN, Raja A. Traumatic superficial temporal artery aneurysm: Case report. *Neurol India* 2003;51:537-8.
4. Veen EJ, Poelmann FB, Ijpma FF. A traumatic superficial temporal artery aneurysm after a bicycle accident. *J Surg Case Rep* 2014;10:doi10.1093/jscr/rju112.
5. Seferi A, Alimehmeti R, Pajaj E, Vyshka G. Superficial temporal artery pseudoaneurysm presenting as a growing, pulsatile, and tender mass. *Surg Neurol Int* 2016;7:66-71.
6. Jimenez JC, Nassoura Z, Morris LF, Hu D. Late traumatic aneurysm of the superficial temporal artery. *J Vasc Surg* 2011;54:1174.
7. Kawai H, Hamasaki T, Imamura J, Tomonori N, Odashiro T, Yamahata H. Three cases of spontaneous superficial temporal artery aneurysm with literature review. *Neurol Med Chir* 2014;54:854-60.
8. Hakan T, Ersahin M, Somay H, Aker F. Pseudoaneurysm of the superficial temporal artery following revision of a middle cerebral artery aneurysm clipping: Case report and review of the literature. *Turk Neurosurg* 2011;21: 430-4.
9. Van Uden DJ, Truijers M, Schipper EE, Zeebregts CJ, Reijnen MM. Superficial temporal artery aneurysm: Diagnosis and treatment options. *Head Neck* 2013;35:608-14.
10. Stapleton CJ, Fusco MR, Thomas AJ, Levy EI, Ogilvy CS. Traumatic pseudoaneurysms of the superficial temporal artery: Case series, anatomy, and multidisciplinary treatment considerations. *J Clin Neurosci* 2014;14:1529-32.

Funding: None; Conflict of Interest: None Stated.

How to cite this article: Balineni P, Muthukumaran G, Zareena S, Kumar R, Hussain T, Shivaji K. Traumatic pseudoaneurysm of the superficial temporal artery. *Indian J Case Reports*. 2019;5(2):108-110.

Doi: 10.32677/IJCR.2019.v05.i02.005