

Case Report

Odontogenic myxoma: A case report and review

Shreya Das¹, Anjana Mazumdar²

From ¹3rd Year PG, ²Professor and Head, Department of Oral Pathology, Dr. R. Ahmed Dental College and Hospital, Kolkata, West Bengal, India

Correspondence to: Dr. Shreya Das, Department of Oral Pathology, Dr. R. Ahmed Dental College and Hospital, Kolkata, West Bengal, India. E-mail: dashreya.1992@gmail.com

Received - 23 November 2018

Initial Review - 12 December 2018

Accepted - 16 January 2019

ABSTRACT

Odontogenic myxoma (OM) is a rare and locally invasive benign neoplasm that mainly affects the mandible with a peak incidence in the second–fourth decades of life and predilection for the female. The lesion often grows as a painless swelling. The radiographic features are variable, and therefore, the diagnosis is not easy. Here, we report the case of an OM in a 17-year-old-female occurred as a painless swelling in the lower right jaw for 1 month is presented. Radiologically, it showed a well-demarcated, multilocular radiolucent lesion with fine, bony trabeculae resulting in “sunburst” appearance. According to clinical and radiological features, this article represents a usual case of OM.

Key words: *Histopathological findings, Myxoma, Odontogenic cell rests, radiological features*

Odontogenic myxoma (OM) is a tumor derived from embryonic mesenchymal elements of dental anlage [1,2]. Investigators said that the incidence rate of OM ranges from 0.5% to 19% [3]. The evidence that supports for its odontogenic origin is its exclusive location in the tooth-bearing areas, occasional association with missing or unerupted teeth, presence of islands of odontogenic epithelium, and histopathological findings which resembles with dental mesenchyme [4].

OM of the jaw has a tendency for extensive bone destruction, invasion into surrounding structures [5]. It has a high recurrence rate of up to 25% after curettage; however, metastasis is rare [3]. The lack of capsule and infiltrative growth pattern is responsible for high recurrence when conservative enucleation and curettage are performed [6,7]. Histopathologically, OM is characterized by a loose, abundant eosinophilic mucoid-rich extracellular matrix or extracellular production of a ground substance that contains round, spindle-shaped, or angular cells with small hyperchromatic nuclei and cytoplasmic processes are interspersed in thin collagen or reticulin fibers [3].

In this article, a rare case of OM of the mandible in a female patient with all classical findings is reported. Along with clinical, histopathological, and radiological features, we also discussed the recent advance diagnostic works (immunohistochemistry), differential diagnosis, and treatment modalities of this lesion.

CASE REPORT

A 17-year-old female was referred to the department of oral pathology at the dental hospital of Kolkata with a swelling in the lower right jaw for 1 month. The medical history was not significant. She had neither any history of extraoral trauma to

that region nor did she have any history of tobacco and alcohol usage.

On the first visit to the oral pathology OPD, a thorough extraoral examination revealed a firm to hard, diffuse swelling in the right body of the mandible extended up to the right angle of the mandible (Fig. 1). An intraoral examination revealed enlargement of the buccal cortical plate with no expansion of lingual cortical plate and obliteration of buccal vestibule in relation to the corresponding premolars and molars.

After thorough clinical examination, the patient was advised for complete blood count, blood sugar estimation both fasting and PP, bleeding (BT) and clotting time, and erythrocyte sedimentation rate. All the above-mentioned investigations were found normal. Viral markers for hepatitis B, C, and HIV were negative. Radiological investigation (orthopantomogram [OPG]) was also done. OPG revealed a well-demarcated, multilocular radiolucent lesion in the body of the mandible with fine, bony trabeculae resulting in “sunburst” appearance (Fig. 2). The lesion was provisionally diagnosed as osteosarcoma.

Then, the patient was advised for incisional biopsy to confirm the diagnosis (Fig. 3). Section stained with H and E (Fig. 4) revealed the presence of several loosely arranged spindle- and stellate-shaped cells with long cytoplasmic processes distributed evenly in abundant mucoid tissue. Few areas of inactive odontogenic epithelium in a ground substance were also seen. Thus, the overall histopathological findings were corroborative to the OM. After histopathological diagnosis, the patient was sent to the department of oral and maxillofacial surgery for excision of the lesion which was performed under general anesthesia. After 3-month, on follow-up of the patient, no complication or recurrence, whatsoever, was reported. The patient’s recovery was uneventful.

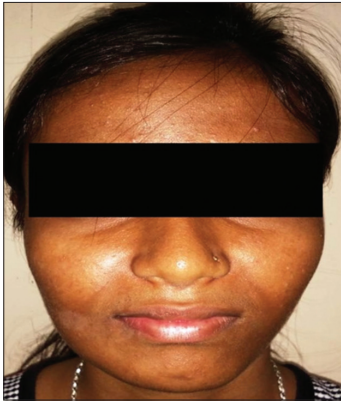

Figure 1: Extraoral pre-operative clinical photograph showing swelling of the right angle of the mandible

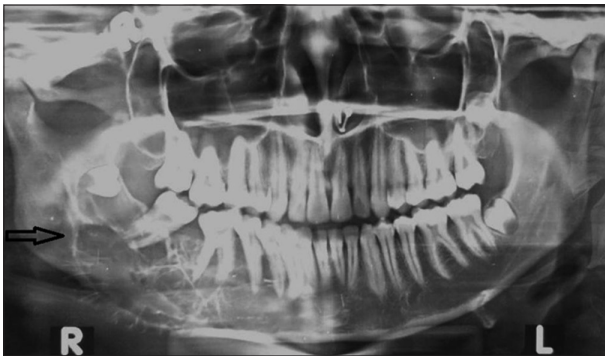

Figure 2: Radiograph showing honeycomb and sunburst appearance

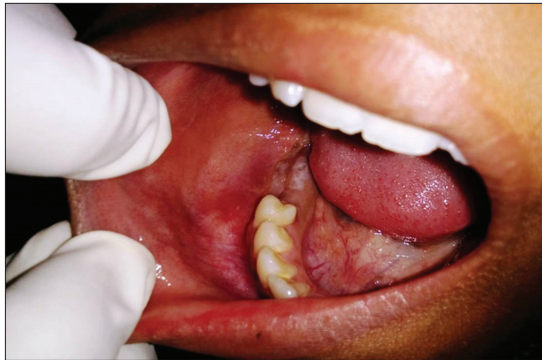

Figure 3: Intraoral clinical photograph during incisional biopsy

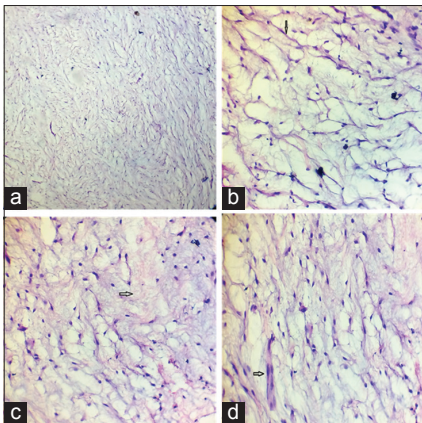


Figure 4: (a) H and E stained section showing stellate, spindle-shaped cells in an abundant, loose myxoid stroma (in $\times 10$ view); (b) H and E stained section showing cells with their long cytoplasmic processes (in $\times 40$ view); (c) H and E stained section showing hypocellular area with eosinophilic ground substance (in $\times 40$ view); (d) H and E stained section showing odontogenic epithelial islands (in $\times 40$ view)

DISCUSSION

Virchow first coined the word “myxoma” [3]. Myxomas of odontogenic origin were first described by Thoma and Goldman, in 1947 [8]. OM accounts for 3–6% of all odontogenic tumors [3]. The unencapsulated tumor has bony trabeculae, irregular calcifications, scant blood vessels, and sparse capillaries. Nests of odontogenic epithelium are occasionally seen but not essential for diagnosis. The presence of mast cells has been reported in a few cases. Fibers are oriented toward the tumor periphery. The undifferentiated mesenchymal cells are capable of fibroblastic differentiation also [9-11]. It can be designated either as odontogenic fibromyxoma, in which the myxomatous element predominates, or odontogenic myxofibroma, with a predominance of fibrous tissue. Some regard OM as a modified form of fibroma in which the myxoid changes of the connective tissue is more prominent [8,12].

The usual occurrence of OM is between 10 and 40 years of age, with a peak incidence in the third decade of life [3]. Some authors stated that the lesion is more common in the mandibular premolar area, whereas others found equal incidence in both jaws [3]. Few reported male:female ratio of 1:2, whereas other researchers have reported ratios ranging from 1:1.5 to 1:4. Investigators stated that there is no sex predilection, whereas others reported a slight predominance in males [3]. OM is usually painless and displacement of teeth and paresthesia is uncommon clinical features, therefore, reaches a considerable size before being detected [9,12-14]. Radiographically, the tumor presents as a unilocular or multilocular radiolucent lesion with well-defined borders expressing a mottled, soap-bubble, tennis racquet, honeycombed, sunray, or sunburst appearance. The lesion shows “wispy” bony trabeculae within radiolucent areas. Unilocular lesions are more frequently found in the anterior region of the jaws, while multilocular lesions occur mainly in the posterior region [13,15].

OM should be included in the differential diagnosis of both radiolucent and mixed lesions. In the case of unilocular and without trabeculae, the tumor may be misdiagnosed as periapical, lateral, periodontal, and traumatic bone cysts. When multilocular, it must be distinguished from ameloblastoma, central hemangioma, odontogenic keratocyst, aneurysmal bone cyst, glandular odontogenic cyst, central giant cell granuloma, cherubism, metastatic tumor, and osteosarcoma [15]. Fibromyxoid sarcoma, myxoid chondrosarcoma, and rhabdomyosarcoma should also be ruled out.

Histopathologically, a spectrum of fibrous connective tissue stroma from myxoid to densely hyalinized and relatively acellular to cellular is present [16,17]. It is distinguished by the presence of sparse cords and islands of inactive odontogenic epithelium [18,19]. An immunohistochemical panel of poly- and mono-clonal antibodies is used to characterize and distinguish the nature of cells as of fibroblastic, histiocytic, myoblastic, and neural origin. Three types of OM cells were discriminated: Spindle cells, stellate cells, and hyaline cells. Neoplastic cells of myxomas are positively stained for transferrin, ferritin, alpha-1-antichymotrypsin (alpha 1-ACT),

alpha-1-antitrypsin (alpha 1-AT), S-100 protein, vimentin, and actin; however, neuron-specific enolase, S-100 alpha subunit, S-100 beta subunit, factor VIII-related antigen, and cytokeratin are negative [10,18].

Antibodies directed against vimentin are used to identify mesenchymal cells, and keratin antibodies detect epithelial differentiation. Spindle cells are positive for transferrin, ferritin, alpha 1-ACT, alpha 1-AT, S-100 protein, and vimentin. Stellate cells are strongly positive for transferrin, alpha 1-AT, S-100 protein, and vimentin. Hyaline cells react with alpha 1-ACT and alpha 1-AT. The myxomatous matrix shows a negative reaction for all these antibodies. These results support that OM is a tumor of a dual fibroblastic and histiocytic origin and also suggest that the cells comprising OM are of myofibroblastic origin [10,19,20]. The expression of matrix metalloproteinases 2 and 9 supports the invasive character of these lesions, which degrade the extracellular matrix, thus penetrates the bony trabeculae resulting in tumor growth.

The tumor is not radiosensitive, and surgery is the only treatment of choice [1,12,21]. Recurrence is minimized with extensive partial or total resection procedures, and this method of treatment is particularly indicated in case of maxilla due to the proximity of vital structures [6,17,22,23]. Complete extirpation of the tumor is difficult because infiltration may be more extensive than that observed clinically. Surgically, it can be enucleated along with curettage, excised widely, or resected, or radical surgery can also be done. Some recommended an initially conservative approach followed by radical surgery if required. When radical surgery is performed, delayed reconstruction has been advised due to the high recurrence rate. On gross examination, OM appears as a grayish-white, nodular heterogeneous mass of variable consistency, with a glistening gelatinous cut surface. All of these classical clinical, radiological, and histopathological features were seen in our case.

CONCLUSION

The clinical and radiographic findings of OM vary and often are not pathognomonic. Therefore, concurrent histopathological findings allow for the definitive diagnosis. This type of lesion should be diagnosed carefully due to their clinical, radiological, and histopathological features overlapping with aggressive lesions, while their prognosis and treatment protocols are different. Hence, a careful clinical and radiological evaluation along with a precise histopathological examination must be carried out to arrive at a proper diagnosis and, consequently, a favorable outcome for the patient.

ACKNOWLEDGMENTS

We would like to thank our guide Dr. Anjana Mazumdar for her valuable support whenever required. We would also like to thank the patient for her cooperation.

REFERENCES

1. Abiose BO, Ajagbe HA, Thomas O. Fibromyxomas of the jaws: A study of 10 cases. *Br J Oral Maxillofac Surg* 1987;25:415-21.
2. Lu Y, Xuan M, Takata T, Wang C, He Z, Zhou Z, *et al.* Odontogenic tumors. A demographic study of 759 cases in a Chinese population. *Oral Surg Oral Med Oral Pathol Oral Radiol Endod* 1998;86:707-14.
3. Shivashankara C, Nidoni M, Patil S, Shashikala KT. Odontogenic myxoma: A review with report of an uncommon case with recurrence in the mandible of a teenage male. *Saudi Dent J* 2017;29:93-101.
4. Stout AP. Myxoma, the tumor of primitive mesenchyme. *Ann Surg* 1948;127:706-19.
5. Hernández Vallejo G, Cohn C, García Peñín A, Martínez Lara S, Llanes Menéndez F, Montalvo Moreno JJ, *et al.* Myxoma of the jaws. Report of three cases. *Med Oral* 2001;6:106-13.
6. Simon EN, Merx MA, Vuhahula E, Ngassapa D, Stoelinga PJ. Odontogenic myxoma: A clinicopathological study of 33 cases. *Int J Oral Maxillofac Surg* 2004;33:333-7.
7. Brannon RB. Oral and maxillofacial, odontogenic tumors. *Clin North Am* 2004;16:359-74.
8. Reichart PA, Philipsen HP. *Odontogenic Tumors and Allied Lesions*. London: Quintessence Publishing Co., Ltd.; 2004.
9. Regizi JA, Scuibba J. *Oral Pathology Clinical - Pathologic Correlations*. London: WB Saunders Company Ltd.; 2003. p. 278-9.
10. Lo Muzio L, Nocini P, Favia G, Procaccini M, Mignogna MD. Odontogenic myxoma of the maxilla: A clinical, radiologic, immunohistochemical, and ultrastructural study. *Oral Surg Oral Med Oral Pathol Oral Radiol Endod* 1996;82:426-33.
11. Zimmermann DC, Dahlin DC. Myxomatous tumors of the jaws. *Oral Surg Oral Med Oral Pathol* 1958;11:1069-80.
12. Deron PB, Nikolovski N, den Hollander JC, Spoelstra HA, Knegt PP. Myxoma of the maxilla: A case with extremely aggressive biologic behavior. *Head Neck* 1996;18:459-64.
13. Gnepp DR. *Diagnostic Surgical Pathology of Head and Neck*. London: WB Saunders Company Ltd.; 2001. p. 643.
14. Neville BW, Damm DD, Allen CM, Bouquot JE. *Oral and Maxillo-facial Pathology*. London: WB Saunders Company Ltd.; 2002. p. 635-7.
15. Chuchurru JA, Luberti R, Cornicelli JC, Dominguez FV. Myxoma of the mandible with unusual radiographic appearance. *J Oral Maxillofac Surg* 1985;43:987-90.
16. Gosh BC, Huvos AG, Gerold FP, Miller TR. Myxoma of the jaw bones. *Cancer* 1973;31:237-40.
17. Gormley MB, Mallin RE, Solomon M, Jarrett W, Bromberg B. Odontogenic myxofibroma: Report of two cases. *J Oral Surg* 1975;33:356-9.
18. Zhao M, Lu Y, Takata T, Ogawa I, Miyauchi M, Mock D, *et al.* Immunohistochemical and histochemical characterization of the mucosubstances of odontogenic myxoma: Histogenesis and differential diagnosis. *Pathol Res Pract* 1999;195:391-7.
19. Oygür T, Dolanmaz D, Tokman B, Bayraktar S. Odontogenic myxoma containing osteocement-like spheroid bodies: Report of a case with an unusual histopathological feature. *J Oral Pathol Med* 2001;30:504-6.
20. Green TL, Leighty SM, Walters R. Immunohistochemical evaluation of oral myxoid lesions. *Oral Surg Oral Med Oral Pathol Oral Radiol Endod* 1992;73:407-71.
21. Farman AG, Nortjé CJ, Grotepass FW, Farman FJ, Van Zyl JA. Myxofibroma of the jaws. *Br J Oral Surg* 1977;15:3-18.
22. Sloopweg PJ, Wittkamp RM. Myxoma of the jaws: An analysis of 15 cases. *J Maxillofac Surg* 1986;14:46-52.
23. Sapp PJ, Eversole LR, Wysocki GP. *Contemporary Oral and Maxillofacial Pathology*. Missouri: Mosby-Year Book; 1997. p. 144.

Funding: None; Conflict of Interest: None Stated.

How to cite this article: Das S, Mazumdar A. Odontogenic myxoma: A case report and review. *Indian J Case Reports*. 2019;5(1):41-43.

Doi: 10.32677/IJCR.2019.v05.i01.014