

# Case Report

## Rupture of an incisional hernia with evisceration of the gut: A case report

Anthony J Edeh<sup>1</sup>, Ugochukwu T Uchendu<sup>2</sup>, Chukwuemeka I Nwangwu<sup>1</sup>, Chijioke C Aneko<sup>1</sup>,  
Chukwuebuka C Aliozo<sup>1</sup>

From<sup>1</sup>Department of Surgery, Enugu state university of science and technology teaching hospital, Enugu, Nigeria, <sup>2</sup>Department of Orthopaedics and Trauma, National orthopaedic hospital, Enugu, Nigeria

**Correspondence to:** Ugochukwu Timothy Uchendu, Department of Orthopaedics and Trauma, National orthopaedic hospital, Enugu, Nigeria. E-mail: [ugotimuchendu@gmail.com](mailto:ugotimuchendu@gmail.com)

Received - 12 October 2018

Initial Review - 29 October 2018

Accepted - 16 December 2018

### ABSTRACT

Spontaneous rupture of the abdominal wall hernia is very rare and usually occurs in incisional and recurrent groin hernias. Here, we report the case of rupture of a large incisional hernia with the evisceration of small bowel in a 56-year-old female. This surgical emergency was successfully managed using the current standard tension-free prosthetic mesh.

**Key words:** *Evisceration of gut, Incisional hernia, Spontaneous rupture, Tension-free prosthetic mesh*

Spontaneous rupture of the abdominal wall hernia is very rare and usually occurs in an incisional and recurrent groin hernia [1]. Despite our awareness of many causative factors and improvements in the surgical techniques and materials, iatrogenic abdominal wall hernia formation remains a significant problem in an abdominal wall surgery. An incisional hernia is known to occur in 11–23% of laparotomies [2].

Commoner complications of such hernias include pain, discomfort, skin changes, bowel obstruction, incarceration, and strangulation. These tend to reduce the overall quality of life. Spontaneous rupture with the evisceration of a gut in an incisional hernia is very rare but represents a real surgical emergency. These hernias are of particular concern for their high recurrence rates and the challenges associated with their repair [3]. We report rupture of a large incisional hernia with the evisceration of small bowel in a 56-year-old female.

### CASE REPORT

A 56-year-old lady presented to a Medical Center, Nigeria with the complaints of the evisceration of a gut of 30 min duration. The patient was in a tricycle going to the market when after a bout of cough; she noticed pain and evisceration of the gut from her hernia (Fig. 1). The patient gave a history of laparotomy and abdominal hysterectomy for a huge uterine leiomyoma in a private hospital about a year ago. The hernia developed after 3 months of surgery and has continued to get bigger and uncomfortable, but she was working to save enough money for repair when this occurred.

On general examination, the patient was frightened and in painful distress. Her height and weight were 1.75 m and 86 kg, respectively. The temperature was 37.2°C, respiratory rate was 20 cycles per minute, pulse rate was 86 beats per minute, and blood pressure was

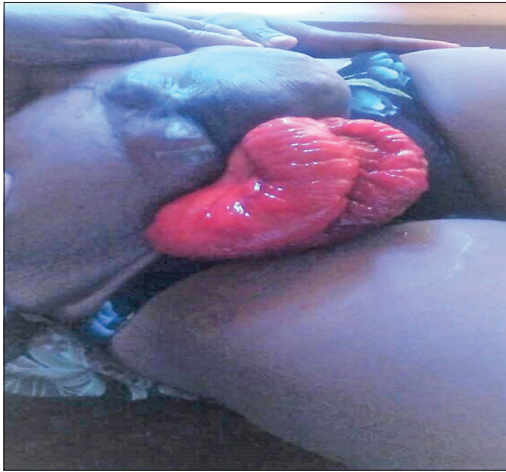
130/80 mmHg. Abdominal examination revealed a large swelling of >20 cm in diameter in the upper half of a subumbilical midline scar. The skin was hyperpigmented and thin. Two loops of small bowel (Jejunum) were eviscerated which appeared normal. Digital rectal examination showed brownish soft, formed stool in the rectum.

The patient was admitted, the gut was washed with saline, covered with clean linen and the normal saline infusion was started with prophylactic antibiotics. She was investigated, counseled and consent obtained for surgery. The blood investigation results showed a hemoglobin of 10.3 g/dl [12–14 g/dl], total white blood cell count of  $5 \times 10^9/L$  [ $4-11 \times 10^9/L$ ], and platelet count of  $340 \times 10^9/L$  [ $150-350 \times 10^9/L$ ]. Urinalysis by dip stick was normal and retroviral screening was negative.

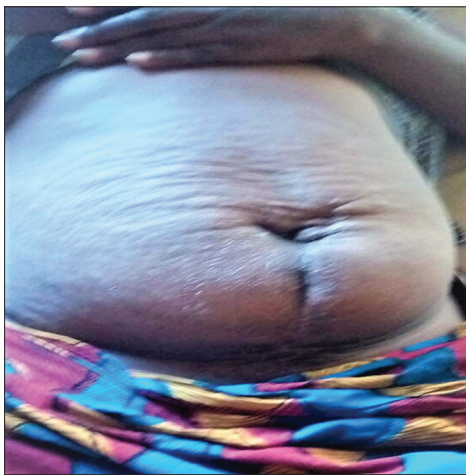The surgery was performed under general anesthesia. A huge defect of 20 cm diameter in the midline below the umbilicus was examined. The sac was dissected and returned to the peritoneal cavity with the gut. The defect was enlarged by a midline incision up to the umbilicus and down to the pubis to facilitate non-tension closure with nylon and a 15 cm×15 cm propylene mesh sutured to the closed defect. Defect closure was done with 2 nylon by far sutures (>1 cm) from the midline alternating with near sutures (>0.5 cm) from the midline and beginning from the umbilicus to the pubic symphysis. Her post-operative period was uneventful and was discharged on the 5<sup>th</sup> post-operative day. The patient was seen at 6 weeks and 6 months, and there was no clinical sign of recurrence (Fig. 2). The patient has been counseled to continue follow-up at 6 monthly intervals for at least 2 years.

### DISCUSSION

According to most reports in Nigeria, the most common abdominal surgery leading to an incisional hernia was cesarean



**Figure 1: Evisceration of the gut from the hernia**



**Figure 2: Follow-up of the patient after 6 months showed no recurrence of the condition**

section [4-7]. Our patient had a history of laparotomy and total abdominal hysterectomy. The incisional hernia can present early after surgery or many years subsequently [8]. Our patient presented early (3 months) after the primary surgery.

A large incisional hernia has a thin sac, relatively avascular or atrophic overlying skin which all contribute to higher chances of rupture [9]. A neglect for early operative intervention or delay in seeking treatment increases the risk of rupture [10,11]. If there is any anticipated delay in early repair of an incisional hernia, a binder or corset wrapped around the abdomen may prevent further enlargement of the fascial defect or sudden disruption of the covering skin [12]. There was a delay in our patient. The rupture may be sudden following any event which can increase intra-abdominal pressure such as coughing, lifting heavy weight, straining at defecation, and micturition or it may be gradual after developing an ulcer at its base [9]. Our patient had a sudden bout of coughing preceding the rupture. The hernia contents can be covered primarily by mesh repair if the general condition and condition of the operation site allows or can be covered by skin followed by delayed mesh repair [13]. We repaired the defect

primarily and only a patch of polypropylene mesh over the repair.

Reported spontaneous rupture of large incisional hernias is rare in the literature. Gupta *et al.* believe there are only 8 such cases reported in the medical literature up to 2011 [14]. Since 2011, there have been some reported intestinal hernias with evisceration [15]. Akkucuk *et al.* in Turkey reported the second repair of such a hernia with mesh [16]. There are still others which were reported after 2011 from different parts of the world including Emegoakor *et al.* in Nigeria [15-20].

## CONCLUSION

In resource-poor societies, preventable morbidities and unusual presentations continue to be witnessed in our surgical practice. The case we reported is typical, and we had presented one approach to successfully managing it.

## REFERENCES

1. Santora TA, Roslyn JJ. Incisional Hernia: Hernia Surgery in the Surgical Clinics of North America. Vol. 73. Philadelphia, PA: W.B. Saunders Company; 1993. p. 557-70.
2. Cassar K, Munro A. Surgical treatment of incisional hernia. *Br J Surg* 2002;89:534-45.
3. Dur AH, den Hartog D, Tuinebreijer WE, Kreis RW, Lange JF. Low recurrence rate of a two-layered closure repair for primary and recurrent midline incisional hernia without mesh. *Hernia* 2009;13:421-6.
4. Ezeome ER, Nwajiobi CE. Challenges in the repair of large abdominal wall hernias in Nigeria: Review of available options in resource limited environments. *Niger J Clin Pract* 2010;13:167-72.
5. Garba ES. The pattern of adult external abdominal hernias in Zaria. *Niger J Surg Sci* 2000;2:12-5.
6. Gali BM, Madziga AG, Na'aya HU, Yawe T. Management of adult incisional hernias at the university of Maiduguri teaching hospital. *Niger J Clin Pract* 2007;10:184-7.
7. Udo IA, Bassey EA, Abasiattai AM. Early outcome of incisional hernia repair using polypropylene mesh: A preliminary report. *Niger Med J* 2014;55:333-7.
8. Houck JP, Rypins EB, Sarfeh IJ, Juler GL, Shimoda KJ. Repair of incisional hernia. *Surg Gynecol Obstet* 1989;169:397-9.
9. Singla SL, Kalra U, Singh B, Narula S, Dahiya P. Ruptured Incisional hernia. *Trop Doct* 1997;27:112-3.
10. Hamilton RW. Spontaneous rupture of an Incisional hernia. *Br J Surg* 1966;53:477-9.
11. Mudge M, Hughes LE. Incisional hernia: A 10 year prospective study of incidence and attitudes. *Br J Surg* 1985;72:70-1.
12. Doherty GM, Mulvihill SJ, Pellegrini CA. Post-operative complications. In: Way LW, Doherty GM, editors. *Current Surgical Diagnosis and Treatment*. 11<sup>th</sup> ed. New York: Lange Medical Books, McGraw-Hill; 2003. p. 23-37.
13. D'Ambrosio R, Capasso L, Sgueglia S, Iarrobino G, Buonincontro S, Carfora E, *et al.* The meshes of polypropylene in emergency surgery for strangulated hernias and incisional hernias. *Ann Ital Chir* 2004;75:569-73.
14. Gupta RK, S S, S C A. Spontaneous rupture of incisional hernia: A rare cause of a life-threatening complication. *BMJ Case Rep* 2011;2011:3486.
15. Emegoakor C, Dike E, Emegoakor F. Unusual complications of incisional hernia. *Ann Med Health Sci Res* 2014;4:971-4.
16. Akkucuk AA, Paltaci I, Kaplan A, Ugur M. A successful repair of incarcerated and eviscerated hernia with polypropylene mesh. *J Med Cases* 2013;4:729-31.
17. Sailaja S, Umadevi K, Rathud PS, Shnuti S, Bafna UD. Spontaneous evisceration of an incisional hernia presenting one year after primary surgery. *Online J Health Allied Sci* 2013;12:15.

18. Tsavdaris G, Hotzoglou N, Kovnidis A, Karakatsanis A, Keokos N. Spontaneous ruptured incisional hernia. *Hell J Surg* 2012;84:187-8.
19. Kshirsagar AY, Vasisth GO, Dwivedi P, Nikam YP. Spontaneous rupture of incisional hernia; a rare life-threatening complication of incisional hernia. *Int J Biomed Adv Res* 2013;4:565-6.
20. Martis JJ, Shridhar KM, Rajeshwara KV, Janardhanan D, Jairaj D. Spontaneous rupture of incisional hernia-a case report. *Indian J Surg* 2011;73:68-70.

*Funding: None; Conflict of Interest: None Stated.*

**How to cite this article:** Edeh AJ, Uchendu UT, Nwangwu CI, Aneko CC, Aliozo CC. Rupture of an Incisional Hernia with Evisceration of the Gut: A Case Report. *Indian J Case Reports*. 2018;4(6):495-497.

Doi: 10.32677/IJCR.2018.v04.i06.029