

Case Report

Sjogren's syndrome presenting with recurrent hypokalemic paralysis

Parikshit Singh Chauhan¹, Samarjeet Singh², Harwinder Sangwan³

From Classified Specialist, ¹Department of Nephrology, ²Department of Radiology, ³Department of Medicine, Military Hospital, Jalandhar, Punjab, India

Correspondence to: Samarjeet Singh, Department of Radiology, Military Hospital Jalandhar - 144005, Punjab, India.

E-mail: samarafmc@gmail.com

Received - 11 October 2018

Initial Review - 29 October 2018

Accepted - 26 November 2018

ABSTRACT

Sjogren's syndrome is an autoimmune disorder commonly affecting females and presents with the dryness of the mouth and eyes. Here, we present an interesting case of Sjogren's syndrome, initial presentation with distal renal tubular acidosis (RTA) causing recurrent hypokalemic paralysis, and dyspnea requiring ventilator support. The patient improved dramatically with potassium and alkali supplementation. She has been on follow-up for the past 3 months and remains asymptomatic. Only a few case reports and series have been reported on such initial presentation of Sjogren's syndrome. To conclude, one must be aware of distal RTAs associated with autoimmune disorder presenting with hypokalemic paralysis.

Key words: *Distal renal tubular acidosis, Hypokalemic paralysis, Sjogren's syndrome*

Primary Sjogren's syndrome is a chronic autoimmune disorder characterized by sicca symptoms, a combination of dry eyes (keratoconjunctivitis) and dry mouth (xerostomia). It clinically involves mainly exocrine glands such as lacrimal and salivary glands with or without extraglandular involvement of the skin, lungs, kidneys, gastrointestinal tract, bladder, peripheral nerves, and other organ systems. Secondary Sjogren's syndrome develops in the presence of primary autoimmune disorders such as systemic lupus erythematosus (SLE) and rheumatoid arthritis. Sjogren's syndrome has worldwide distribution; the incidence of Sjogren's syndrome varies widely as per geographic distribution. In a meta-analysis of population-based study, the overall incidence and prevalence were 7 and 43 persons per 100,000 person-years [1], and the highest rates are being from Europe and Asia. The ratio of female to male in a multicenter registry varies from 7:1 for African Americans to 27:1 for Asians [2].

Distal renal tubular acidosis (RTA) are uncommon disorders; Type I commonly associated with hypokalemia, The common causes of type I RTAs in the adult being autoimmune disorders like Sjogren syndrome, rheumatoid arthritis and hypercalciuric states, while hereditary distal RTA is most common in children [3]. Distal RTA type I is characterized by normal anion gap metabolic acidosis, hypokalemia, nephrolithiasis, nephrocalcinosis, and osteomalacia.

Usually, the acidosis and hypokalemia associated with Sjogren's syndrome is mild, but there have been cases reported of hypokalemia severe enough to cause paralysis as the first presentation of Sjogren's syndrome.

CASE REPORT

A 28-years-old lady presented to the emergency ward with a complaint of dyspnea of 1-day duration associated with an inability

to move all limbs for 6 h of duration. She had no history of fever, chest pain, drug intake, or snakebite. The patient had a history of admission twice in the past 4 months with similar complaints at another center requiring ventilator support both times, once for 3 weeks. She also took antitubercular therapy (ATT) for 2 months to relieve the pain of the left hip which was associated with non-specific symptoms such as unexpressed weight loss, malaise, and fatigue without any clinical improvement. As there was no improvement, she had quit the treatment on her own. Clinically, the patient had tachypnea (respiratory rate - 30/min) with Sp_o₂ - 94% at room air and power grade 2/5 all limbs.

Her investigations during the hospitalization period were as follows: Hemoglobin - 8.9 g/dl, total leukocyte count - 9800/mm³, platelet count - 1.53 lakh/mm³, blood smear showed microcytic hypochromic anemia, urea/creatinine - 27/0.7 mg/dl, bilirubin/serum glutamic oxaloacetic transaminase/serum glutamic pyruvic transaminase - 0.8/23/28, Ca/PO₄ - 8.0/2.7, urine routine examination revealed albumin 1+, 24 h urinary protein - 1768 mg/24 h, 25 D3 - 65 ng/ml, antinuclear antibody by enzyme-linked immunosorbent assay - 160 U (N<20 U), soluble substance A - 98.05 U (<20), soluble substance B - 40 U (<20), ds DNA - 10.30 IU/ml, Anti-Sm Ab - 5.6 U (<20), creatine phosphokinase - 172 (N<170 U/L), contrast-enhanced computed tomography kidney-ureter-bladder revealed bilateral multiple renal calculi, and Schirmer's test was negative. The X-ray hips (Fig. 1) were suggestive of pseudofractures. Urgent investigations done were suggestive of severe hypokalemia (K - 2.2 meq/dl) and combined metabolic and respiratory acidosis (pH - 7.18, pO₂ - 104, pCO₂ - 48, and HCO₃ - 10).

Considering the findings of above-mentioned investigations, a diagnosis of Sjogren's syndrome was made and a lip biopsy was

performed which showed leukocytic infiltrates in the interstitium (Fig. 2). She was intubated (difficult due to subglottic stenosis) in view of impending respiratory fatigue, started on IV potassium and alkali supplements with a gradual improvement of clinical parameters such as muscle strength and respiratory efforts, and laboratory parameters such as arterial blood gas and serum potassium. She was extubated on the 4th day, following admission. She was continued on oral alkali, potassium, and iron supplements and started on low-dose steroids in view of subnephrotic proteinuria. Currently, the patient is on regular follow-up and has been asymptomatic except for hoarseness of voice due to recurrent laryngeal nerve palsy. She is planned to be kept on regular follow-up for the development of other systemic manifestations.

DISCUSSION

Twenty-five percent of patients with Sjogren's syndrome have distal RTAs [4]. The possible mechanism of distal RTA in Sjogren syndrome is an absence of H⁺-ATPase pump in intercalated cells in the collecting tubules due to immune-mediated injury leading to decreased secretion and hence retention of hydrogen ions [5], which leads to increased excretion of potassium ions in exchange for sodium reabsorption in collecting tubules to maintain electroneutrality [6]. The other mechanism is of defective H⁺-ATPase pump which leads to sodium wasting hence stimulation of angiotensin-aldosterone activity causing hypokalemia [7].

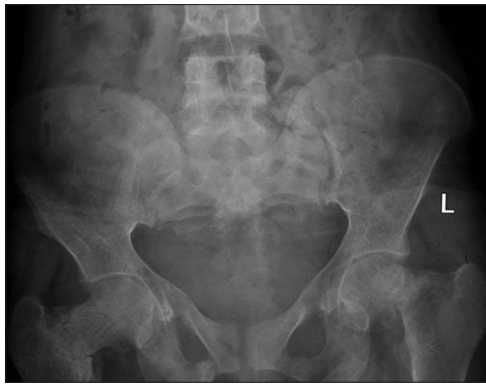

Figure 1: X-Ray of the hip showing pseudofracture of the right hip joint and pathological fracture of the left hip joint

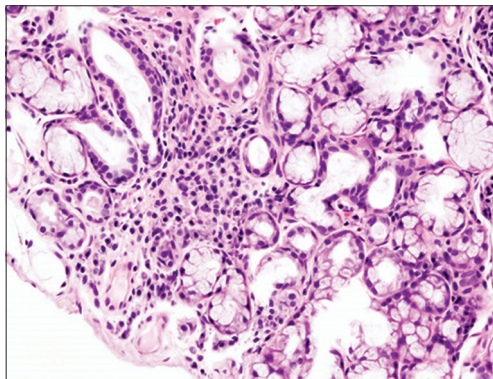


Figure 2: Salivary gland surrounded by lymphocytic infiltration of the interstitium

There have been case reports of hypokalemic paralysis being associated with Sjogren's syndrome from India and abroad. The first case of hypokalemic paralysis was reported in 1981 [8]. The largest case series has been from Pune where 16 patients of Sjogren's syndrome were documented to have hypokalemic periodic paralysis among a database of 50,000 patients [9]. There has been no consensus on performing a renal biopsy in primary Sjogren's syndrome, and further studies are required for its indication in this disease [10].

In our case, as the patient had subnephrotic proteinuria only with no hypoalbuminemia and renal dysfunction, we did not perform a renal biopsy and she has already been started on immunosuppressants. Although she had no sicca symptoms, the objective test for lacrimal glands was inconclusive and lip biopsy and positive serological tests for antibodies confirmed the diagnosis. She had all the features of distal RTAs such as metabolic acidosis, hypokalemia, and nephrolithiasis. Daily lifelong therapy with the alkali, i.e., 1–2 meq/kg/day is the treatment of choice. She has also been offered supportive treatment such as iron and vitamin supplements and low-dose steroids with marked improvement. Our patient on first time had first presented with paralysis requiring ventilator support and other supportive measures and osteomalacia presenting as pain hip joint, for which ATT empirically was started since she had other non-specific features such as unquantified weight loss, malaise, and fatigue without any clinical improvement. It was on evaluation during subsequent admission that she was diagnosed with Sjogren's syndrome.

CONCLUSION

One must be aware of distal RTAs associated with autoimmune disorder presenting with hypokalemic paralysis. We have presented this case to sensitize and raise awareness about this rare presentation of a rare disorder.

REFERENCES

1. Qin B, Wang J, Yang Z, Yang M, Ma N, Huang F, *et al.* Epidemiology of primary Sjögren's syndrome: A systematic review and meta-analysis. *Ann Rheum Dis* 2015;74:1983-9.
2. Brito-Zerón P, Acar-Denizli N, Zeher M, Rasmussen A, Seror R, Theander E, *et al.* Influence of geolocation and ethnicity on the phenotypic expression of primary Sjögren's syndrome at diagnosis in 8310 patients: A cross-sectional study from the big data Sjögren project consortium. *Ann Rheum Dis* 2017;76:1042-50.
3. Rodríguez Soriano J. Renal tubular acidosis: The clinical entity. *J Am Soc Nephrol* 2002;13:2160-70.
4. Pun KK, Wong CK, Tsui EY, Tam SC, Kung AW, Wang CC, *et al.* Hypokalemic periodic paralysis due to the Sjögren syndrome in Chinese patients. *Ann Intern Med* 1989;110:405-6.
5. Cohen EP, Bastani B, Cohen MR, Kolner S, Hemken P, Gluck SL, *et al.* Absence of H(+)-ATPase in cortical collecting tubules of a patient with Sjogren's syndrome and distal renal tubular acidosis. *J Am Soc Nephrol* 1992;3:264-71.
6. Sebastian A, McSherry E, Morris RC Jr. Renal potassium wasting in renal tubular acidosis (RTA): Its occurrence in Types 1 and 2 RTA despite sustained correction of systemic acidosis. *J Clin Invest* 1971;50:667-78.
7. Gueutin V, Vallet M, Jayat M, Peti-Peterdi J, Cornière N, Leviel F, *et al.* Renal β -intercalated cells maintain body fluid and electrolyte balance. *J Clin Invest* 2013;123:4219-31.

8. Raskin RJ, Tesar JT, Lawless OJ. Hypokalemic periodic paralysis in Sjögren's syndrome. *Arch Intern Med* 1981;141:1671-3.
9. Kulkarni N, Chopra A. Clinical profile of primary Sjogrens syndrome with hypokalemic periodic paralysis. *J Assoc Physicians India* 2018;66: 69-70.
10. Kidder D, Rutherford E, Kipgen D, Fleming S, Geddes C, Stewart GA, *et al.* Kidney biopsy findings in primary Sjögren syndrome. *Nephrol Dial Transplant* 2015;30:1363-9.

Funding: None; Conflict of Interest: None Stated.

How to cite this article: Chauhan PS, Singh S, Sangwan H. Sjogren's syndrome presenting with recurrent hypokalemic paralysis. *Indian J Case Reports*. 2018;4(6):419-421.

Doi: 10.32677/IJCR.2018.v04.i06.001