

## Case Report

# Multifocal retiform hemangioendothelioma of bone masquerading as skeletal metastasis

Neha Chopra Narang<sup>1</sup>, Salil Narang<sup>1</sup>, Vasantha Kumar Venugopal<sup>2</sup>

From <sup>1</sup>Ex Senior Resident, Department of Pathology, UCMS & GTB Hospital, <sup>2</sup>Consultant Radiologist, Department of Radiology, IBS Hospital, New Delhi, India

**Correspondence to:** Dr. Neha Chopra Narang, Department of Pathology, UCMS & GTB Hospital, New Delhi, India. E-mail: [nehac1080@gmail.com](mailto:nehac1080@gmail.com)

Received – 07 July 2018

Initial Review - 16 July 2018

Accepted - 18 August 2018

### ABSTRACT

Hemangioendothelioma (HE) is a rare primary bone tumor of vascular origin constituting 0.5–1% of primary malignant bone tumors. Here, we report the clinical and histopathological features of a 38-year-old male who presented with multifocal lesions involving the left scapula, left proximal humerus, and the left ulnar olecranon process which was diagnosed as metastatic lesion radiologically and clinically. The final diagnosis of retiform HE was made on the basis of histopathology.

**Key words:** Multifocality, Retiform hemangioendothelioma, Skeletal metastasis.

Retiform hemangioendothelioma (RHE) is a rare vascular neoplasm of an intermediate grade of malignancy. It was first described by Calonje *et al.* in 1994 [1]. HE usually occurs in the age group of 20–80 years, and approximately 25% are multicentric [2]. These tumors commonly involve the lower limb bones; however, <10% also involve vertebrae and only few may occur in the skull, pelvis, and clavicle [2,3]. These tumors have a high rate of local recurrence and low rate of metastasis. Two studies on RHE have been described, one by Aditya *et al.* [4] who reported RHE as a primary bone tumor arising from parietal bone and the other by Kyo Kim *et al.* [5] arising from the sphenoid bone in infratemporal fossa.

We report an unusual case of multifocal RHE, mimicking metastasis clinically as well as radiologically, and extensive literature search has failed to reveal such presentation of RHE as a primary bone tumor.

### CASE REPORT

A 38-year-old male presented to the department with a chief complaint of difficulty in lifting the left upper limb above the shoulder level and decrease in power or feeling of weakness in the same for 6 months. He gave a history of a fall while practicing martial arts in August 2016. The physical examination revealed no abnormality except tenderness while lifting the left upper limb. The vitals were within the normal range.

The radiographic investigation (X-ray) showed complete destruction of the left glenohumeral joint with an irregularly marginated destruction of the glenoid cavity of the left scapula. Adjacent lobulated homogenous soft tissue density was noted in the left axilla, which was suggestive of a malignant lesion. Cortical

breach along with radiolucent areas in the medulla was noted in the left proximal humerus. Subsequent non-contrast-enhanced computerized tomography (NCCT) and magnetic resonance imaging (MRI) revealed expansile soft tissue mass involving the glenoid cavity. The adjacent body of the left scapula was causing a destruction of the same with extension into adjacent soft tissue, and associated lytic changes were seen in the left proximal humerus and proximal end of ulna (Fig. 1). A fluorodeoxyglucose-positron emission tomography scan showed these lesions to be metabolically active and destructive. Based on the above findings, a possibility of skeletal metastasis was given. Incision biopsy from the left elbow showed marked capillary proliferation admixed with lymphocytic infiltrate and eosinophils. The possibility of a vasoformative lesion was suggested.

The patient underwent the left upper limb forequarter amputation removing the whole of the scapula, part of the clavicle, and the whole upper limb. Gross examination (Fig. 2) revealed hemorrhagic destructive lesion involving the glenoid cavity and adjacent body of the scapula with extension into adjacent soft tissue. Hemorrhagic lytic lesions were also noted in the proximal humerus (Fig. 2) and proximal end of the ulnar olecranon process. Microscopic examination of sections from scapula, humerus, and olecranon process revealed similar morphology with a presence of an irregular pattern of the elongated and arborizing vessels. Neoplastic vessels were lined by a single layer of hobnail-like endothelial cells along with the presence of papillae having a hyalinized collagenous core. The intervening stroma was fibrotic and showed lymphocytic and eosinophilic inflammatory infiltrate (Fig. 3). The tumor cells lacked cytological atypia, and mitosis was sparse. The final diagnosis of RHE was given. Unfortunately, the patient was lost to follow-up. Hence, no additional therapy or treatment was given to the patient.

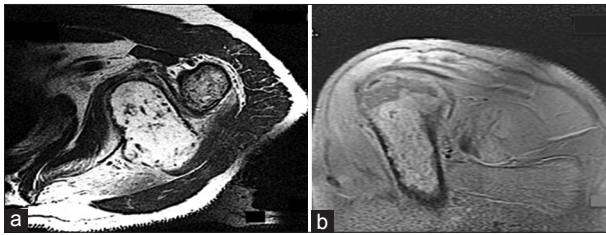


Figure 1: Magnetic resonance imaging. (a) Axial T2 image shows a lytic expansive lesion with multiple flow voids in the scapula. (b) Sagittal PD image showing hyperintense lytic lesion in proximal humerus in the same patient

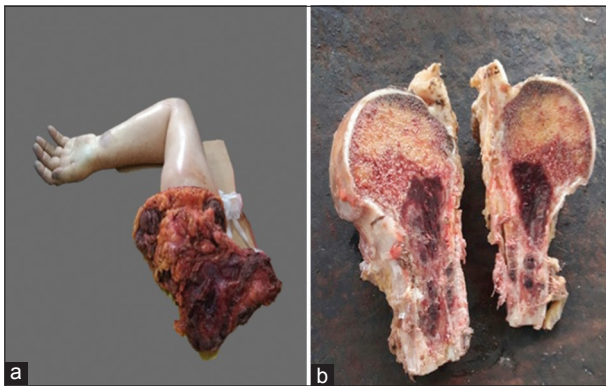


Figure 2: Gross examination. (a) Hemorrhagic destructive lesion involving glenoid cavity and adjacent body of the scapula with extension into adjacent soft tissue (b) Hemorrhagic lytic lesions noted in the proximal humerus

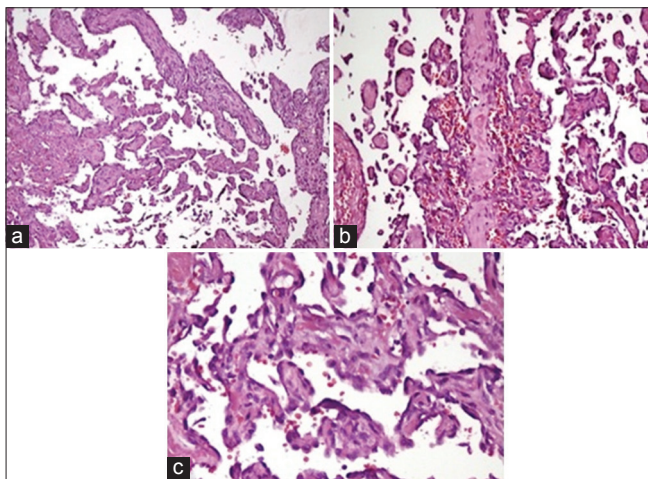


Figure 3: Microscopic examination. (a) Characteristic narrow and arborizing vascular channel infiltrating bone (H & E x40). (b) The intervening fibrotic stroma showed lymphocytic and eosinophilic inflammatory infiltrate. (c) Neoplastic vessels lined by a single layer of hobnail-like endothelial cells along with papillae having hyalinized collagenous cores

**DISCUSSION**

Vascular tumors of bone are a heterogeneous group having different classification schemes. These tumors in bone arise from endothelial cells, resulting in variable expression of endothelial markers which cannot differentiate between benign and malignant lesions [6]. The classification of vascular tumors of bone is controversial due to the lack of consistent terminology, definitive histologic criteria, and

Table 1: Proposed classification of vascular tumors of the bone by Wenger and Wold (2000)

Proposed classification of vascular tumors of the bone
<b>Benign vascular tumors of the bone</b>
<b>Hemangioma</b>
Cavernous
Capillary
<b>(Hem) angiomatosis</b>
Non-aggressive, regional
Non-aggressive, disseminated (cystic angiomatosis)
Aggressive or massive osteolysis or Gorham stout’s disease
<b>Intermediate (locally aggressive and rarely metastasizing) vascular tumors of bone</b>
<b>Epithelioid hemangioma</b>
<b>Malignant vascular tumors of the bone</b>
Epithelioid hemangioendothelioma
Angiosarcoma
Primary
Irradiation-induced
Bone infarction associated

Table 2: Differential diagnosis of multifocal retiform hemangioendothelioma of bone

Purely lytic pattern	Young	Histiocytosis Brown tumor Metastasis
	Old	Metastasis Myeloma Lymphoma
	Mixed lytic and sclerotic pattern	Fibrous dysplasia Aneurysmal bone cyst Fibrous cortical defect
Mixed lytic and sclerotic pattern	Solitary lesion with well-defined margins	Osteosarcoma Ewing’s sarcoma Fibrosarcoma
	Solitary lesion with ill-defined margins	

limited correlation with clinical outcome [6]. In 2000, Wenger and Wold proposed a new classification system for benign and malignant vascular tumors, considering these lesions as a spectrum [6] (Table 1).

HE can affect any portion of the skeleton but most commonly involves the axial skeleton. They have slight male preponderance with multicentricity described in 25% of cases [2]. Histopathological examination is required to confirm the diagnosis of RHE as it does not have definitive clinical or radiologic features. The radiological appearance of vascular tumors is not specific; however, radiologic multifocality points toward vascular neoplasm as a differential possibility [6,7]. Radiologically, malignant vascular tumors of the bone present as single or multiple (contiguous/disseminated) lytic lesions with cortical destruction and endosteal scalloping or have mixed sclerotic and lytic pattern [6]. The possible differential diagnosis to be considered in young and old patients presenting with multifocal lytic lesions and with mixed pattern has been summarized in Table 2 [2,8].

Requena and Kutzner [9] described seven subtypes of HE, RHE, spindle cell HE (hemangioma), papillary intralymphatic angioendothelioma (Dabska tumor), Kaposiform HE, epithelioid HE, pseudomyogenic HE, and composite HE. The biological behavior of these vascular tumors is intermediate

between benign hemangioma and malignant angiosarcoma. All cases of spindle cell HE showed benign behavior and hence were categorized as a hemangioma. Epithelioid HE had more aggressive biological behavior than the other subtypes. The other five subtypes including RHE are truly borderline vascular lesions.

HE has been classified into three histologic grades (Grade 1, 2, and 3) based on the degree of vasoformative appearance, tumor cell pleomorphism, and mitotic figures. This grading was described by Unni [10]. The grade of anaplasia is considered as the most important indicator of prognosis with disease-free survival decreasing with increasing grade [8,10]. The final diagnosis of RHE is usually available postoperatively as the pre-operative biopsy may not give a definitive diagnosis as in our case. The need for surgical intervention and post-operative adjuvant therapy (chemotherapy/radiotherapy) should be carefully considered to avoid unnecessary complications, but no post adjuvant therapy was administered in the present case as the patient was lost to follow up.

## CONCLUSION

RHE is a rare vascular neoplasm of an intermediate grade of malignancy. A number of diagnostic techniques are available, but final diagnosis of such lesion can be done on the basis of histopathology. Surgery and post-operative adjuvant therapy (chemotherapy/radiotherapy) can be used as a treatment modality. The improved prognosis of patients depends on the early diagnosis and accurate treatment.

## REFERENCES

1. Calonje E, Fletcher CD, Wilson-Jones E, Rosai J. Retiform hemangioendothelioma. A distinctive form of low-grade angiosarcoma delineated in a series of 15 cases. *Am J Surg Pathol* 1994;18:115-25.
2. Adler B, Naheedy J, Yeager N, Nicol K, Klamar J. Multifocal epithelioid hemangioendothelioma in a 16-year-old boy. *Pediatr Radiol* 2005;35:1014-8.
3. Evans HL, Raymond AK, Ayala AG. Vascular tumors of bone: A study of 17 cases other than ordinary hemangioma, with an evaluation of the relationship of hemangioendothelioma of bone to epithelioid hemangioma, epithelioid hemangioendothelioma and high grade angiosarcoma. *Hum Pathol* 2003;34:680-9.
4. Aditya GS, Santosh V, Yasha TC, Shankar SK. Epithelioid and retiform hemangioendothelioma of the skull bone-report of four cases. *Indian J Pathol Microbiol* 2003;46:645-9.
5. Kim IK, Cho HY, Jung BS, Pae SP, Cho HW, Seo JH, *et al.* Retiform hemangioendothelioma in the infratemporal fossa and buccal area: A case report and literature review. *J Korean Assoc Oral Maxillofac Surg* 2016;42:307-14.
6. Verbeke SL, Bovee JV. Primary vascular tumors of bone: A spectrum of entities? *Int J Clin Exp Pathol* 2011;4:541-51.
7. Vermaat M, Vanel D, Kroon HM, Verbeke SL, Alberghini M, Bovee JV, *et al.* Vascular tumors of bone: Imaging findings. *Eur J Radiol* 2011;77:13-8.
8. Narang V, Garg B, Sood N, Kaur H. Multifocal hemangioendotheliomas of bone mimicking metastases. *Indian J Pathol Microbiol* 2014;57:609-10.
9. Requena L, Kutzner H. Hemangioendothelioma. *Semin Diagn Pathol* 2013;30:29-44.
10. Unni KK. *Dahlin bone tumors*. 5th ed. Philadelphia: Lippincott-Raven;1996. p. 317-28.

*Funding: None; Conflict of Interest: None Stated.*

**How to cite this article:** Narang NC, Narang S, Venugopal VK. Multifocal retiform hemangioendothelioma of bone masquerading as skeletal metastasis. *Indian J Case Reports*. 2018;4(4):327-329.

Doi: 10.32677/IJCR.2018.v04.i04.025