

Case Report

Basal Cell Adenoma: A rare case report with immunohistochemical analysis

Anjali Sharma¹, Deshant Agarwal², Anil Kumar Gupta³, Chandralekha L Pande⁴

From ¹Head and Senior Consultant, ²Assistant Consultant, ⁴Ex Head, Department of Pathology, ³Senior Consultant, Department of Surgical Oncology, Bhagwan Mahaveer Cancer Hospital and Research Centre, Jaipur, Rajasthan, India

Correspondence to: Dr. Deshant Agarwal, Flat No. 49A/02 Elegance Apartment, S B Vihar, Swez Farm, Sodala, Jaipur, Rajasthan, India. E-mail: deshaant@gmail.com

Received – 26 March 2018

Initial Review – 29 April 2018

Published Online – 08 July 2018

ABSTRACT

Basal cell adenoma (BCA) of the salivary gland is a rare benign monomorphic adenoma accounting for approximately 1–2% of all salivary gland tumors. It is characterized by the presence of sheets/nests of monomorphic cells with a prominent basement membrane. An absence of myxoid and chondroid stroma separates it from the pleomorphic adenoma. Participation of myoepithelial cells is still a controversial issue in the histogenesis of this tumor. We are presenting a case of BCA of the parotid gland in an elderly male patient. A panel of immunohistochemical markers is used to confirm its benignity and emphasize its use to differentiate it from other common histological entities. We briefly review the literature and discuss the differential diagnosis of this rare entity.

Key words: Basal cell adenoma, Calponin, P63, Salivary gland neoplasm

Salivary gland tumors account for 2–6.5% of all head-and-neck tumors [1], and among salivary gland neoplasm, basal cell adenoma (BCA) constitutes only 1–3%. BCA was first introduced by Kliensasser and Kleir in 1697, but it was recognized as a distinct disease entity in 1991 by the WHO [1]. It is characterized by uniform appearing basaloid cells arranged in a solid, tubular, trabecular, and membranous pattern. The characteristic feature of adenoma is a lack of myxoid and chondroid mesenchymal component. The absence of myoepithelial cells was also considered to be a characteristic feature of this tumor; however, the current reports suggest the role of myoepithelial cells in its histogenesis [2]. Here, we report a case of a 50-year-old male patient with BCA of the parotid gland.

CASE REPORT

A 50-year-old patient reported in our hospital with a chief complaint of a painless swelling on the left pre-auricular region, which is gradually increasing in size for the past 1 year. The patient was a beedi smoker for the past 20 years. There was no history of fever and weight loss. The patient has not taken any prior treatment for the same.

On general physical examination, lymphadenopathy was present, and a well-circumscribed nodule, firm in the consistency of size 3 cm×3 cm was identified in the left preauricular area. The overlying skin was normal in color and was freely movable. Intraoral examination showed an absence of swelling. Other routine laboratory tests including hemoglobin, hematocrit, red blood cell counts, lactate dehydrogenase, bilirubin, and liver and kidney function tests showed no significant abnormality and

were in normal range. On correlating the history and clinical examination, a provisional diagnosis of pleomorphic adenoma was given.

To know the extension and exact location of the tumor, computed tomography was planned, which showed enhancing nodular mass of size 5.4 cm×3.9 cm×3.2 cm in superficial lobe of the left parotid. No calcification and cystic lesion were noted. Fine-needle aspiration cytology was performed and was suggestive of low-grade epithelial neoplasm, suspected as pleomorphic adenoma. However, the probabilities of malignancy could not be ruled out. Radical left parotidectomy with supraomohyoid neck dissection was done. On gross examination, the cut surface showed a capsulated well-circumscribed gray-white area of size 4 cm×2.5 cm×2.5 cm, surrounded by normal salivary gland tissue.

Histopathological examination revealed a well-encapsulated lesion characterized by a biphasic population of cells arranged in sheets, which were separated by a thin eosinophilic membrane. The peripheral cells were small with hyperchromatic nuclei and show palisading arrangement, while the inner parts of the sheets were formed by large hypochromatic cells. Numerous ducts like structures were also seen, which were filled with eosinophilic material within the sheets (Fig. 1). Evidence of cartilage and myxoid stroma were not identified. Capsular invasion, perineural invasion, nuclear atypia, necrosis, and mitotic figures were not seen. Lymph nodes (level I to III) were negative for tumor involvement. The overall microscopic features were suggestive of BCA.

Further immunohistochemical (IHC) examination was planned to confirm the diagnosis. Low molecular weight cytokeratin (LMWCK), carcinoembryonic antigen (CEA), P63,

calponin, S100, and Ki67 were applied. Cells surrounding the ductal structures showed positivity for LMWCK and CEA. Rest of the tumor cells showed immunopositivity for P63; however, calponin and S100 were found to be negative. Ki67 index was <3%. The overall IHC profile confirmed our diagnosis of BCA (Fig. 2). All the soft tissue margins of resected specimen were evaluated and were found to be negative for tumor involvement. The patient was kept under regular follow-up for the past 2 years with no evidence of recurrence.

DISCUSSION

BCA is a rare, benign epithelial neoplasm of the salivary gland. It frequently occurs over 50 years of age, 3–8 cm in size as a unilateral well-circumscribed painless mass [3]. Histologically, four patterns have been described: Solid, trabecular, tubular, and membranous. They are characterized by the presence of uniform and regular basaloid cells with two different morphologies. One

group of cells present at the periphery of tumor nests/islands is smaller cells with little cytoplasm and intensive basaloid-rounded nuclei. The other group of cells is placed centrally, which are larger cells with abundant cytoplasm and pale nuclei. A basement membrane-like eosinophilic structure surrounds the tumor nests separating them from surrounding stroma [4].

The microscopic findings of BCA are not very characteristic. Pleomorphic adenoma, basal cell adenocarcinoma, and adenoid cystic carcinoma are considered as differential diagnosis of BCA [4]. In basal cell adenocarcinoma, capsular invasion, necrosis, abnormal mitotic figures, increased mitotic activity, and perineural and vascular invasion can be seen [4]. The Ki 67 is also found to be more than 5% [5]. Adenoid cystic carcinoma is an invasive tumor, lacks capsulation, and shows perineural invasion. It lacks vascularity in the microcystic areas [6]. Since it is a malignant tumor, the expression of proliferating marker Ki 67 ranges from 13.6% to 34.7%, while in BCA, it is <5% [3]. Pleomorphic adenoma shows variable histomorphology with the blending of cell cytoplasm to the adjacent stroma. It also shows myxoid/chondroid stroma which is not observed in BCA [3].

IHC analysis can help to rule out the differential diagnosis. BCA expresses variable IHC expression from tumor to tumor. However, overall, it supports the multidirectional differentiation into ductal, basal, and myoepithelial cells. It shows positivity for LMWCK, CEA, and EMA mainly confined to the cells surrounding ductal structures. Peripheral tumor cells located adjacent to connective tissue stroma show immunoreactivity for P63, S100, SMA, calponin, myosin, and vimentin, suggesting its association with myoepithelial cells [7]. P63 shows immunopositivity for both myoepithelial cells and basal cells; however, basal cells are immunonegative for S100 and calponin [8].

In our case, ductal cells (luminal cells) showed positivity for LMWCK and CEA. While the other component cells of tumor were positive for P63 and negative for S100 and Calponin, suggesting that the tumor was composed largely of basal cells. Ki67 was <3% and favors its benign nature. Overall, microscopic and IHC findings confirm the diagnosis of BCA. Primary treatment of BCA is surgical excision by means of a superficial/

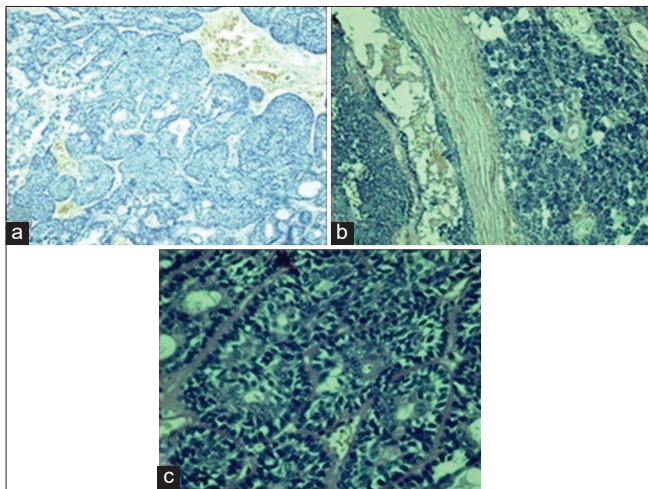


Figure 1: (a) Tumor cells arranged in sheets and nests ($\times 40$). (b) Encapsulated tumor separated by fibrous capsule from surrounding normal tissue. (c) Tumor sheets are separated by eosinophilic membrane. Peripheral hyperchromatic cells with inner hypochromatic cells

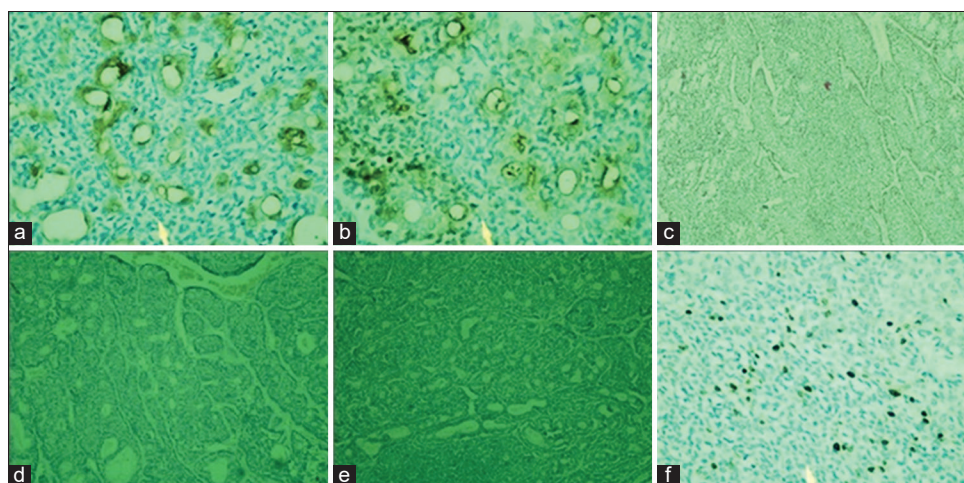


Figure 2: Immunohistochemical staining - (a) positivity for low molecular weight cytokeratin; (b) positivity for carcinoembryonic antigen; (c) positivity for P⁶³; (d) No immunoreactivity for S100; (e) No immunoreactivity for calponin; (f) immunoreactivity for Ki 67

total parotidectomy, and postoperatively, there is no role of chemotherapy/radiotherapy if excision performed adequately. In the membranous type of BCA, total parotidectomy is proposed due to an increased tendency of multicentricity and increased recurrence (25–37%) and malignant transformation rate (28%). Despite its benign behavior a long term follow-up is advisable to detect recurrence [9].

CONCLUSION

As BCA is now considered as a separate entity, we can expect an increase in its diagnosis. A comprehensive analysis of BCA is required with IHC analysis to differentiate it from the similar lesion. IHC patterning suggests the involvement of luminal and abluminal cells in its histogenesis. The role of myoepithelial cells in BCA is still a controversial issue and should be further studied. In any suspected neoplastic salivary gland tumor, differential diagnosis of its malignant counterpart should be ruled out.

REFERENCES

1. Gupta N, Jadhav K, Ahmed MB, Amberkar VS. Basal cell adenoma in a relatively rare site. *J Oral Maxillofac Pathol* 2009;13:101-4.
2. González-García R, Nam-Cha SH, Muñoz-Guerra MF, Gamallo-Amat C. Basal cell adenoma of the parotid gland. Case report and review of the

literature. *Med Oral Patol Oral Cir Bucal* 2006;11:E206-9.

3. Motoki N, Kohei S, Shuichi K, Tatsushi S, Kanae N, Hisao I. Tubular trabecular type basal cell adenoma of the parotid gland: A patient report. *Yonago Acta Med* 2010;53:65-9.
4. Giriyan SS, Ahmed MS. Basal cell adenoma of parotid gland: A rare case report and review of literature. *Int J Sci Res* 2016;5:1711-4.
5. Jung MJ, Roh JL, Choi SH, Nam SY, Kim SY, Lee SW, *et al.* Basal cell adenocarcinoma of the salivary gland: A morphological and immunohistochemical comparison with basal cell adenoma with and without capsular invasion. *Diagn Pathol* 2013;8:171.
6. Jang M, Park D, Lee SR, Hahm CK, Kim Y, Kim Y, *et al.* Basal cell adenoma in the parotid gland: CT and MR findings. *AJNR Am J Neuroradiol* 2004;25:631-5.
7. Ogawa I, Nijai H, Takata T, Miyauchi M, Ito H, Ijuhin N. The cellular composition of basal cell adenoma of the parotid gland: An immunohistochemical analysis. *Oral Surg Oral Med Oral Pathol* 1990;70:619-26.
8. Nagao T, Sato E, Inoue R, Oshiro H, H Takahashi R, Nagai T, *et al.* Immunohistochemical analysis of salivary gland tumors: Application for surgical pathology practice. *Acta Histochem Cytochem* 2012;45:269-82.
9. Yu GY, Ubmüller J, Donath K. Membranous basal cell adenoma of the salivary gland: A clinicopathologic study of 12 cases. *Acta Otolaryngol* 1998;118:588-93.

Funding: None; Conflict of Interest: None Stated.

How to cite this article: Sharma A, Agarwal D, Gupta AK, Pande CL. Basal Cell Adenoma: A rare case report with immunohistochemical analysis. *Indian J Case Reports*. 2018;4(3):227-229.