

Case Report

Lingual mandibular bone defect: A case report and review

Sanjana Ravindra, Poornima Chandra, Balaji Pachipulusu, Mahesh Kumar TS

From Department of Oral Medicine and Radiology, Rajarajeswari Dental College and Hospital, Bengaluru, Karnataka, India

Correspondence to: Dr Sanjana Ravindra, Department of Oral Medicine and Radiology, Rajarajeswari Dental College and Hospital, Bengaluru, Karnataka, India. E-mail: sanjanaravindra@gmail.com

Received - 20 March 2018

Initial Review - 29 April 2018

Published Online - 10 May 2018

ABSTRACT

Lingual mandibular bone defect is an asymptomatic radiolucent lesion of the mandible and usually encountered during routine radiographic examinations. It is essential to diagnose this lesion because of its resemblance with other odontogenic pathologies. A 67-year-old female patient presented with a case of lingual mandibular bone defect which was an incidental finding. Panoramic radiograph and cone-beam computed tomography were used for diagnosing the defect.

Key words: *Developmental salivary gland defect, Lingual mandibular bone defect, Stafne bone cyst*

Lingual mandibular bone defect is a depression or a concavity containing salivary gland tissue in the lingual cortex of mandible [1]. It is described as asymptomatic, unilateral, well-defined, ovoid or round, unilocular radiolucency between the mandibular angle and the third molar [2]. This type of bone defect is generally encountered incidentally on routine radiographic examination [3]. A 67-year-old female patient presented with a case of lingual mandibular bone defect which was an incidental finding.

CASE REPORT

A 67-year-old female patient presented to the Department of Oral Medicine and Radiology with a chief complaint of missing teeth in lower left back tooth region for 2 months and wanted a replacement of missing teeth. History revealed that she underwent extraction of lower left back teeth due to mobility. Her medical history revealed that she was being treated for diabetes mellitus (Metformin 500 mg) for 12 years. On general physical examination, the patient was moderately built and nourished. Extraoral examination revealed no abnormalities and no regional lymphadenopathy. On intraoral examination, edentulous space in relation to 17, 27, and 37, generalized mobility of teeth, root stumps in relation to 46 and 47, supragingival calculus, and extrinsic stains were noted.

A screening panoramic radiograph was advised, which revealed a well-defined unilocular radiolucency measuring about 1 cm × 0.5 cm anterior to the right angle of the mandible and below the inferior alveolar canal (Fig. 1). Margins of the lesion were well defined with corticated border that was more prominent on superior and anterior surface. Based on the radiographic appearance of the lesion, a working diagnosis of lingual mandibular bone defect was given. To ascertain the extent of the

lesion, the patient was advised to undergo cone-beam computed tomography (CBCT). A round, solitary, unilocular defect was noted along the medial aspect of the body of the mandible in axial and coronal sections and also in the three-dimensional reformatted image (Fig. 2a-c). The lesion measured 10.87 mm mediolaterally, 6.36 mm buccolingually, and 5.93 mm superoinferiorly. The lower border of mandible was thin and intact. These radiographic features confirmed the diagnosis of lingual mandibular bone defect. The lesion was notified to the patient and scheduled for regular follow-up. No dimensional alterations were detected on panoramic radiograph up to 3 months after the first visit.

DISCUSSION

Lingual mandibular bone defect is a developmental defect which is seen as an invagination in the medial surface of the mandible. The various terminologies such as Stafne bone cyst, latent bone cyst, developmental salivary gland defect, static bone cavity, aberrant salivary gland defect, lingual cortical mandible defect, embryonic mandible defect, and submandibular salivary gland inclusion [4,5] suggest that the exact pathogenesis is still uncertain. Nevertheless, it is proposed that the cavity could result from a failure of normal bone deposition in the region formerly occupied by cartilage [1]. It is also been suggested that these defects result from benign fatty or vascular lesion. The most widely accepted view is that the cavities develop as a result of a localized pressure atrophy of the lingual surface of the mandible from the adjacent salivary gland [6,7]. Lingual mandibular bone defect has anterior and posterior variants. The posterior variant is the most known variant of the defect and is located between the mandibular angle and first mandibular molar tooth below the inferior alveolar canal [8-11]. The submandibular gland is directly related with the posterior variant, while the sublingual gland is related to the

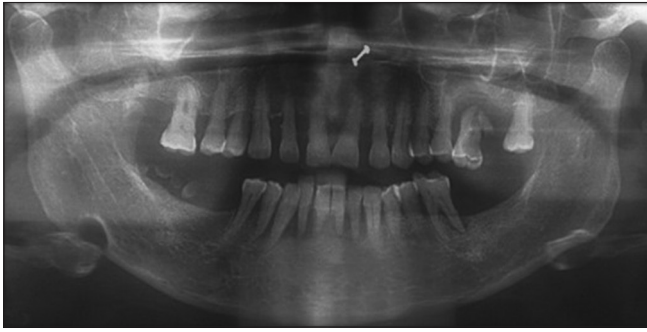


Figure 1: Panoramic radiograph showing well-defined unilocular radiolucency

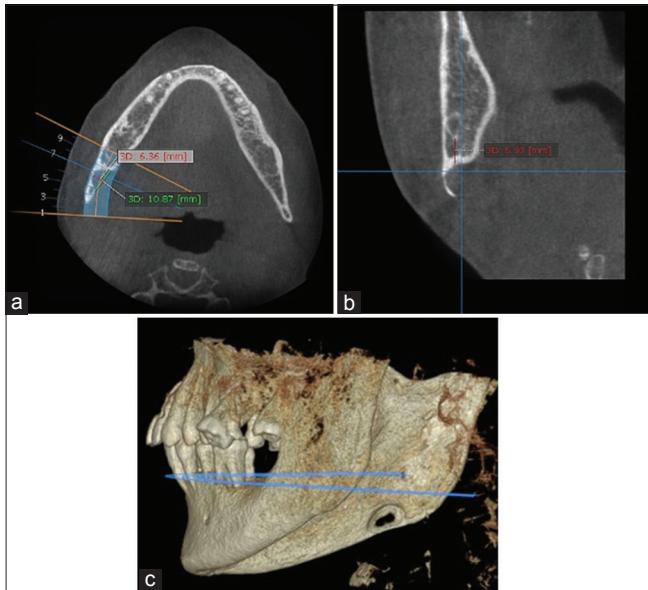


Figure 2: (a) Cone-beam computed tomography showing axial view, (b) coronal view, (c) and three-dimensional view of lingual bone cyst

anterior variant, and the parotid gland with the two variants of the ascending ramus of the mandible [5,12]. These defects are usually unilateral, occasionally bilateral. The prevalence ranges from 0.10% to 0.48%. The defect in our case was located near the right third molar region and below inferior alveolar canal and hence was a posterior unilateral variant [1,2,13-15]. It has a gender predilection for males between 50 and 70 years [15]. The lesion is asymptomatic and is encountered on a routine radiographic examination. The margins of the radiolucent defect are well-defined by a dense radiopaque line which is usually thicker on the superior aspect. This appearance is as a result of the x-rays passing tangentially through the relatively thick walls of depression. Arijji *et al.* [16] classified lingual bone defect according to the depth and content of the cavities.

According to depth, the bone defects were classified as follows:

Type I: Cavity depth is limited to the medullary portion of the mandible.

Type II: Cavity depth reaches the buccal cortex of the mandible but does not cause its expansion.

Type III: Cavity depth reaches the buccal cortex of the mandible and causes its expansion.

According to content, they were classified as follows:

Type F: Cavity is filled with fat.

Type S: Cavity is filled with soft tissue (lymph node, vessel, connective tissue, etc.).

Type G: Cavity is filled with part of the submandibular gland.

The lesions are reported to be present below the inferior alveolar nerve canal and have well-corticated borders which make their appearance distinctive and unique. However, sialadenosis, traumatic bone cyst, bone marrow defects, giant cell granuloma, or residual cyst can be considered as differential diagnosis [9]. Conventional radiographs may be inadequate for recognition of the lesion and needs to be supported with additional diagnostic techniques. Sialography, CT, and CBCT imaging techniques have been used to achieve a final diagnosis of lingual bone defect. Sialography is a diagnostic technique to determine whether glandular tissue exists in the cavity. However, this procedure is invasive and uncomfortable for the patient [17]. Gomez *et al.* proposed that CT is complementary diagnostic procedure for lingual bone defect and other cystic lesions could be distinguished with this method [18,19]. CBCT is preferred over conventional CT due to radiation dose. It allows definitive diagnosis and can be used in follow-up period. Thus, radiographic follow-up is recommended management for lingual bone defect instead of surgery.

CONCLUSION

Lingual mandibular bone defects are rare and static lesions. It is important for the clinicians to be aware of the existence of these anatomic variations in the examination process. Cystic-appearing lesions that occur in the mandible are often difficult to distinguish from one another with radiography. Awareness of these entities can save the patient from unnecessary treatment and procedures.

REFERENCES

1. Stafne EC. Bone cavities situated near the angle of the mandible. *J Am Dent Assoc* 1942;29:1969-72.
2. Wood NK, Goaz PW editors. Radiolucencies of the jaws. In: *Differential Diagnosis of Oral and Maxillofacial Lesions*. 5th ed. Saint-Louis: Mosby; 2007. p. 316-8.
3. Segev Y, Puterman M, Boder L. Stafne bone cavity- magnetic resonance imaging. *Med Oral Patol Oral Cir Bucal* 2006;11:345-7.
4. Grellner T, Frost D, Brannon R. Lingual mandibular bone defect: Report of three cases. *J Maxillofac Surg* 1990;48:288-96.
5. Philipson H, Takata T, Reichart P, Sato S, Sueti Y. Lingual and buccal mandibular bone depressions: A review based on 583 cases from a worldwide literature survey, including 69 new cases from Japan. *Dentomaxillofac Radiol* 2002;31:281-90.
6. Boyle CA, Horner K, Coulthard P, Fleming GJ. Multiple Stafne bone cavities: A diagnostic dilemma. *Dent Update* 2000;27:494-7.
7. Kaur A. Stafne bone cyst: A case report with review of literature. *Int J Oral Health Dent* 2015;1:149-50.
8. Dorman M, Piersie D. Ectopic salivary gland tissue in the anterior mandible: A case report. *Br Dent J* 2002;193:571-2.
9. de Courten A, Knuffer R, Samson J, Lombardi T. Anterior lingual mandibular salivary gland defect (Stafne defect) presenting as a residual cyst. *Oral Surg Oral Med Oral Pathol Oral Radiol Endod* 2002;94:460-4.
10. Barker GR. Xeroradiography in relation to a stafne bone cavity. *Br J Oral Maxillofac Surg* 1988;26:32-5.

11. Reuter I. An unusual case of Stafne bone cavity with extraosseous course of the mandibular neurovascular bundle. *Dentomaxillofac Radiol* 1998;27:189-91.
12. Barker G. A radiolucency of the ascending ramus of the mandible associated with investid parotid salivary gland material and analogous with a Stafne bone cavity. *Br J Oral Maxillofac Surg* 1988;26:81-4.
13. Dereci O, Duran S. Intraorally exposed anterior Stafne bone defect: A case report. *Oral Surg Oral Med Oral Pathol Oral Radiol Endod* 2012;113:e1-e3.
14. Turkoglu K, Orhan K. Stafne bone cavity in the anterior mandible. *J Craniofac Surg* 2010;21:1769-75.
15. Campos PS, Oliveira JA, Dantas JA. Stafne's defect with buccal cortical expansion: A case report. *Int J Dent* 2010;2010:1-3.
16. Ariji E, Fujiwara N, Tabata O. Stafne's bone cavity. Classification based on outline and content determined by computed tomography. *Oral Surg Oral Med Oral Pathol* 1993;76:375-80.
17. Oikarinen VJ, Wolf J, Julku M. A stereosialographic study of developmental mandibular bone defects (Stafne's idiopathic bone cavities). *Int J Oral Surg* 1975;4:51-4.
18. Quesada-Gomez C, Valmaseda-Castellon E, Berini-Aytes L, Gay-Escoda C. Stafne bone cavity: A retrospective study of 11 cases. *Med Oral Patol Oral Cir Bucal* 2006;11:277-80.
19. Slasky BS, Bar-Ziv J. Lingual mandibular bony defects: CT in the buccolingual plane. *J Comput Assist Tomogr* 1996;20:439-43.

Funding: None; Conflict of Interest: None Stated.

How to cite this article: Sanjana R, Poornima C, Mahesh Kumar TS, Balaji P. Lingual mandibular bone defect: A case report and review. *Indian J Case Reports*. 2018;4(2):162-164.