

## Case Report

# Unilateral reexpansion pulmonary edema after tube thoracostomy: A case report

Amitesh Gupta, Parul Mrigpuri

From Department of Pulmonary Medicine, Sri Lal Bahadur Shastri Government Medical College, Mandi, Himachal Pradesh, India

**Correspondence to:** Dr. Parul Mrigpuri, Department of Pulmonary Medicine, Sri Lal Bahadur Shastri Government Medical College, Mandi at Ner Chowk, Himachal Pradesh – 175 021, India. E-mail: [parul57\\_mrigrpuri@yahoo.com](mailto:parul57_mrigrpuri@yahoo.com)

Received - 13 January 2018

Initial Review - 09 February 2018

Published Online - 23 March 2018

### ABSTRACT

We report a case of unilateral reexpansion pulmonary edema (RPE) in a patient of secondary spontaneous pneumothorax of 2 days' duration developed after tube thoracostomy. RPE is an unusual but life-threatening complication. It may result in variable degree of hypoxemia and hypotension. Prognosis depends on early diagnosis and prompt management.

**Key words:** Hypoxemia, pneumothorax, reexpansion pulmonary edema

Reexpansion pulmonary edema (RPE) is a rare but potentially life-threatening complication with a poor prognosis if not diagnosed promptly particularly after rapid drainage of massive pleural effusion or pneumothorax either by aspiration or tube thoracostomy. The incidence of RPE reported in literature varies from 0.9% to 29.8%, and the mortality rate associated with RPE can be as high as 20% [1]. The risk factors for developing RPE are young age (<40 years), prolonged lung collapse (>4 days), large effusion or pneumothorax (>30% of hemithorax), and timing of reexpansion of the lung [2]. Endotracheal intubation and mechanical ventilation may be required. Majority of young patients without any comorbid illness recover, but in others, death occurs due to hypoxemia and hypotension if prompt management is not done. We report a case of unilateral pulmonary edema developed within 4 h of tube thoracostomy done in a 61-year-old male diagnosed with secondary spontaneous pneumothorax.

### CASE REPORT

A 61-year-old male patient was admitted in respiratory ward with the complaints of sudden onset breathlessness for the past 2 days, with symptoms increasing in severity without any diurnal or postural variation. The patient was also having chest pain on the right side which was diffuse, sharp, and non-radiating in nature. There was no history of trauma, paroxysmal nocturnal dyspnea, sweating, hypertension, hemoptysis, or diabetes mellitus. There was no similar history in the past. He was a chronic active smoker with no history of illicit drug abuse.

On general examination, he had a pulse rate of 114/min, blood pressure of 110/70 mm Hg, and oxygen saturation (Spo<sub>2</sub>) of 92% at room air with no cyanosis but evident dyspnea. Respiratory system examination was suggestive of decreased chest movements with hyper-resonant note on the right side over all lung fields.

On auscultation, breath sounds were absent on the same side. A provisional diagnosis of pneumothorax was kept which was confirmed with chest X-ray (Fig. 1).

An immediate intercostal tube (ICT) insertion 28 F was inserted in 5<sup>th</sup> intercostal space in midaxillary line on the right side. His dyspnea was relieved, and his saturation improved to 97% at room air. However, after few hours, the patient had a continuous dry cough for 10 min associated with increased breathlessness and right-sided chest pain. His pulse rate rose to 120/min with a drop-in blood pressure to 100/60 mm Hg. His saturation also dropped to 85% at room air. ICT position was confirmed, and the patient was started on supplemental oxygen with non-invasive ventilation support. Chest X-ray was done which showed a homogenous alveolar opacity on the right side with crepitations on auscultation and a diagnosis of unilateral RPE was made (Fig. 2).

Computed tomography (CT) chest was also done which revealed ground glass opacities with interlobular septal thickening on the right side (Fig. 3). The patient was closely monitored for 24 h and supplemental oxygen with non-invasive ventilation (NIV) was continued. Symptoms resolved after 24 h and follow-up chest X-ray showed completely expanded lung with no evidence of pulmonary edema (Fig. 4). ICT was removed on 3<sup>rd</sup> day. On follow-up, the patient was doing well with no fresh problems.

### DISCUSSION

RPE was first described by Carlson *et al.* in 1959 that occurred after management of pneumothorax [3]. Usually, RPE is a self-limiting asymptomatic complication, but mortality rate of 20% has been described in the literature [1]. Our patient had a short duration of pneumothorax of 2 days as per history which may have resulted in the good outcome. A high index of suspicion was

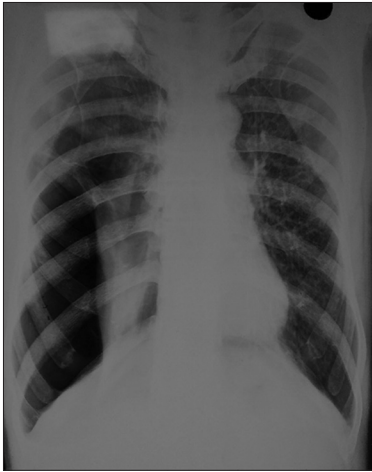


Figure 1: Chest X-ray showing right pneumothorax

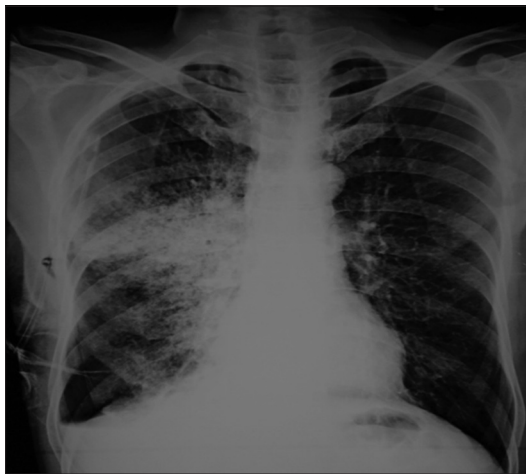

Figure 2: Chest X-ray showing homogenous opacity on the right side with intercostal tube in place and minimal pneumothorax

kept, and he was managed with supplemental oxygen and NIV support. The exact mechanism responsible for RPE is not known, but cause may be multifactorial. Many studies have shown it to develop after microvasculature injury resulting in permeability edema [4]. There is thickening of capillary endothelium and basement membrane due to prolonged lung collapse. On lung reexpansion, these altered vessels get damaged due to stretching resulting in the development of RPE.

Second hypothesis is the release of inflammatory mediators such as interleukin-8 and monocyte chemoattractant protein-1 causing RPE [5]. One study has also reported increased hydrostatic pressure as the cause [6]. Reperfusion injury has also been described as the cause for the development of RPE in literature [7].

The diagnosis can be made keeping a high index of suspicion based on history, clinical examination, and radiology. The patient typically develops worsening dyspnea and chest pain which may or may not be associated with dry cough particularly few minutes after the procedure done for pleural drainage. The management is generally supportive with supplemental oxygen, volume replacement, lateral decubitus positioning with affected side down to improve oxygenation, and NIV for mild hypoxemia.

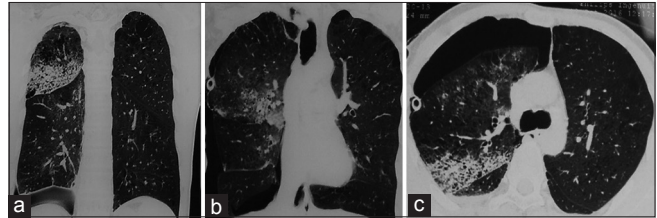


Figure 3: Computed tomography (CT) chest (a and b) coronal section showing evidence of edema in the right lung. CT chest (c) axial section showing pneumothorax with immediate intercostal tube tip along with ground glass opacities and interlobular septal thickening on the right side

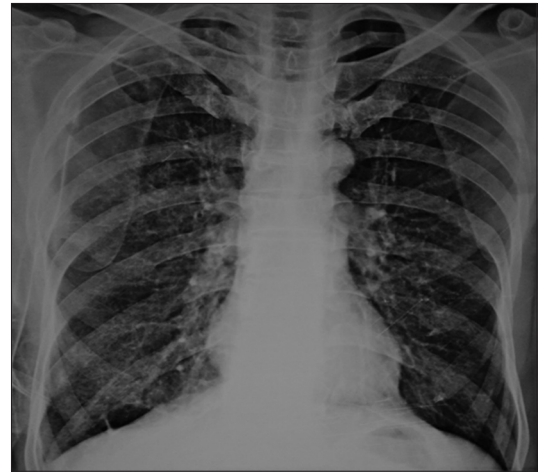

Figure 4: Chest X-ray showing expanded lung and resolution of pulmonary edema

Severe hypoxemia may require mechanical ventilation. Diuresis should be avoided due to volume depletion [8]. RPE may be prevented by allowing slow decompression; the volume of fluid being drained during thoracentesis should usually be limited to 1–1.5 L. The ICT should be first connected to underwater seal drainage bag rather than applying negative pressure.

## CONCLUSION

RPE is a rare but potentially life-threatening complication occurring after rapid pleural drainage procedures in massive pleural effusion and pneumothorax. Clinician should know about this complication and associated risk factors particularly if there is worsening of patient's condition after initial improvement.

## REFERENCES

1. Echevarria C, Twomey D, Dunning J, Chanda B. Does re-expansion pulmonary oedema exist? *Interact Cardiovasc Thorac Surg* 2008;7:485-9.
2. Matsuura Y, Nomimura T, Murakami H, Matsushima T, Kakehashi M, Kajihara H. Clinical analysis of re-expansion pulmonary Edema. *Chest* 1991;100:1562-6.
3. Carlson RI, Classen KL, Gollan F, Gobbel WG Jr., Sherman DE, Christensen RO. Pulmonary Edema following the rapid re-expansion of a totally collapsed lung due to a pneumothorax: A clinical and experimental study. *Surg Forum* 1958;9:367-71.
4. Doerschuk CM, Allard MF, Oyarzun MJ. Evaluation of re-expansion pulmonary Edema following unilateral pneumothorax in rabbits and the effect of superoxide dismutase. *Exp Lung Res* 1990;6:355-6.

5. Nakamura H, Ishizaka A, Sawafuji M, Urano T, Fujishima S, Sakamaki F, *et al.* Elevated levels of interleukin-8 and leukotriene B4 in pulmonary edema fluid of a patient with re-expansion pulmonary Edema. *Am J Respir Crit Care Med* 1994;149:1037-40.
6. Sue RD, Matthay MA, Ware LB. Hydrostatic mechanisms may contribute to the pathogenesis of human re-expansion pulmonary Edema. *Intensive Care Med* 2004;30:1921-6.
7. Sivrikoz MC, Tuncozgun B, Cekmen M, Bakir K, Meram I, Kocer E, *et al.* The role of tissue reperfusion in the re-expansion injury of the lungs. *Eur J Cardiothorac Surg* 2002;22:721-7.
8. Light RW, editor. Thoracentesis and pleural biopsy. In: *Pleural Disease*. 4<sup>th</sup> ed. Baltimore: Williams and Wilkins; 2003. p. 358-77.

*Funding: None; Conflict of Interest: None Stated.*

**How to cite this article:** Gupta A, Mrigpuri P. Unilateral reexpansion pulmonary edema after tube thoracostomy: A case report. *Indian J Case Reports*. 2018;4(2):92-94.