

Case Report

Audiological findings in individual with glomus tympanicum: A case report

Kavitha Vijayakumar, Innamul Hassan, Deepika Jayachandran, Shamangi Nakhare

From, Department of Audiology, MERF - Institute of Speech and Hearing (P) Ltd, Chennai, Tamil Nadu, India

Correspondence to: Ms. Deepika Jayachandran, Department of Audiology, MERF - Institute of Speech and Hearing (P) Ltd, New No: 1, Old No: 1/1 South Canal Bank Road, Mandaivelipakkam, Chennai, Tamil Nadu, India. Phone: +91- 9986974065, E-mail: deepika.jayachandran@gmail.com

Received - 12 December 2017

Initial Review - 24 January 2018

Published Online - 24 February 2018

ABSTRACT

Parangliomas are also called glomus tumors, a rare, neuroendocrine neoplasm that arises from the paraganglia in the glomus cells derived from the embryo in the neural crest of the sympathetic nervous system (a branch of the autonomic nervous system). This case report is on glomus tympanicum on the right side in a 36-year-old male presented with pulsatile tinnitus and ear pain. On otoscopic examination and radiological findings, it appears as a reddish mass behind the tympanic membrane. The pre-operative and the post-operative audiological findings are profiled and discussed.

Key words: *Glomus tumors, Glomus tympanicum, Parangliomas*

Parangliomas are also called glomus tumors, which arise from paraganglia in the glomus cells and are derived from the embryo in the neural crest of the sympathetic nervous system (a branch of the autonomic nervous system [ANS]) [1]. Glomus tympanicum is one of the types of glomus tumor, which is a rare, neuroendocrine neoplasm and may develop at any site in the body. It is stated as the most common primary neoplasm of the middle ear which is 0.6% of the head and neck, 0.03% of all the neoplasms [2] and it is the second most common tumor of the temporal bone [3]. It leads to occlusion of the middle ear space, leading to conductive hearing loss and in case of large tumors can cause sensorineural component as well. The diagnosis of glomus tympanicum is by otoscopic examination, and the primary diagnosis is with the help of computed tomography (CT) and magnetic resonance imaging (MRI) scans. The treatment options for the glomus tympanicum tumors are based on the individual properties of the tumor [4]. Due to its slow progress, observation at each level of the tumor growth and the evaluation of symptoms are very important. The surgical removal options range from relatively simple transcanal approaches to much more complex mastoid and petrous operations depending on the size, location of the tumor, and extent of other structures involved. This case reports the importance of hearing preservation even after the surgical excision of the glomus tympanicum tumor.

As the tumors are present inside the middle ear space, there is no significant appearance of any tumor growth. The most often noticed symptom is the pulsatile tinnitus which is due to the flow of blood into the vessels of the tumor. Other symptoms which are reported are the conductive hearing loss (which is due to the blocking of the tumor, thereby affecting the transmission of the sound), ear pain, and occasionally bleeding from the ear due to the rupture of the blood vessels which is seen in severe cases [2,5]. Dizziness is also presented as a symptom rarely in some

cases as the signs for the disorder vary with the size of the tumor [6,7]. The signs and symptoms of these tumors vary according to individual patient, the nature of the tumor and extent/spread of the tumor. Hence, this report provides the pre- and post-operative profiles of a patient with glomus tympanicum.

CASE REPORT

A 36-year-old male presented to the otolaryngology outpatient department with the complaint of sound (pulsatile tinnitus) in the right ear for the past 1 year duration and ear pain on the right side for 1 month. The patient's history revealed reduced hearing sensitivity in the right ear. However, on otoscopic examination, there was an appearance of reddish mass behind the right tympanic membrane and normal tympanic membrane in the left ear was noticed. Pure tone audiometry revealed minimal to mild conductive hearing loss on the affected side and the left ear revealed normal hearing thresholds. Immittance audiometry revealed "A" type tympanogram in both ears.

Further, as a part of pre-operative evaluation, the patient had undergone radiological evaluation, the CT scan revealed soft tissue lesion in hypotympanum abutting towards promontory, identified as glomus tympanicum associated with cholesteatoma. MRI was done and the results revealed small enhancing soft tissue lesion in the hypotympanum and it is abutting the promontory, it is also abutting the right jugular bulb which was very prominent. These findings inferred to be glomus tympanicum.

The above Fig. 1 depicting the hearing thresholds of the patient preoperatively, and based on the pre-operative radiological findings, the patient was advised for the excision of the tumor on the right side. The patient had undergone transcanal-transmastoid posterior tympanotomy approach for the same.

After the surgical management, the patient had undergone audiological evaluation and the results revealed hearing sensitivity within normal limits in both ears, as depicted in Fig. 2, and the immittance audiometry revealed, “As” type tympanogram in the right ear and “A” type tympanogram in the left ear.

Further, the post-operative radiological evaluation revealed mild enhancement of the soft tissue thickening noted in the right mesotympanum and hypotympanum which is engulfing the long process of incus and stapes with no obvious evidence of erosion were noticed. Follow-up audiological evaluation was done after 5 years and the hearing thresholds were within normal limits in both ears, as depicted in Fig. 3. The immittance audiometry revealed “As” type tympanogram in the right ear and “A” type tympanogram in the left ear. There was no recurrence of the tumor. The tinnitus was subsided and there was no ear pain in the right ear.

DISCUSSION

Small collections of paraganglionic tissue form the glomus bodies, these types of cells are derived from the embryonic neuroepithelium in close association with the ANS. Glomus

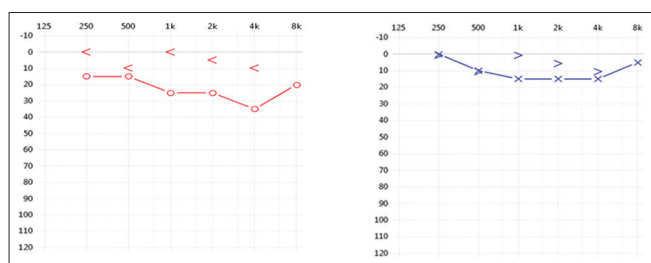


Figure 1: The pure tone audiometric results of the patient with glomus tympanicum in the right ear (pre-operative)

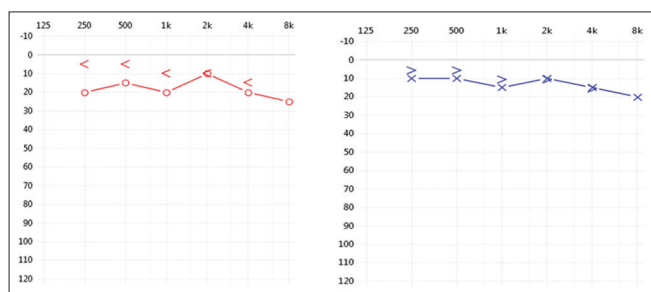


Figure 2: The pure tone audiometric results of the patient after the excision (post-operative) of the glomus tumor in the right ear

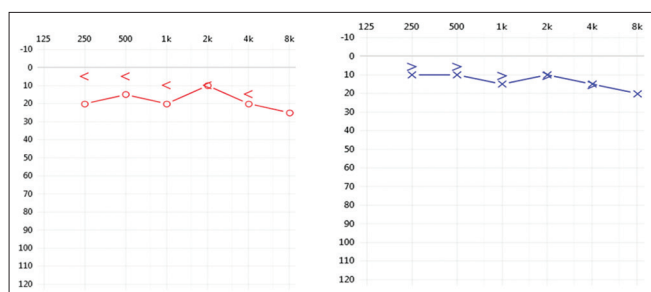


Figure 3: The pure tone audiometric results after 5 years of surgery (follow-up evaluation)

tumors are dense matrix of connective tissue among the nerve fascicles. These tumors expand within the temporal bone through the pathways of least resistance such as air cells, vascular lumens, skull base foramina, and the Eustachian tube. They also invade and erode bone in a lobular fashion, but they often spare the ossicular chain. The parenchyma of the paraganglia consists of two primary cell types. Type I cells are more common and are typically round with indistinct cell borders. Type II cells are smaller and irregularly shaped. The Glasscock-Jackson and Fisch classifications of glomus tumors are widely used. The Fisch classification of glomus tumors is based on the extension of the tumor to surrounding anatomic structures and is closely related to mortality and morbidity. This tumor falls under the category of Type A tumor.

- Type A tumor - Tumor limited to the middle ear cleft (glomus tympanicum).

The optimal treatment option for glomus tympanicum of the temporal bone is still controversial. The management options depend on the size of the tumor, location, and general status of the patient. The treatment option is the surgical excision of the tumor, initial radiotherapy, and the continuous observation of the patient. The aim is the resection of the tumor for the well-being of the patient using approaches such as postauricular transcanal tympanotomy approach and open/closed cavity mastoidectomy with tympanoplasty [8].

Radiation therapy is an alternative treatment for these types of tumors because this serves as a good response with low level of complications and has a long-term clinical control of these glomus tympanicum tumors [9]. It is stated that these tumors may occur at the sixth or seventh decade of life due to poor health conditions. Observation in cases of elderly people is necessary because the growth of the tumor is slow and the necessary management options depend on the process of the development of the tumor.

CONCLUSION

This case revealed the audiological findings, the location, and the extent of the tumor. The management options include radiation therapy and surgical management, which depends on the size of the tumor. Radiation therapy can also be considered based on the individual findings. This case discussed above shows how the patient has regained his hearing after the surgical excision of the tumor. Therefore, early detection leads to the preservation of the hearing and improvement in the quality of life.

REFERENCES

1. Dixon A, Galliard F. Middle Ear Tumors; 2016. Available from: <https://www.radiopaedia.org/articles/middle-ear-tumours>.
2. Manan AA, Mohammad I, Nik Othman NA, Sofi AI. A rare cause of common symptom: Glomus Tympanicum. *Int Med J* 2016;23:494-5.
3. O’Leary MJ, Shelton C, Giddings NA, Kwartler J, Brackmann DE. Glomus tympanicum tumors: A clinical perspective. *Laryngoscope* 1991;101:1038-43.
4. Singh VK, Badhwar S, D’Souza J, Indrajit IK. Glomus tympanicum. *Med J Armed Forces India* 2004;60:200-3.

5. Pluta RM. Glomus Jugulare Tumors. Available from: <https://www.emedicine.medscape.com/article/251009-overview>. [Last accessed on 2017 Jun 14].
6. Hain TC. Glomus Tumors, Dizziness and Balance. Available from: <https://www.dizziness-and-balance.com/disorders/tumors/glomus.html>. [Last accessed on 2011 Jan 25].
7. Jyung RW. Hearing and Balance Disorders-Glomus Tumors. Newark, NJ, USA: UMDNJ/New Jersey Medical School, American Hearing Research Foundation; 2012.
8. Mahadevaiah A, Parikh B, Kumaraswamy K. Surgical management of glomus tympanicum tumor. *Indian J Otolaryngol Head Neck Surg* 2007;59:5-8.
9. Konefal JB, Pilepich MV, Spector GJ, Perez CA. Radiation therapy in the treatment of chemodectomas. *Laryngoscope* 1987;97:1331-5.

Funding: None; Conflict of Interest: None Stated.

How to cite this article: Vijayakumar K, Hassan I, Nakhare S, Jayachandran D. Audiological findings in individual with glomus tympanicum: A case report. *Indian J Case Reports*. 2018;4(1):43-45.