

## Case Report

## Radiological diagnosis of Cysticercosis of Breast - An unusual presentation

Sharma BB<sup>1</sup>, Jilowa S<sup>1</sup>, Kumar S<sup>2</sup>, Bhardwaj A<sup>1</sup>, Singh Y<sup>1</sup>, Mishra RK<sup>1</sup>

From 1Department of Radio diagnosis & 2Surgery, Post Graduate Institute of Medical Education and Research & Dr. Ram Manohar Lohia hospital, New Delhi, India

**Correspondence to:** Dr Bharat Bhushan Sharma, B-32, Nivedita Kunj, Sector 10, R K Puram, New Delhi – 110022. E mail: [bbhushan986@gmail.com](mailto:bbhushan986@gmail.com) Tel No +91 11 26182700

Received: 28 November 2014 Initial Review: 28 December 2014 Accepted: 31 December 2014 Published online: 06 January 2015

## ABSTRACT

Breast cysticercosis manifestation is usually uncommon and only a few cases have been reported in the literature. This manifests in the form of signs and symptoms which normally do not point towards the diagnosis. The radiological modalities always narrow down the gap between the complaints and the diagnosis. We present a case with cysticercus cysts in breast parenchyma as well as in both pectoral muscles which was suspected on ultrasonography (USG) and diagnosed on Magnetic Resonance Imaging (MRI). The patient responded to the medical treatment conservatively thus avoiding excisional biopsy. Follow up and repeat MRI has confirmed the cure of the complaints as well as the disease.

**Key words:** *Cysticercosis, Magnetic Resonance Imaging (MRI), Radiological modalities, Ultrasonography*

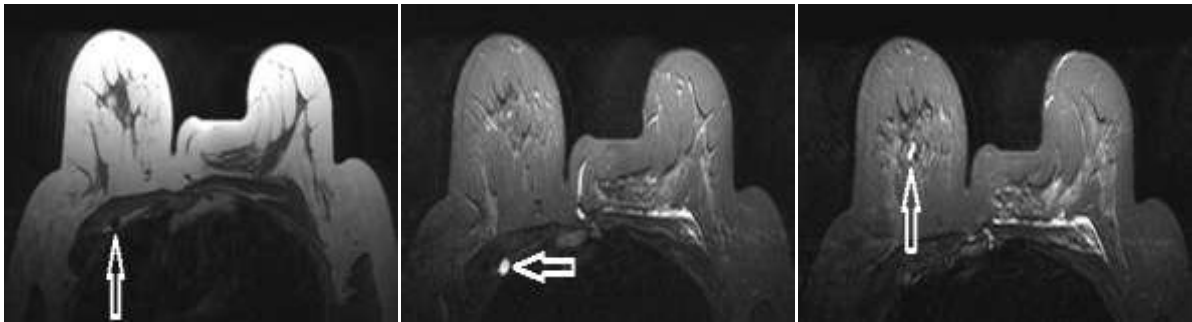
Cysticercosis is a parasitic infection caused by *cysticercus cellulosae* which can affect any organ or tissue of the body. The common sites encountered are skeletal muscles, subcutaneous tissues, brain and eye. Occasionally the heart, lung, liver, kidney and bone may also be involved. The patients with breast cysticercosis usually present with a painful or painless lump in the breast. It can affect all the age groups and cases have been reported in patients as young as 16 yrs to as old as 63 yrs. USG and MRI, being non-invasive and radiation free modalities, have a promising role in diagnosis and follow up of these patients. This may also help avoiding unnecessary surgical interventions.

## CASE REPORT


A 29 year old female presented with complaints of pain in the right breast and anterior chest wall of two years duration. The pain used to increase on movement of right shoulder and right arm. There was no associated history of fever. Biochemical tests and parameters were normal. The

clinical examination of bilateral breasts revealed an ill-defined, non-tender (2x2cm) palpable lump in outer upper quadrant of right breast with normal nipple-areolar complex. There was mild tenderness in the anterior axillary fold on right side. Left breast did not reveal any abnormality and was normal on clinical examination. There was no other complaint suggestive of any other focus in musculoskeletal regions in the body.

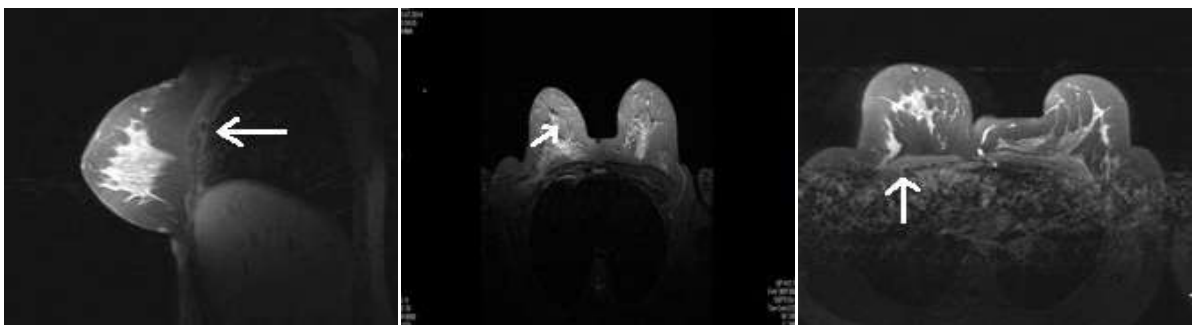
Mammography of right breast did not reveal any definitive lesion. USG of the breasts revealed two small cystic lesions in fibroglandular tissue of right breast measuring 8 mm each. A hypoechoic cystic lesion measuring 2x1.6 cm was also seen in left pectoralis major muscle with central echogenic focus. The right pectoralis major muscle was reported as normal. Provisional diagnosis of cysticercosis of breast was made and for further evaluation and confirmation of diagnosis, MRI chest region was done. MRI revealed two well defined round to oval cystic lesions measuring 7.8 mm each hypointense on T1W and hyperintense on T2W in right breast parenchyma (Fig 1 a, b and c).



**Figure 1 a, b and c – Non-contrast MRI Axial sections of both breasts. (a) T1W image shows hypointense cystic lesion (arrow) in deep pectoralis muscle of the right side and bulky left pectoral muscle. (b) T2W image at the same location shows hyperintense lesion (horizontal arrow). (c) T2W image shows twin hyperintense parenchymal lesions in right breast (arrow).**



**Figure 2 - Contrast enhanced MRI breast. (a) T2W Axial section of left breast shows hyperintense lesion (arrow) with hypointense rim seen in pectoralis major muscle. (b) T2W Sagittal section shows same lesion with well defined margins (arrow)**



**Figure 3 a, b and c – Contrast enhanced MR breast. (a) T1W Sagittal section of the right breast shows intramuscular cystic lesion with enhancing wall and scolex (arrow) resembling cyst with dot appearance. (b) T1W Axial section the same intramuscular lesion (arrow) with enhancing bulky pectoralis muscle. (c) Post treatment T1W Contrast enhanced axial section has shown regression of right breast parenchymal and muscular lesions (arrow).**

Another well-defined cystic lesion of similar intensity measuring 0.95 mm was noted in right pectoralis major muscle showing post-contrast enhancement of mural nodule (Fig 2 a, b and 3 a, b). Left pectoralis major was bulky and had a cystic lesion with surrounding edema and

heterogenous enhancement (Fig 2 a, b). Possibility of chronic inflammatory granulomatous lesions like cysticercosis was considered in view of multiple lesions in the right breast and in both pectoral muscles, in a patient living in countries like India. MRI brain was done to look

for any concomitant cerebral lesions and was found to be normal.

Patient was treated with oral albendazole (15 mg/kg/day in 2 divided doses) for four weeks along with analgesics. Patient responded to the treatment and had symptomatic relief. There was also disappearance of the right breast lump during the course of albendazole. The patient was closely followed up and follow up MRI was done after three months of therapy. MRI showed two small crumpled barely visible lesions in upper outer quadrant of right breast. Lesions in both pectoral muscles were completely resolved (Fig 3 c).

## DISCUSSION

Cysticercosis is caused by encysted larvae of pork tapeworm called *Taenia solium* and it is endemic in countries like Mexico, Eastern Europe, Africa, South East Asia, and Latin America. Cysticercosis is common in rural areas of developing countries. The organism is transmitted to humans by ingestion of eggs from contaminated water or food or through autoinfection [1]. The eggs hatch in small intestine, release oncospheres which penetrate the bowel mucosa and finally blood stream to reach to various other organs of the body to develop into cysticercus cellulosae.

Cysticercus may remain viable for years without inducing host inflammatory response. When the larvae dies, it induces vigorous granulomatous inflammatory response with resultant clinical manifestations depending on the organ involved [2,3]. The most frequent sites of involvement are muscles of the upper arm, chest wall, eye, abdominal wall, neck followed by tongue, face and breast. Involvement of breast substance by cysticercosis is not uncommon and it should be included in the differential diagnosis for a lump in the breast like in our case. Clinical symptoms of the cysticercosis depend on the number and site of involvement as well as the extent of associated inflammation. Clinical diagnosis of breast cysticercosis is often difficult and lesions may mimic as fibroadenoma [4]. Cysticercosis should be considered in a patient living in endemic area if a cystic lesion is found in or near the pectoral muscle and should be included in differential diagnosis of lump in the breast [2].

The diagnosis has usually been made by needle/excision biopsy and is correlated with

histopathological examination in earlier reports [5]. USG and MRI can play a vital role in characterization of these lesions, being non-invasive modality with no risk of radiation. USG is the best modality of imaging to differentiate between cystic and solid lesions. This can also highlight the internal echoes of the lesions with distal enhancement or shadowing [6-7]. Intramuscular cysts are oriented in the direction of muscular fibres. For localization of small lesions not detectable by both mammography and ultrasonography, MRI can be an invaluable tool.

MRI is helpful in depicting number, location and stages of parasites. Cysticercosis on MRI is seen as cystic lesion that appears hyperintense on T2W and hypointense on T1W images. Scolex appears as a tiny hypointense speck within the hyperintense cyst. Peripheral rim enhancement of cyst wall is also seen on contrast images as in our case. MRI may show a high intensity, 2-4 mm mural nodule, depicting the scolex in the interior of parenchymal cysts. These are pathognomonic of cysticercosis on gadolinium enhanced images which corresponds to the active parenchymal form of the cyst [8]. Susceptibility weighted imaging has been used in detecting calcifications in cysticercus cysts in brain and also in breast [9].

European College of Radiology, 2013 on neurocysticercosis considered cystic lesions showing scolex on CT/MRI as absolute criteria and spontaneous resolution of small ring enhancing lesions with albendazole as major criteria for the diagnosis. Our case showed spontaneous resolution on medical therapy. MRI can play a role in follow up of these cases after medical treatment, thus avoiding unnecessary biopsy and excision of lumps.

## CONCLUSION

Breast Cysticercosis is uncommon lesion but not rare. Cysticercosis should be included in the differential diagnosis of breast lumps in patients especially living in endemic countries and presenting with multiple cystic lesions with scolex, particularly associated with lesions in pectoral muscles. USG is the initial modality to know about the consistency and morphology of the lesions. MRI has a promising role in the diagnosis and follow-up of these cases, thus avoiding unnecessary excision biopsy and intervention.

## REFERENCES

1. Gonzalez AE, Evans CA, Gilman RH. Cysticercosis: Working Group in Peru. *Taenia solium* Cysticercosis. *Lancet*. 2003;362:547-56.
2. Agnihotri, Talwar OP, Pudasaini S, Baral R. Cysticercosis of Breast – A Case Report. *Pol J Pathol*. 2006;57(1):53-4.
3. Lucarelli AP<sup>1</sup>, Martins MM, de Oliveira VM, Rinaldi JF, Roveda D Jr, Galvão MA, et al. Short Report: Cysticercosis of the Breast, a Rare Imaging Finding. *Am J Trop Med Hyg* 2008;79(6):864-5.
4. Karthikeyan TM, Manimaran D, Mrinalini VR. Cysticercosis of Breast which mimicked a Fibroadenoma: A rare presentation. *J Clin Diagn Res* 2012;6(9):1555-6.
5. Sahai K, Kapila K, Vernana K. Parasites in fine needle aspirates-Assessment of host tissue response. *Postgrad Med J* 2002;78(917):165-7.
6. Upadhyaya V, Narain D, Sarkar S. Cysticercosis of Breast. *J Diagn Med Sonography* 2009;26(1):35-8.
7. Naik D, Srinath MG, Kumar A. Soft tissue cysticercosis - Ultrasonographic spectrum of the disease. *Musculoskeletal* 2011;1(1):60-2.
8. Rahalkar MD, Shetty DD, Kelkar AB, Kelkar AA, Kinare AS, Ambardekar ST. The many faces of cysticercosis. *Clin Radiol* 2000;55(9):668-74.
9. Wu Z, Mittal S, Kish K, Yu V, Hu J, Haacke EM. Identification of calcification with MRI using susceptibility - weighted imaging: a case study. *J Magn Reson Imaging* 2009;29:177-82.

---

**How to cite this article:** Sharma BB, Jilowa S, Kumar S, Bhardwaj A, Singh Y, Mishra RK. Radiological diagnosis of Cysticercosis of Breast - An unusual presentation. *Indian J Case Reports*. 2015;1(1):1-4.

*Conflict of interest: None stated, Funding: Nil*

---