

## Case Report

## Importance of Conventional Radiography in Diagnosis and Management of Giant Cell Tumour at an unusual location

Sarita Jilowa<sup>1</sup>, GC Verma<sup>2</sup>, BB Sharma<sup>1</sup>, Jitendra Singh<sup>2</sup>, Yashvant Singh<sup>1</sup>, RK Mishra<sup>1</sup>, Atul Bhardwaj<sup>1</sup>

From, <sup>1</sup>Department of Radiodiagnosis, PGIMER & RML Hospital, and <sup>2</sup>Department of Orthopaedics, Dr. Baba Saheb Ambedkar Hospital, New Delhi, India

**Correspondence to:** - Associate Professor, Department of Radiodiagnosis, PGIMER & RML Hospital, New Delhi. E mail: [saritajilowa@gmail.com](mailto:saritajilowa@gmail.com)

Received: 12 March 2015

Initial Review: 01 May 2015

Accepted: 06 May 2015

Published Online: 23 May 2015

### ABSTRACT

Giant cell tumour (GCT) or osteoclastoma of the bone is mostly benign but locally aggressive primary tumour of unknown origin occurring at epiphysis. It is a tumour of long bones and rarely seen in bones of hand and foot. The cases are reported in tarsal and carpal bone but involvement of metatarsal bone is very rare. We present a case of twenty years old female patient with GCT of second metatarsal of left foot. The patient underwent aggressive curettage and filling with bone chips and is on regular follow up.

**Keywords:** Bone, Curettage, Giant cell tumour, Metatarsal, Osteoclastoma

**G**iant cell tumour (GCT) of bone is a benign aggressive tumour which carries a high risk of local recurrence. This tumour is known to have a potential for metastasis and malignant transformation [1]. It commonly affects skeletally mature patients between the ages of 20 and 40 years with peak incidence being in third decade [2]. This tumour is rarely seen in patients with open growth plates. The patients usually present with pain, swelling and sometimes with pathological fracture.

### CASE REPORT

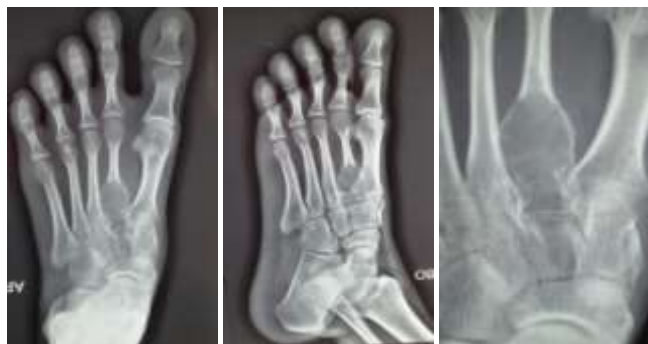A 20 years old female patient came to orthopaedic Out Patient Department with complaints of pain over the dorsal aspect of left foot of four months duration. The pain was insidious in onset and mild to moderate in intensity. It was non-radiating, intermittent in nature and there was no relief with medication. There was some relief with rest but got aggravated on walking. The pain was associated with swelling over the base of second metatarsal of left foot.

There was no history of fever, weight loss or trauma. There was no history of any treatment taken earlier.

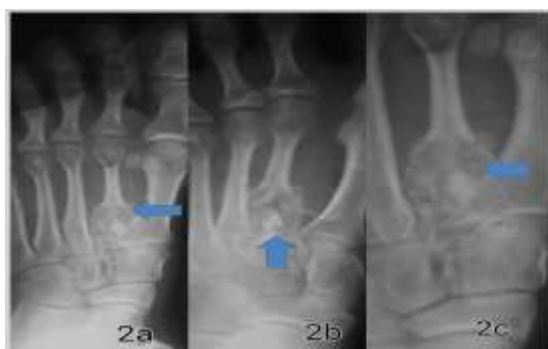
On examination, there was ovoid shaped firm swelling on the dorsum of foot which was tender on deep palpation. Local temperature was not raised and there was no redness of overlying skin. The skin was stretched but overlying vessels were not prominent. All the routine laboratory investigations such as complete blood count, ESR, random blood sugar, serum calcium and alkaline phosphatase were within normal limits. Thyroid profile was also normal. Provisional diagnosis of bony cyst or enchondroma was made and investigations were planned.

Plain X- ray of left foot has shown an epiphyseal expansile lytic lesion of the second metatarsal bone. There were multiple thin trabeculations associated with cortical thinning without pathological fracture (Figure 1a, b and c). Rest of the bones were normal and there was no extension

beyond the joint. The working diagnosis of GCT was made on the basis of the clinical and radiological findings.



**Figure 1: Plain radiographs of Left foot. (a) AP, (b) Lateral and (c) magnified AP views. There is an expansile lesion of GCT of epiphyseal region of second metatarsal with multiple thin inner trabeculations.**



**Figure 2: Post operative plain radiographs of same patient after curettage and filling with bone chips (a) AP, (b) lateral and (c) magnified AP view. There is good post operative response without any complications (arrows).**

The curettage was done with filling of cavity with bone graft taken from iliac crest. Biopsy of the curettage sample consisted of bone chips measuring 3x1x1cm and sent for microscopic examination. Examination revealed round to oval sheets of elongated mononuclear cells with an open chromatin intimately admixed with numerous osteoclasts like giant cells. No significant mitotic activity reported. The tumour was focally eroding surrounding bone and reactive bone formation at periphery was also evident. No sarcomatous change was evident. All these features were suggestive of giant cell tumour.

The “below knee cast” was applied for six weeks and full weight bearing was allowed after three months. Follow up after six months has shown no recurrence either clinically or radiologically (Figure 2a, b and c). At the time of follow up there was no pain on full weight bearing.

## DISCUSSION

GCT is a distinctive neoplasm known for its variable behaviour. It is an aggressive and potentially malignant lesion. It occurs de novo or sometimes in lesions of paget’s disease. GCT is seen in long bones in 85-90% of cases. 50% of these cases are seen in the region of knee. Lower femur, upper tibia, distal radius, proximal humerus and fibula are frequent sites while it rarely involves small bones [3]. Unni has reported an incidence of 4% in iliac bone, spine and sacrum. Only 2% of GCTs are noted in hand and 1.5% in foot, mostly in phalanges and tarsal bones [4]. GCT of metatarsal bone is very rare as seen in our case.

These tumours are characterised by extensive bony destruction with high recurrence rate. GCT of small bones of hand and foot is noted to have some peculiar features as compared to GCT at other sites. GCTs of small bones are seen predominantly in females of younger age group. These have shorter duration of symptoms with an average of six months or less and more aggressive behaviour than GCT of long bones. Biscaglia et al demonstrated the multifocal trend and high recurrence rate with pulmonary metastasis while evaluating cases of GCT for 50 years from a single institute. Out of total 21 cases of GCT of small bones of foot, 18 were in tarsal bones, 9 in talus and only three were found in metatarsal bone [5].

The centric location of GCT in bones of hand and foot is more prevalent than the eccentric location seen at other sites. They can cause significant amount of pain and deformity due to their aggressive and recurrent nature [6]. 15% to 60% recurrence rate has been reported within 3 years of first surgery. Recurrence may be primary or secondary following treatment particularly radiotherapy. These lesions should be followed up regularly because of small but definitive risk of malignant transformation [7]. The lesions are treated successfully with curettage and packing with bone chips as has been done in our case.

There is need of high index of suspicion when evaluating any tumour of foot and GCT should be considered in differential diagnosis of destructive bone lesions of the foot [8]. Histological examination is necessary to confirm the diagnosis as clinical presentations as well as radiologic images are non-conclusive. GCT is a solitary lesion characterised histologically by benign appearing osteoclasts like giant cells. These may have as

many as 40-60 nuclei per cell and stromal cells that originate within the epiphysis of adults. However, the biologic behaviour of these tumours is non predictable on histological grounds. GCT must be differentiated on the basis of clinical presentation considering the age, duration of symptoms and imaging parameters.

GCT presents with classical imaging features like epiphyseal expansile lytic nature, site, extension of the tumour into soft tissue, absence of periosteal reaction and mineralised matrix. Radiographic features of GCT are non specific and may overlap with many other osteolytic lesions. These must be differentiated from aneurysmal bone cyst (ABC), giant cell reparative granuloma (GCRG), chondromyxoid fibromas, and brown tumour of hyperparathyroidism, angiosarcoma, myeloma, and expansile metastasis on the above mentioned sites. The diagnosis of ABC or GCRG is more likely if the lesion is found in metadiaphyseal location in a skeletally immature patient. These are mostly solitary but in 18% of the cases, multi centric lesions may be seen which require bone scan for diagnostic work up as well as follow up.

Curettage along with adjuvant therapy with phenol, liquid nitrogen or polymethylmethacrylate (PMMA) is considered as the standard treatment for both primary and recurrent GCT of small bones of hands and feet [9]. Reconstruction of defect after curettage with bone cement is among acceptable methods. The procedure does not affect functions of the foot [10]. Local resection of the affected metatarsal with autograft or allograft replacement is the preferred surgical treatment. The other treatment options described in the literature are simple curettage, curettage with bone grafting, enbloc resection with reconstruction of joint surface using silastic prosthetic implants, arthrodesis, amputation, radiotherapy, chemotherapy and embolization. The use of intraoperative cryogenic agents like liquid nitrogen has reduced the recurrence rate up to ten percent [11]. Our case shows the importance of conventional radiograph in diagnosing GCT; therefore, patient was operated upon at right time and the foot could be salvaged.

## CONCLUSION

The foot is the site of various lytic lesions with overlapping clinical features that result in difficulty in making the diagnosis and GCT of metatarsal is one of them. Timely diagnosis can be made if all expansile lytic

lesions undergo radiological examination supplemented with FNAC or needle biopsy to establish the diagnosis.

## REFERENCES

1. Yangisawa M, Okada K, Tajino T, Torigoe T, Kawai A, Nishida J. Clinicopathological study of giant cell tumour of small bones. *Ups J Med Sci.* 2011;116(4):265-8.
2. Pardiwala DN, Vyas S, Puri A, Agarwal MG. Pictorial essay: Giant cell tumor of bone. *Indian J Radiol Imaging.* 2001;11:119-26.
3. Mahajan S, Shikari A, Habib M, Kuchey G, Sharma S. Giant cell tumour of the second metatarsal. *The Internet Journal of Orthopedic Surgery.* 2008;11(1).
4. Unni KK. Giant cell tumor. In: Unni KK, ed. *Dahlin's bone tumours: general aspects and data on 11,087 cases.* 5<sup>th</sup> ed. Philadelphia, PA: Lippincott-Raven; 1996. pp. 263–83.
5. Biscaglia R, Bacchini P, Bertoni F. Giant cell tumour of the bones of the hand and foot. *Cancer.* 2000;88(9):2022-32.
6. Dellenbaugh SG, Wilkinson L, Aydogan U. Giant cell tumour of distal phalanx of great toe: A Case Report. *Foot Ankle Spec.* 2014;7(3):237-41.
7. Tharayil J, Patil RK. Salvage of foot with extensive giant cell tumour with vascularised fibular bone graft. *Indian J Plast Surg.* 2011;44(1):150-6.
8. Song KS, Park CH. Giant cell tumour of Talus: 19 year follow up of a patient. *J Foot Ankle Surg.* 2014; May 28. pii: S1067-2516(14)00139-2. doi: 10.1053/j.jfas.2014.04.003. [Epub ahead of print].
9. Oliveira VC, van der Heijden L, van der Geest IC, Campanacci DA, Gibbons CL, van de Sande MA, et al. Giant cell tumours of small bones of hands and feet: Long term results of 30 patients and a systematic literature review. *Bone Joint J.* 2013; 95-B(6):838-45.
10. Ozer D, Er T, Aycan OE, Oke R, Coskun M, Kabukcuoglu YS. May bone cement be used to treat benign bone tumours of the feet with confidence? *Foot (Edinb).* 2014;24(1):1-5.
11. RajaRajan NS, Basha IM. Giant cell tumour of the second metatarsal. *International Journal of Healthcare Sciences.* 2014;2(1):159-62.

*Funding: None; Conflict of Interest: None Stated*

**How to cite this article:** Jilowa S, Verma GC, Sharma BB, Singh J, Singh Y, Mishra RK, Bhardwaj A. Importance of Conventional Radiography in Diagnosis and Management of Giant Cell Tumour at an unusual location. *Indian J Case Reports.* 2015; 1(2): 38-40.