

Case Report

Multiple Dens Invaginatus - A case report and review of literature

Ambili Ayilliath*, Nandan S**, Raj A C***

*Department of Pedodontics, and **Oral Medicine & Radiology K.V.G Dental College & Hospital, Karnataka, India, **Department of Pedodontics, Pacific Dental College & Hospital, Rajasthan, India.

Correspondence to: Dr Ambili Ayilliath, Reader, Department of Pedodontics, K.V.G Dental College & Hospital, Karnataka, India. E-mail id: dr_ayilliath@yahoo.com.

Received: 11 February 2016 Initial Review: 02 March 2016 Accepted: 09 March 2016 Published Online: 30 March 2016

ABSTRACT

Dens invaginatus is a developmental variation of a tooth resulting from an alteration in the normal growth pattern of the dental papilla. It is clinically characterized by a palatine furrow that can be limited to the coronal pulp or may extend to the radicular apex. The commonly affected tooth is maxillary lateral incisor. The occurrence of multiple dens invaginatus is extremely rare. Although a clinical examination may reveal a deep pit or fissure on the lingual surfaces of maxillary anterior teeth, the radiographic examination is the choice for diagnosis of dens invaginatus. Familiarity with the radiographic appearance of this anomaly is essential for the dental practitioner. The purpose of this paper is to present a clinical case of multiple dens invaginatus involving maxillary anterior teeth which was diagnosed during routine radiographic evaluation.

Keywords: Anomaly, Dens invaginatus, Dens in dente

Dens invaginatus (DI) is a developmental anomaly resulted by a deepening or invagination of the enamel organ into the dental papilla prior to calcification of the dental tissues [1]. This kind of malformation was first described by 'Ploquet' in 1794 in whale's tooth. Salter in 1855 first described this condition as "a tooth within a tooth". It was first described in human tooth by a dentist, Socrates in 1856 [1-2]. Tomes first described a case of coronal DI in 1859 [3]. Muhltreiter in 1873 reported on 'anomalous cavities in human teeth [1].

There are various synonyms given for this developmental disturbance in the literature. The term dens invaginatus was introduced by Hallet as the enamel was located centrally and the dentine peripherally due to the invagination [3]. Busch in 1897 first suggested the use of 'dens in dente' which implies the radiographic appearance of a tooth within a tooth. Hunter (1951) suggested the term 'dilated composite odontome' which infers an abnormal dilatation of the dental papilla. The use of 'gestant anomaly' was recommended by Colby in 1956 [4].

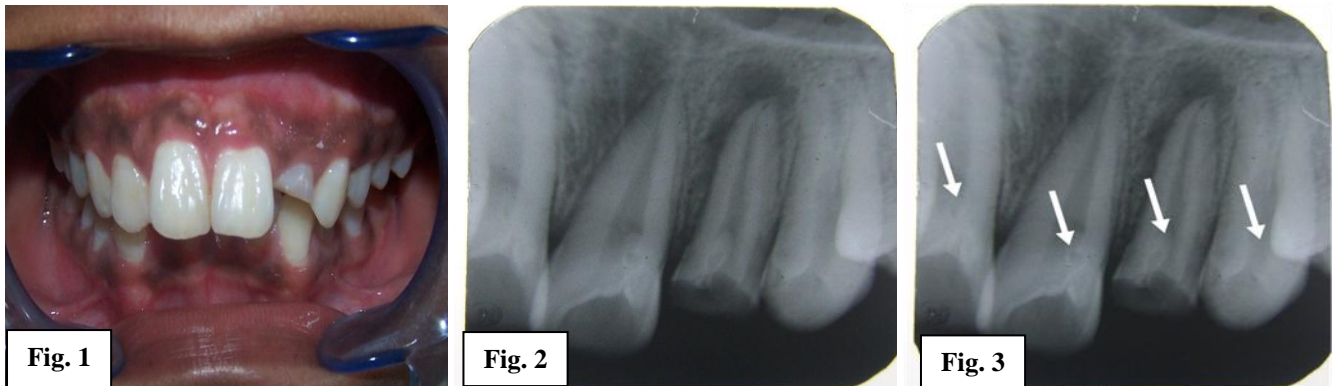Bilateral occurrence of the condition is frequently seen. Swanson and McCarthy (1947) were the first to present bilateral dens invaginatus malformation. Multiple dens invaginatus involving all four maxillary incisors has been reported by Conklin [5]. Only 1 case of dens in dente involving canine to canine has been reported in the literature by Burton et al [6]. We, hereby, report a case of multiple dens invaginatus involving maxillary anterior teeth (from canine to canine).

CASE REPORT

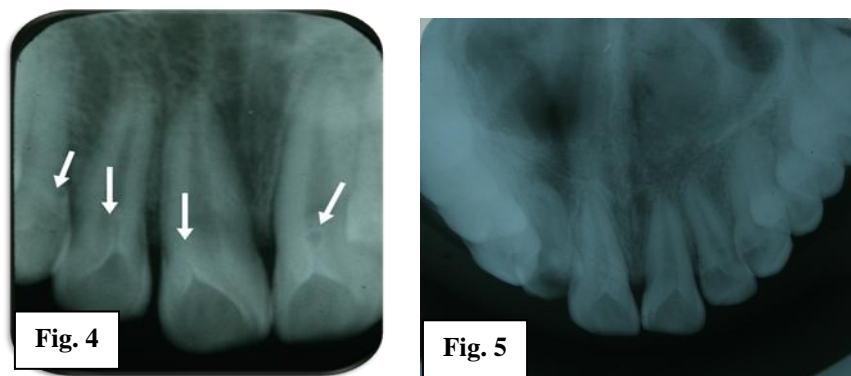
A 13 year old male patient presented to the Department of Pedodontics, K.V.G Dental College and Hospital, Sullia with the chief complaint of broken tooth in the upper left front tooth region. His past history and intraoral findings were non contributory except for findings like incompetency of lips and Class II division 1 malocclusion (**Fig 1**). IOPAR in relation to maxillary left lateral incisor showed hazy radiolucency of around 1 cm in diameter with ill defined irregular borders in the periapical region (**Fig 2**). There was also some radio opaque extensions

from coronal part of tooth into the pulp chambers of 21, 22, 23 (**Fig 3**) and 11, 12, 13 (**Fig 4**). A re-evaluation of the palatal aspect of maxillary anterior teeth showed no abnormal findings other than deep lingual pits of 12, 11 and 21. Occlusal radiograph showed that all the maxillary anterior teeth were having such radio opaque extensions into the pulp chamber in the coronal aspect (**Fig 5**). A full mouth radiographic survey was done which showed no pathologic changes in the rest of the dentition.

Radiographic diagnosis was chronic periapical abscess of maxillary left lateral incisor. The case is provisionally diagnosed as multiple dens in dente affecting the maxillary anterior teeth. The lesion was managed by abscess drainage and root canal treatment on 22. Since rests of the teeth were without any pulpal or periapical involvement, prophylactic restoration of deep pits of 12, 11 and 21 was done.



Figures: Fig 1 - Class II division 1 malocclusion. Fig 2 - IOPAR showing hazy radiolucency of around 1 cm in diameter with ill defined irregular borders in the periapical region of 22. Fig 3 - Showing radio opaque extensions from coronal part of tooth into the pulp chambers of 11, 21, 22, and 23.



Figures: Fig 4 - Showing radio opaque extensions from coronal part of tooth into the pulp chambers of 13, 12, 11, and 21. Figure 5 - Occlusal radiograph showing radio opaque extensions.

DISCUSSION

DI is a malformation of teeth probably resulting from an infolding of the dental papilla during tooth development. Affected tooth show a deep infolding of enamel and dentine starting from the foramen caecum or even the tip of the cusps and which may extend deep into the root [1]. It may also be associated with Taurodontism, Microdontia,

Gemination and Dentinogenesis imperfecta, short roots and with some medical–dental syndromes [7].

Various etiologies regarding the occurrence of DI have been suggested by different authors. According to Rushton (1937) the cause is embryological with the stimulation and subsequent proliferation and ingrowth of cells of the enamel organ into the dental papilla during development.

Kronfeld (1934) considered that the problem was due to the result of retardation of a focal group of cells, with those surrounding continuing to proliferate normally. Atkinson (1943) suggested that the problem was the result of external forces like forces from adjacent tooth germs during development. Other external factors considered as a cause for the occurrence of DI are trauma and infection [4]. The 'twin-theories' (Bruszt 1950) suggested a fusion of two tooth-germs [1]. According to Ohazama et al, during tooth development the ectomesenchymal signaling systems that occur between the dental papilla and the internal enamel epithelium affect tooth morphogenesis [8]. These signals have specific roles such as the regulation of growth and the folding of the enamel organ [9]. Dassule et al suggested that the absence of certain molecules can result in abnormally shaped teeth as well as defects in the developing tooth germ [10].

The first classification was published by Hallet in 1953. The most commonly used classification was proposed by Oehlers in 1957. Oehler S (1957) has classified this lesion into 3 types: **Type I:** - An enamel lined minor form occurring within the confines of the crown not extending beyond amelocemental junction. **Type II:** - An enamel lined form which invades the root, but remains confined as a blind sac, it may or may not communicate with the dental pulp. **Type III:** - a form which penetrates through the root perforating at the apical area showing a second foramen in the apical or in the periodontal area [1].

According to Pindborg, the prevalence of the condition affecting the maxillary lateral incisors ranged from 0.25 to 5.1 per cent [3]. It has been reported in the maxillary central, lateral incisors, canines and bicuspid, and the mandibular incisors and bicuspid [11]. It is mostly observed in the maxilla, compared to mandible and it occurs bilaterally in 43% of the cases [12]. The prevalence of DI occurring in all dentitions ranges from 0.25% to 7.74% [11]. Following maxillary lateral incisors in decreasing order of frequency are central incisors, premolars, canines and molars [3]. It can occur rarely in primary but frequently in permanent dentition. Males are more affected than females in a ratio of 3:1.14 [13].

High degree of inheritance has also been reported [13]. According to Bhaskar et al, two variations of DI can be found: Coronal and Radicular type. The coronal type is caused by an invagination of all layers of the enamel into

the dental papilla. The pulp is usually exposed and becomes necrotic or inflamed resulting in periapical lesions necessitating endodontic therapy. In radicular type, there is folding of Hertwig's sheath into the developing root, much like the coronal type, and pulpal necrosis and apical lesions are often associated [5]. A maxillary predominance is seen with this lesion [14].

In most of the cases, DI is detected incidentally on the radiograph [2]. The affected teeth radiographically show an infolding of enamel and dentine which may extend deep into the pulp cavity and into the root and sometimes even reach the root apex [1]. In present case also, the diagnosis was made on radiographic examination. Therefore, radiographic examination is a valuable tool for the diagnosis of DI in conjunction with clinical examination. The classic radiographic appearance of the coronal DI is a pear shaped invagination of the enamel and the dentine, with a narrow constriction at the opening on the surface of the tooth [15]. It should be done as per the ALARA principles (As Low As Reasonably Achievable) to minimize the radiation doses and releases of radioactive materials by employing all reasonable methods [7].

Clinically, a morphologic alteration of the crown or a deep foramen caecum can serve as an indication for the diagnosis of DI; however, affected tooth may not show clinical signs of the malformation [3,7]. The clinical aspects of the crown may vary, ranging from the normal to the most unusual and different shapes, such as a greater buccolingual diameter, peg-shaped, barrel-shaped and conical, and talon cusp. The presence of a deep blind foramen may be the first clinical sign indicating the existence of a DI [16]. The defect usually creates a thin barrier of enamel and dentin from the pulp [17]. This invagination allows entry of irritants into this area which predisposes for the development of dental caries which further progresses to pulp necrosis sometimes within a few years of eruption and even before root end closure. Other reported sequelae of undiagnosed and untreated coronal invaginations are abscess formation, retention of neighbouring teeth, displacement of teeth, cysts and internal resorption [1].

The treatment modalities include a) Conservative therapy - to prevent caries, pulp infection and premature loss of tooth, the condition must be recognised early and the tooth should be prophylactically restored with resins. It is indicated in Type 1 and some Type 2 forms and

contraindicated in Type 3. Endodontic therapy is indicated in Type 3 DI. Endodontic surgery is indicated in cases where endodontic therapy fails and is indicated for severe forms of DI, where periapical lesions are prominent. Intentional replantation is indicated in cases where combined endodontic-surgical treatment fails. It is performed to gain access to obtain an apical seal. Extraction is indicated when invaginated tooth causes an esthetic or functional disturbance [18]. The tooth most susceptible to coronal invagination at least in cases with deep pit should be investigated clinically and radiographically so as to instigate preventive treatment.

CONCLUSION

Dens invaginatus is clinically significant due to the possibility of pulpal involvement, as these invaginations can increase the bacterial growth and can affect the normal status of main canal. Dens in dente, though rare, is an anomaly that should be familiar to all practicing dentists. An early diagnosis is crucial and requires thorough clinical examination of all teeth especially lateral incisors.

REFERENCES

- Hulsmann M. Dens invaginatus: Aetiology, classification, prevalence, diagnosis and treatment considerations. *International Endodontic Journal*. 1997; 30: 79-90.
- Munir B, Tirmazi SM, Majeed HA, Khan AM, Iqbalbangash N. Dens invaginatus: Aetiology, classification, prevalence, diagnosis and treatment considerations. *Pakistan Oral & Dental Journal*. 2011; 31(1): 191-198.
- Mupparapu M, Singer SR. A rare presentation of dens invaginatus in a mandibular lateral incisor occurring concurrently with bilateral maxillary dens invaginatus: Case report and review of literature. *Australian Dental Journal*. 2004; 49(2); 90-93.
- Alani A, Bishop K. Dens invaginatus. Part 1: classification, prevalence and aetiology. *International Endodontic Journal*. 2008; 41; 1123-1136.
- Sisodia S, Maria R, Maria A. Dens invaginatus - A review and case Report. *Endodontology*. 75-82.
- Burton DJ, Saffos RO, Scheffer RB. Multiple bilateral dens in dente as a factor in the etiology of multiple periapical lesions. *Oral Surgery, Oral Medicine and Oral Pathology*. 1980; 49 (6): 496-499.
- More CB, Patel HJ. Dens Invaginatus: A Radiographic Analysis. *Open Access Scientific Reports*. 2012; 1: 147.
- Ohazama A, Courtney JM, Sharpe PT. Opg, Rank and Rankl in tooth development: co-ordination of odontogenesis and osteogenesis. *J Dent Res*. 2004; 83: 241-4.
- Kettunen P, Laurikkala J, Itaranta P, Vainio S, Itoh N, Thesleff I. Associations of FGF-3 and FGF-10 with signaling networks regulating tooth morphogenesis. *Developmental Dynamics*. 2000; 219: 322-32.
- Dassule HR, Lewis P, Bei M, Maas R, McMahan AP. Sonic hedgehog regulates growth and morphogenesis of the tooth. *Development*. 2000; 127: 4775-85.
- Jimenez-Rubio A, Segura JJ, Jimenez-Planas A, Llamas R. Multiple dens invaginatus affecting maxillary lateral incisors and a supernumerary tooth. *Endod Dent Traumatol*. 1997; 13: 196-198.
- Kannan SK, Bharadwaj TP, Urraj G. Dens in dente (dens invaginatus). Report of two unilateral and one bilateral case. *Indian J Dent Res*. 2003; 14: 125-129.
- Canger EM, Kayipmaz S, Celenk P. Bilateral dens invaginatus in the mandibular premolar region. *Indian J Dent Res*. 2009; 20(2): 238-40.
- Attur KM, Shylaja MD, Mohitta A, Abraham S, Kerudi V. Dens invaginatus, clinically as talons cusp: an uncommon presentation. *Indian J Stomatol*. 2011; 2: 200-03.
- Mishra S, Mishra L, Sahoo SR. A Type III Dens Invaginatus with Unusual Helical CT and Histologic Findings: A Case Report. *J Clin Diagn Res*. 2012; 6: 1606-1609.
- Neves FS, Bastos LC, Maria de Almeida S, Boscolo FN, Haiter-Neto F, Campos PSF. Dens Invaginatus: a cone beam computed tomography case report. *J Health Sci Inst*. 2010; 28: 249-50.
- Nandikeshwar P, Gaidhane P. Milind, Messd Khaled Al Salem. Non- Surgical Treatment of Dens Invaginatus: A Report of Two Cases. *Dental News*. 2006; 13(4): 42-48.
- Sousa SM, Bramante CM. Dens invaginatus: Treatment choices. *Endod Dent Traumatol*. 1998; 14: 152-158.

How to cite this article: Ayilliath A, Nandan S, Raj AC. Multiple Dens Invaginatus - A case report and review of literature. *Indian J Case Reports*. 2016; 2 (1): 14-17.

Conflict of interest: None stated, Funding: Nil