

Case Report

Giant Cell Tumor of Talus – Role of imaging

Bharat B Sharma¹, Sandeep Sharma², Priya Ramchandran², NK Maggu³, Sameer Kakar³, Vinay K Govila³

From Department of 1Radio diagnosis, and 3Orthopedics, SGT Medical College, Gurgaon, India and 2Anesthesia, Heartlands Hospital, Birmingham, UK.

Correspondence to: Dr Bharat Bhushan Sharma, C-35, First Floor, Anand Niketan, New Delhi – 110021, India. E mail: bbhushan986@gmail.com.

Received: 20 May 2016

Initial Review: 08 June 2016

Accepted: 14 June 2016

Published Online: 18 June 2016

ABSTRACT

Giant cell tumor (GCT) or Osteoclastoma of the tarsal bone is very rare as compared to that of long bones. The involvement of talus becomes unique in its presentation as it remains undiagnosed for a long time. The tumor usually occurs in younger age especially in small bones of hands and feet. We present a case of 34-years old male who presented with sprain of left foot and was finally diagnosed as giant cell tumor of the talus. This was possible with the help of various radiological modalities like plain X-ray, computerised tomography (CT) and magnetic resonance imaging (MRI). GCT of talus may be found as an incidental finding but the subsequent management depends upon the staging of the tumor as per the radiological evaluation.

Keywords: CT, Giant Cell Tumour, MRI, Tarsal bone

Giant cell tumor (GCT) is also known as Osteoclastoma occurs in younger age group and it is usually subarticular in location. This is benign tumor with local aggressiveness and comprises 5% of all the primary bone tumors. The importance of GCT management increases as there is tendency of these tumors for the recurrence [1]. The incidence of small bone GCT is 45% in younger age group as compared to 16% in combined cases. The understanding of these types of tumors becomes paramount because of their recurrence and metastasis. The purpose of this case is to highlight the clinico-radiological features of the small bone giant cell tumors and their subsequent impact on the management.

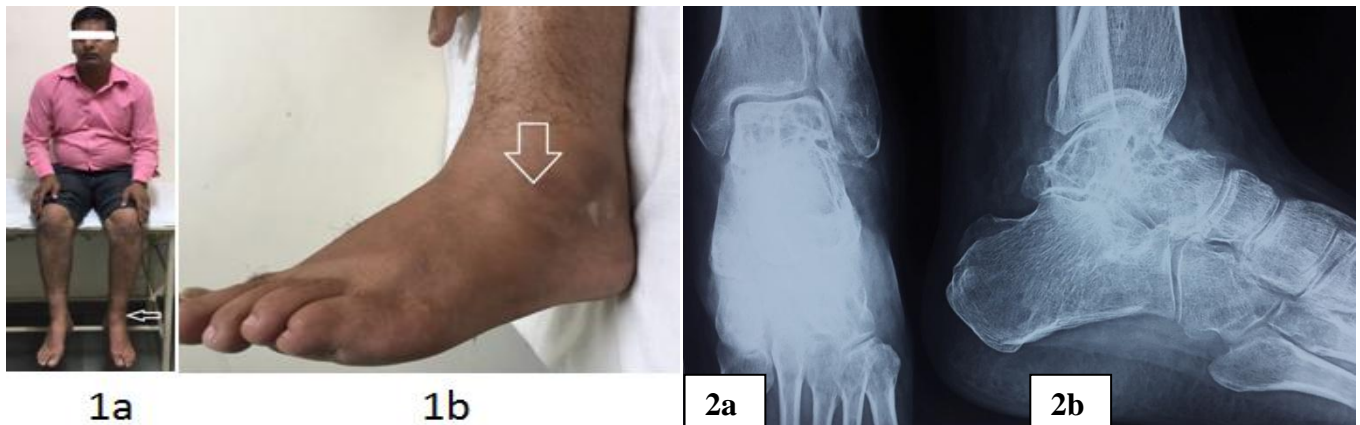
CASE REPORT

34-years old male presented with history of trivial trauma of left foot (**Fig. 1a and 1b**). This happened one year back and he was taking symptomatic treatment without much relief. He also had slight pain in this region earlier for about six months.

On examination, there was a swelling and slight asymmetry of the left ankle joint. The movements were restricted and painful. There was no mark of injury over the skin. There was no history of fever or other associated joint pains. There was no past history of tuberculosis, diabetes or hypertension.

All the biochemical parameters were normal. Plain X-ray ankle was advised. The skiagram revealed cystic lesions in the left talus tarsal bone without any obliteration of the joint space (**Fig. 2a and 2b**).

Plain CT was also done subsequently which revealed the expansile lytic lesion in the tarsal bone. The cortical thinning was extensive with a few broken regions. No evidence of new bone formation was noticed (**Fig. 3a, 3b & 3c**). Now the patient has undergone Contrast enhanced MRI and the total extent of lesion was delineated. There was enhancement of the lesion (**Fig. 4a, 4b, 4c and 5**). FNAC confirmed the diagnosis as Giant Cell Tumor. Patient has been planned for curettage and bone grafting.



Figures: Fig 1 - Photograph of 34-years old male (a) Comparison of two legs with slight asymmetry of left leg (horizontal arrow). (b) Left foot shows swelling at the left ankle joint region (vertical arrow). Fig 2 - Radiograph of left ankle joint (a) Anteroposterior view shows a few radiolucencies in talus with preservation of joint (b) Lateral view shows the affected talus in profile with multiple radiolucencies without obliteration of its outline.

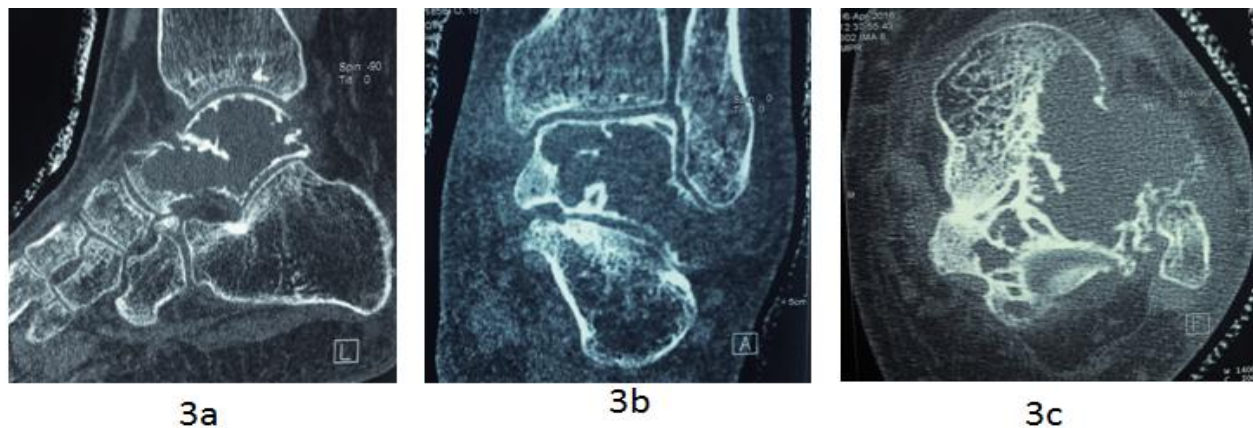


Figure 3 - NCCT Left foot with ankle joint (a) Lateral reformatted image shows an expansile lesion in talus with other tarsal bones being unaffected (b) Anteroposterior reconstructed image shows the extension of pathology on lateral and medial aspects (c) Coronal reconstructed image shows the same lesion with a few cortical breaks of talus tarsal bone.

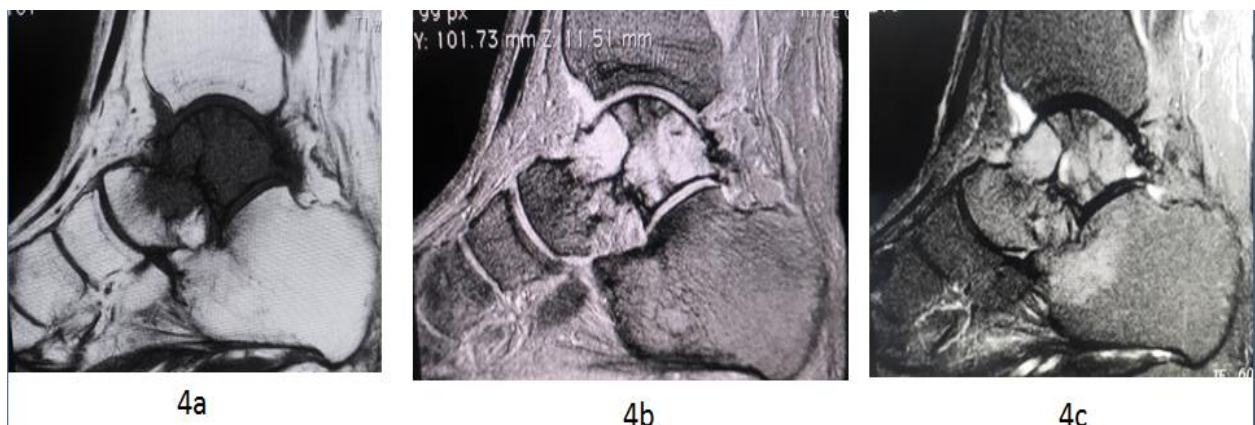

Figure 4 - Non contrast MRI ankle joint (a) T1W image shows a hypointense talus because of loss of marrow signals (b) T2W image shows hyperintense regions within the affected tarsal talus bone (c) STIR image shows suppression of marrow signals in the normal tarsal bones but hyperintensities within the affected talus bone.

DISCUSSION

GCT falls in the classification of primary bone tumor group. The common sites are the lower end of femur, upper end of tibia and lower end of radius. The smaller bone of the foot and hand are the rare sites but tends to occur multicentric [2]. The younger age group is affected more with smaller bone involvement [3]. Biscaglia et al has found the incidence as 45% among individuals below 20 years of age [4]. The peak incidence is at third decade [5]. Our patient is 34 years old when the skeleton has matured and the involvement of the tarsal bone at this age is slightly uncommon.

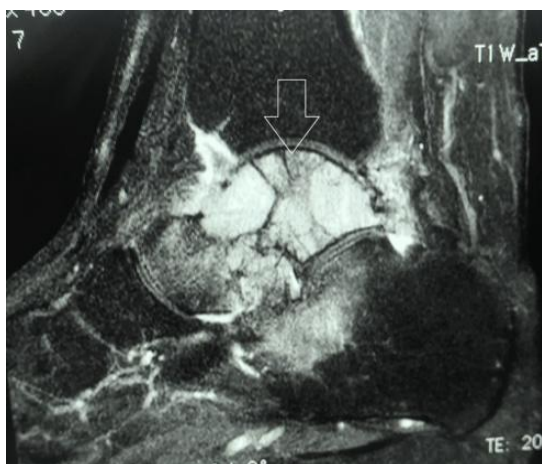


Figure 5 - Post gadolinium T1W fat saturated image shows intense enhancement of the affected talus and partly of the calcaneum on its anterior aspect (vertical white arrow)

Clinically the patient usually presents with ankle sprain but reporting without any trauma are also not uncommon. Our patient had history of ankle sprain for which he reported to the clinician. Malawer and Vance have reported the non aggressive nature of the tarsal bone GCT [6]. Pathologically it is constituted by friable vascular stroma of thin walled capillaries with necrosis, cyst formation and hemorrhage. The signs and symptoms are related to the multidirectional expansion of the tumor in marrow.

CT and MRI are the best modalities for the delineation of the tumour. CT has got advantage to describe about the bony contents and outline and MRI scores over the tissue characterization. The detailed contents of the tumor can best be described by T1W, T2W and contrast enhanced fat

suppressed T1W sequences. The tumor presents as lytic lesion within the small bone which extends beyond the confine of the cortex. Cortical thinning is without any periosteal reaction.

Campanacci grading has been advocated in CT and plain roentgenogram. Grade I presents with intact thinned out mature bone cortical margin. Grade II presents well defined margins without any cortical rim and Grade III presents with fuzzy margins. Grade I and II are treated with curettage and grade III is treated with excision [7].

As per the occurrence of GCTs, they are divided into three stages as follows – 1) Stage I: Radiologically and histological presence of GCT – 10-15%, 2) Stage II: Aggressive expansile radiological picture with remodeling – 70-80%, and 3) Stage III: Histological benign appearance with extension to the adjoining soft tissues.

If fracture is also present then the new bone formation can be seen. Joint surface are well preserved for quite late sometimes. There is approximately 3% GCTs which show lung metastasis and the incidence is mostly found in recurrence cases. Fine Needle Aspiration (FNAC) can confirm the diagnosis [8]. p63 expression in immunostaining with mononuclear cells differentiates the tumor from aneurysmal bone cyst and chondroblastoma [9].

Primary management is by bone grafting and curettage. Fresh-frozen osteochondral allograft reconstruction has been a great success in the management of talus GCT [10]. The recurrence rate is still quite high. It was found as 72% who are treated with isolated curettage, 13% in those treated along with adjuvant, 15% with resection and 10% with amputation [11].

CONCLUSION

Small bone expansile lesions are the real diagnostic dilemma and poses real challenge for both the radiologists and the treating orthopedic surgeons. One can come closer to the diagnosis with the present diagnostic armamentarium like CT and MRI. MRI has got variety of sequences by which the confidence in probable diagnosis increases as happened in our case which was subsequently confirmed by FNAC. MRI with contrast is the most useful tool for these types of cases and the delay in diagnosis can be avoided with their judicious use.

REFERENCES

1. Bapat MR, Narlawar RS, Pimple MK, Bhosale PB. Giant cell tumour of talar body. J Postgrad Med. 2000;46:110.
2. Wold LE, Swee RG. Giant cell tumor of the small bones of the hand and feet. Semin Diagn Pathol. 1984;1:173-184.
3. Chatha DS, Raybak L, Witting J, et al. Clin Orthop Relat Res. 2007;(465):271-276.
4. Biscaglia R, Bacchini P, Bertoni F. Giant cell tumor of the bones of the hand and foot. Cancer. 2000;88:2022-32.
5. Harness NG, Mankin HJ. Giant-cell tumor of the distal forearm. J Hand Surg. 2003;29A:188e93.
6. Malawer MM, Vance R. Giant cell tumor and aneurysmal bone cyst of the talus: clinicopathological review and two case reports. Foot Ankle. 1981;1:235-4.
7. Campanacci M, Gluntini A, Olim R. Giant cell tumour of bone: A study of 209 cases with long term follow-up in 130 cases. Ital J Orthop Traumatol. 1975;1:249-277.
8. Lawson L, Van Lerberg N, Tawfik O. Pulmonary metastasis from a benign giant-cell tumor of the hand: report of a case diagnosed by fine needle aspiration cytology. Diagn Cytopathol. 1996,15:157-160.
9. Dickson BC, Li SQ, Wunder JS, et al. Giant cell tumor of bone expression p63. Mod Pathol. 2008;21(4):369-375.
10. Schoefeld AJ, Leeson MC, Grossman JP. Fresh-frozen osteochondral allograft reconstruction of a giant cell tumor of the talus. J Foot Ankle Surg. 2007;46(3):144-8.
11. Oliveria VC, van der Heijden L, van der Geest IC, Campanacci DA, Gibbons CL, van der Sande MA, et al. Giant cell tumours of the small bones of Bone Joints J. 2013;95-B(6):838-845.

How to cite this article: Sharma BB, Sharma S, Ramachandran P, Maggu NK, Kakar S, Govila VK. Giant Cell Tumour of Talus – Role of Imaging. Indian J Case Reports. 2016; 2(3) 79-82.

Conflict of interest: None stated, Funding: Nil