

Case Report

Electromyographic analysis of the masseter and temporalis muscles and bite force in a patient treated by functional maxillary orthopedics: a case report

Sandra Valéria Rancan, Marcelo Palinkas, César Bataglion, Paulo Batista de Vasconcelos, Selma Siéssere, Flávia Luiza Rancan, Laura Moura Martins, Simone Cecilio Hallak Regalo, Marisa Semprini

From, Department of Morphology, Physiology and Basic Pathology, Ribeirão Preto Dental School, University of São Paulo, Ribeirão Preto, Brazil

Correspondence to: Prof. Marcelo Palinkas. Faculdade de Odontologia de Ribeirão Preto, Universidade de São Paulo. Avenida do Café, s/n, 14040-904, Ribeirão Preto, São Paulo, Brazil. palinkas@usp.br.

Received: 01 July 2016 Initial Review: 06 August 2016 Accepted: 12 September 2016 Published Online: 20 September 2016

ABSTRACT

This case report evaluated electromyographic activity of the masseter and temporalis muscles and molar bite force, before and after with functional orthopedic. A 65 years woman presenting with orofacial pain symptoms, cervical tension, condyle subluxation and osteoarthritis. The patient was diagnosed with temporomandibular dysfunction and treated with use of a Simões Network 9 modified type functional maxillary orthopedics appliance. The Myosystem BR1 apparatus was used to analyze the electromyographic activity of the masseter and temporalis muscles. The maximum molar bite force was measured with the digital dynamometer (KratuS). This study showed increased EMG activity of the masseter and temporalis muscles in postural conditions of mandible and molar bite force after 12 months of treatment. After twelve months of treatment, the patient had lack of pain symptoms as well as an improvement in the balance of the mastication muscles, as demonstrated by EMG activity and maximum molar bite force.

Keywords: Electromyography, Functional Maxillary Orthopedics, Molar Bite Force, Stomatognathic System

Temporomandibular joint disorder (TMD) is defined as a group of disorders that affect the mastication muscles, temporomandibular joint (TMJ), and related structures [1]. The symptoms in these patients with TMD include pain in the TMJ, face, and mastication muscles, headache, auricular symptoms such as airplane ear, auricular noise, and vertigo [2]. TMD treatment is directly related to modern dentistry and embraces methods that promote relaxation of the mastication muscles, such as those used in functional maxillary orthopedics. This specialty aims to act on the neuromuscular system that controls normal maxillary development to prevent

malformations and functional disorders [3]. It treats poor occlusions and their physical and functional consequences using therapeutic resources that utilize functional stimuli, aiming to achieve morpho-functional balance of the stomatognathic system [4].

This neuro-occlusal rehabilitation treatment corrects poor occlusion and remodels the bone structure, providing muscle harmony and improving the signs and symptoms of TMJ dysfunction [5]. McNamara et al [6] reported that functional orthopedics reduces the signs and symptoms of TMD, improves symptoms of obstructive sleep apnea and

prevents the development of skeletal facial asymmetry, which can produce functional disorders in the stomatognathic system. According to the literature, there are other treatment modalities available to treat TMD are acupuncture [7], occlusal splint [8], botulinum toxin [9] and laser therapy [10].

The objective of this clinical case report was to demonstrate the importance of functional maxillary orthopedics as a method of rehabilitation to improve the life quality of individuals with bone unconformity, orofacial pain, and TMD, by illustrating potential functional changes in the mastication muscles through surface and maximal molar bite force electromyographic activity analyses.

CASE REPORT

This case report was approved by the research ethics committee (number process 2008.1.259.58.9), according to resolution 466/2012 of the Brazilian Health Council.

A 65 years woman patient (weight: 63.0 kg; height: 1.58 cm; body mass index: 25.24 kg/m²) who had all of her teeth and demonstrated distal occlusion presented with headaches, cervical pain, a lack of confidence regarding mouth opening, and clicking sounds in both ears. During patient anamnesis, Research Diagnostic Criteria for Temporomandibular Disorders (RDC/TMD) survey was applied, clinical examination of the oral cavity was performed, and muscular palpation was carried out on the face, neck, and TMJs. The diagnosis of TMD was made by clinical examination and RDC/TMD where the clinical aspects (Axis I) and psychosocial factors (Axis II) were approached.

Auxiliary exams including panoramic radiography, teleradiology profile, and TMJ planigraphy were performed; in addition, complementary exams such as polysomnography to diagnosis sleep bruxism. Through the results of these exams, it was possible ratify the diagnosis centric sleep bruxism, right and left mandibular condyle subluxation, flattening of the anterior and superior aspects of the mandibular condyles. Use of cephalometric analysis indicated the use of functional orthopedics apparatus and associated with pharmacotherapy. The patient was informed about the treatment plan, and signed an agreement form accepting the proposed research exams and treatments.

The first stage of this case report involved EMG activity analyses of the masseter and temporalis muscles (right and left) as well as the maximum molar bite force, before the proposed treatment. For EMG data collection was used Myosystem BR1 apparatus (Data Hominis Tec. Ltd, Uberlândia, MG, Brazil) (**Fig. 1**). Electromyography was conducted using surface active differential electrodes (two 10 mm-long x 2 mm-wide silver chloride bars 10 mm apart) with input impedance of 10¹⁰ Oectpf, bias current input of rrenA, common-mode rejection ratio of 110 dB at 60 Hz and gain equal to 20x. For signal conditioning and data acquisition, a portable, high performance twelve channel data acquisition system was used. The EMG signals were further amplified by 50x (total gain 1000x), bandpass filtered (20 Hzd (20 Hz ratio of 11 at a frequency of 2 kHz with 16 bits resolution. The following conditions were evaluated: rest (4s), dental clenching in maximal voluntary contraction (4s), right (10s) and left (10s) right laterality (10s), left laterality (10s) and protrusion (10s).




Figure 1 - Myosystem-BR1



Figure 2 - Digital dynamometer, model IDDK

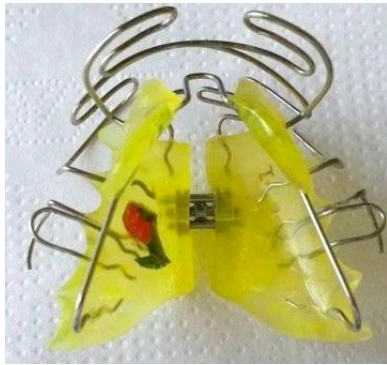

Figure 3 - SN 9 modified type functional orthopedics appliance

Maximum molar bite force was measured using a digital dynamometer (IDDK; Kratos, Cotia, SP, Brazil) with a capacity of 1000 N (Figure 2). Measurements were taken first on the right and then on the left side, where the strongest bite was developed. During measurement, the patient was sitting on a chair with her arms extended beside her body and her hands resting on her thighs. She was instructed and trained in how to bite the equipment, ensuring procedure reliability. The dynamometer was cleaned using alcohol and protected with a disposable latex cover (Wariper, Sao Paulo, SP, Brazil), which was used as a biosafety measure. Three measurements were taken for each side, alternating between the sides with a 2-minute break between each bite. The maximum bite force was recorded as the highest value for each side.

The second stage was the treatment itself. A modified appliance (Simões Network 9-SN9) [4] type functional maxillary orthopedics with free dorsal arches and built in pro-rotation was set up and fitted in the patient (Figure 3). The SN9 permits lateral-protrusive movements and dissipates tensions in the curve of the dorsal arch responsible for fractures. Throughout the treatment, monthly check-ups were carried out, which consisted of periodic evaluation of apparatus fitness within the oral cavity and performance of any necessary adjustments. After 6 to 12 months of treatment, patient anamnesis was repeated using questionnaires and clinical evaluation. In addition, electromyographic examination and measurement of molar bite force were performed again.

DISCUSSION

Many methods can be used to evaluate functional changes of the stomatognathic system in patients with TMD and

orofacial pain, including electromyographic examination and measurement of molar bite force [11].

Table 1 - Electromyographic means (microvolt/second), of the right and left masseters (RM and LM) and anterior temporalis (RT and LT) muscles, in the following clinical conditions, before and after (12 months) use of functional maxillary orthopedic

Clinical Conditions	Muscles	Treatment Time		
		Before	6 mo	12 mo
Rest	RM	4.26	20.97	4.82
	LM	4.05	5.86	4.16
	RT	6.94	4.98	5.22
	LT	6.56	13.55	5.39
Right laterality	RM	5.22	22.26	6.73
	LM	11.01	10.57	11.44
	RT	14.77	11.01	13.19
	LT	13.17	16.97	13.00
Left laterality	RM	4.56	14.74	6.78
	LM	12.12	10.08	7.39
	RT	5.24	4.95	6.62
	LT	10.28	16.85	10.22
Protrusion	RM	21.15	17.51	19.76
	LM	48.1	41.00	25.56
	RT	5.08	5.27	6.94
	LT	5.33	13.74	7.84
Maximal Voluntary Contraction	RM	20.78	23.05	96.83
	LM	59.85	46.65	131.61
	RT	30.23	21.89	38.23
	LT	37.89	41.17	71.86

These internationally accepted methodologies have as their main objective a rational and criteria-based diagnosis, and can be used to complement anatomic-physiological

study [12]. These methods were used in the current clinical case to analyze the masseter and temporalis muscles of a patient with TMD, who was treated with a protocol using functional maxillary orthopedics [13].

Table 2 - Mean of maximal bite force (N) before and after (6 and 12 months) use the functional maxillary orthopedic

Region	Treatment Time		
	Before	6 months	12 months
Right molar region	228.89	274.59	314.99
Left molar region	291.85	225.55	304.01

The EMG examinations performed revealed important information about the functional reestablishment of the masseter and temporalis muscles, proving the effectiveness of the treatment used (Table 1). The results collected when the mandible was at rest showed a decrease of electromyographic activity in the masseter and temporalis muscles (right and left) after treatment (12 months) in comparison to the activity measured in the initial phase of treatment. This decrease was probably related to remission of pain symptoms caused by dental compression during sleep, subluxation of the mandibular condyles, headaches, cervical pain and osteoarthritis [14], and was likely due to posture changes during use of the apparatus leading to clinical improvement. Bone discrepancy remodeling and articular positioning after 12 months of functional orthopedics appliance use reestablished the functionality of the masticatory muscles [15].

During evaluation of right and left laterality, the neuro-anatomical muscular activation pattern observed remained the same after 12 months of treatment, with higher electromyographic activity of the temporalis muscle through the ipsilateral side of the mandible and higher contralateral activity of the masseter muscle, as expected [12]. During protrusion, the muscular pattern necessary to maintain this position showed higher activation of the masseter muscles in comparison with the temporalis muscles. Therefore, the present clinical case displayed the same pattern as that described by the kinesiology literature [16]. On the other hand, dental clenching in maximal voluntary contraction caused increased activity in all of the analyzed muscles (right masseter of 20.78 to 96.83, left masseter of 59.85 to 131.61 9.85, right temporalis of 30.23 to 38.23 and left temporalis of 37.89 to 71.86 μ V/s). This result suggests the adaptation of muscular function

resulting from a well-planned and appropriate treatment [17].

In the current case, the physiological masticatory muscle balance achieved after 12 months of functional orthopedics treatment using an SN 9 modified appliance may have been related to psychological impact on the patient [18]. Patients undergoing functional orthopedics treatment may become more confident in the execution of mandible movement, thus recruiting a lower number of muscular fibers to perform the same masticatory function as compared to before treatment [19]. In the present clinical case, however, patient psychological changes and their correlation with variations in electromyographic activity were not evaluated.

Functional maxillary orthopedics treatments cause a significant decrease in bite force [20]. The results of the current study reinforce findings in the literature showing that treatment with functional orthopedics apparatus in subjects with accurately diagnosed TMD leads to successful pain relief. However, the findings did not reinforce other reports in the literature since the results showed an increase of maximal molar bite force after functional jaw orthopedics (Table 2) and an improvement of occlusal strength after 12 months of treatment.

CONCLUSION

The results of this case report showed a positive change in the stomatognathic system of a TMD patient after functional orthopedics treatment. This demonstrates the effectiveness of neuromuscular mechanics in changing skeletal posture in the cervical area, establishing the TMJ and promoting muscular remodeling, relieving symptoms related to TMD, and reestablishing the functional balance of the masseter and temporalis muscles. These improvements were due to correct mandible movement and an increase in maximal molar bite force.

REFERENCES

1. Matuska AM, Muller S, Dolwick MF, McFetridge PS. Biomechanical and biochemical outcomes of porcine temporomandibular joint disc deformation. *Arch Oral Biol.* 2016; 64:72-9.
2. Shaffer SM, Brismer JM, Sizer PS, Courtney CA. Temporomandibular disorders. Part 2: conservative management. *J Man Manip Ther.* 2014; 22:13-23.

3. Martins LM. Jaw functional orthopedics: dysfunction prevention. Ribeirs LM. Jaw functional orthopedTota Bookstore and Publisher. 2011, ISBN 978-8560246-11-3.
4. Leite RA, Rodrigues JF, Sakima MT, Sakima T. Relationship between temporomandibular disorders and orthodontic treatment: a literature review. Dental Press J Orthod. 2013; 18:150-157.
5. Stuhr SH, Earnshaw DH, Duncombe AM. Use of orthopedic manual physical therapy to manage chronic orofacial pain and tension-type headache in an adolescent. J Man Manip Ther. 2014; 22:51-58.
6. McNamara JA Jr, Lione R, Franchi L, Angelieri F, Cevidanes LH, Darendeliler MA, et al. The role of rapid maxillary expansion in the promotion of oral and general health. Prog Orthod. 2015; 16:33.
7. Rancan SV, Bataglioni C, Bataglioni SA, Bechara OM, Semprini M, Siéssere S, et al. Acupuncture and temporomandibular disorders: a 3-month follow-up EMG study. J Altern Complement Med. 2009; 15:1307-1310.
8. Candirli C, Korkmaz YT, Celikoglu M, Altintas SH, Coskun U, Memis S. Dentists' knowledge of occlusal splint therapy for bruxism and temporomandibular joint disorders. Niger J Clin Pract. 2016; 19:496-501.
9. Kim HS, Yun PY, Kim YK. A clinical evaluation of botulinum toxin-A injections in the temporomandibular disorder treatment. Maxillofac Plast Reconstr Surg. 2016; 28: 38:35.
10. Sayed N, Murugavel C, Gnanam A. Management of Temporomandibular Disorders with Low Level Laser Therapy. J Maxillofac Oral Surg. 2014; 13:444-450.
11. Berni KC, Dibai-Filho AV, Pires PF, Rodrigues-Bigaton D. Accuracy of the surface electromyography RMS processing for the diagnosis of myogenous temporomandibular disorder. J Electromyogr Kinesiol. 2015; 25:596-602.
12. Cec2-ation of molar and incisor bitIssa JP, Si, Siof molar and inciet al. Ageing and surface EMG activity patterns of masticatory muscles. J Oral Rehabil. 2010; 37:248-255.
13. Martins LM. Electromyographic evaluation of temporal, masseter and orbicularis muscles, Angleazil. Arch Oral Biol. 2008; 53ectromyogr Kinesiol. 2015; 25015; 25; 222014; 224; 224; 22stem was used. The EMG signals were stry SLMandic, 2007.
14. Takeshita N, Ishida M, Watanabe H, Hashimoto T, Daimaruya T, Hasegawa M, et al. Improvement of asymmetric stomatognathic functions, unilateral crossbite, and facial esthetics in a patient with skeletal Class III malocclusion and mandibular asymmetry, treated with orthognathic surgery. Am J Orthod Dentofacial Orthop. 2013; 144:441-454.
15. Sood S, Kharbanda OP, Duggal R, Sood M, Gulati S. Neuromuscular adaptations with flexible fixed functional appliance--a 2-year follow-up study. J Orofac Orthop. 2011; 72:434-445.
16. Dib A, Montero J, Sanchez JM, Lib A, Montero A. Electromyographic and patient-reported outcomes of a computer-guided occlusal adjustment performed on patients suffering from chronic myofascial pain. Med Oral Patol Oral Cir Bucal. 2015; 20:e135-143.
17. Hashimoto T, Kuroda S, Kamioka H, Mishima K, Sugahara T, Takano-Yamamoto T. Bimaxillary protrusion with masseter muscle hypertrophy treated with titanium screw anchorage and masseter surgical reduction. Am J Orthod Dentofacial Orthop. 2009; 135:536-548.
18. Serg HG, Zentner A. Study of psychosocial aspects of adult orthodontic treatment. Int J Adult Orthodon Orthognath Surg, 1997; 12:17-22.
19. De Rossi M, Santos CM, Miglioran12 1997; 12 12hodAll on Four Santos CM, Miglioran12 1997; 12 12hodontic treatment. screw anchoragClin Implant Dent Relat Res. 2014; 16:594-600.
20. Al-Khateeb SN, Abu Alhaija ES, Majzoub S. Occlusal bite force change after orthodontic treatment with Andresen functional appliance. Eur J Orthod. 2015; 37:142-146.

How to cite this article: Rancan SV, Palinkas M, Bataglioni C, Vasconcelos PB, Siéssere S, Rancan FL, Martins LM, Regalo SCH, Semprini M. Electromyographic analysis of the masseter and temporalis muscles and bite force in a patient treated by functional maxillary orthopedics: a case report. Indian J Case Reports. 2016;2(4): 93-97.

Conflict of interest: None stated, Funding: Nil