

## Spectrum of fireworks related ocular injuries on the day of Deepavali

Sikander A K Lodhi, S. Saudhamini, Thandra Sai Shreya, Nalinikanth Mukkavalli

*From the Department of Ophthalmology, Osmania Medical College / Sarojini Devi Eye Hospital, Hyderabad, Telangana India*

**Correspondence to:** Dr Sikander AK Lodhi, 'Hill View', 10-3-300/3, Humayun Nagar, Masab Tank, Hyderabad - 500028, Telangana, India. Email: [sikanderlodhi@gmail.com](mailto:sikanderlodhi@gmail.com)

Received: 01 Dec 2016

Initial Review: 21 Dec 2016

Accepted: 30 Dec 2016

Published Online: 09 Jan 2017

### ABSTRACT

Fireworks are often associated with severe ocular injury. In India, fireworks are an important cause of ocular injury during Deepavali festival. We present the spectrum of fire-cracker related ocular injuries on the day of Deepavali and their associated risk factors. All patients with cracker related ocular injuries on Deepavali day, seen at a tertiary care eye hospital, are included in this case series. This case series evaluates the type of ocular injury, type of firecracker involved and the associated risk factors leading to the casualties

**Keywords:** Fireworks, ocular injury, corneal abrasions, hyphema

Deepavali is an important Indian festival that is celebrated on a mass scale, not only in India but also in other countries wherever Indians are settled. Traditionally firecrackers are an essential part of Deepavali celebrations, "The Festival of Lights". Fireworks are also part of The Hari Raya Festival in Malaysia, Independence Day in the United States and the Chaharshanbe Soori in Iran.

We do not have population-based studies to show the real magnitude of fire-cracker related eye injuries in India, but hospital-based studies show that it causes significant ocular morbidity in our country [1, 2]. We report a series of cases of cracker-related ocular injuries seen on the day of Deepavali, to highlight the importance of fireworks being an important cause of ocular injury in India and to study their associated risk factors.

### MATERIAL AND METHODS

All the patients with cracker-related eye injuries attending the Emergency department of a tertiary care government

eye hospital on the day of Deepavali, from noon to 6 AM next morning, were included in this case series. All the patients were attended immediately. A comprehensive eye examination was done and the necessary treatment was given immediately. The injuries were classified according to Birmingham eye trauma terminology system (BETTS) [3].

Patients with minor injuries were given treatment and sent home and those with ocular injuries of more serious magnitude were admitted either for observation or for any surgical treatment. Superficial skin burns, abrasions, foreign bodies on the cornea and corneal epithelial abrasions were given outpatient treatment. Those with closed globe injuries, causing hyphema, iridodialysis, lens subluxation and vitreous hemorrhage; and open globe injuries were admitted for further management.

### RESULTS

Twenty-three patients (with the involvement of 28 eyes) were seen on the day of Deepavali, twenty were males and

three were female patients. The age range was four to fifty years, seventeen of whom were less than 25 years. Different types of crackers - flower pots, rockets,

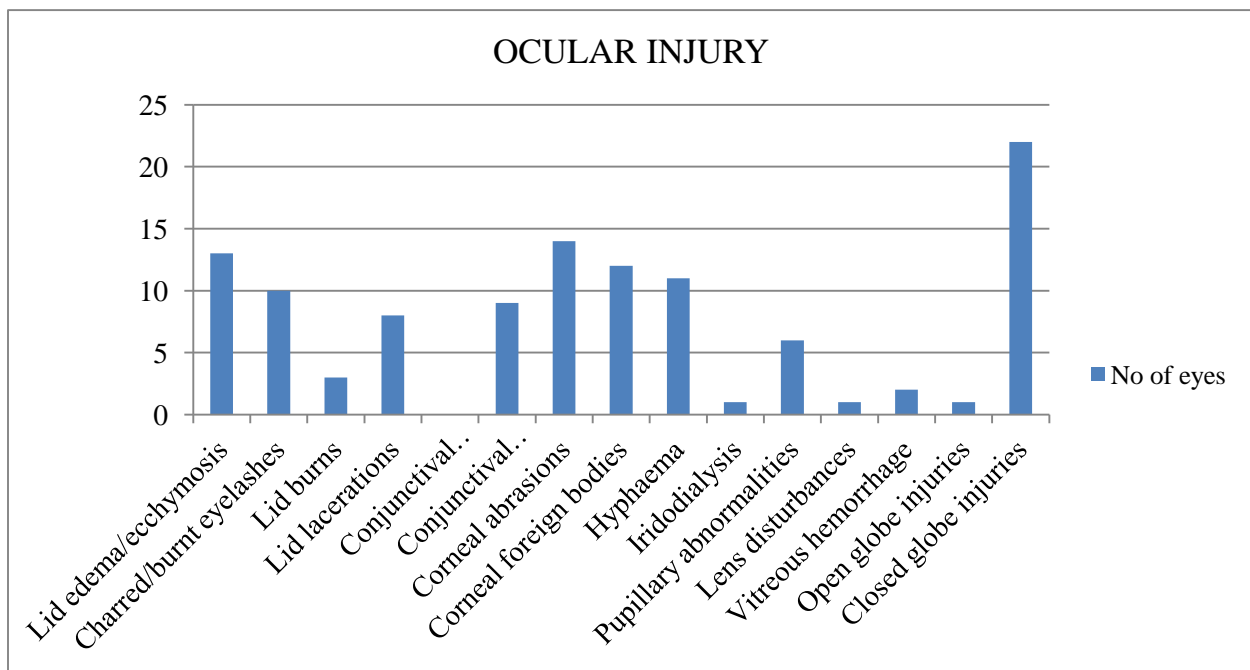
sparklers, bombs, to name a few were involved in causing the ocular injuries. The most common type of cracker causing injury was a bomb.

**Table 1 - Cases admitted for inpatient management**

Cases	Initial VA	Visual outcome
1. Blunt trauma with total hyphema and vitreous hemorrhage	PL+	CF ½ meter Hyphema cleared with persisting VH
2. Blunt trauma with hyphema	CF 2 meter	6/9 Hyphema cleared and normal fundus
3. Hyphema, dislocated cataractous lens, VH +RD	PL ±	PL ± PPL+PPV+EL +SOI
4. Open globe laceration	PL-	PL- Wound repair
5. Hyphema	6/60p	6/9 Hyphema cleared with medical management

The number of cases that were actively involved in burning crackers and getting injured was 10 and the remaining 13 were comprised of onlookers, passersby or accidentally getting injured due to a flying cracker from a distance. None of the cracker injury patients gave a history of using any protective eyewear. The right eye was involved in 12 cases and both eyes in 6 cases. Strangely, all these 12 cases of RE involvement belong to those cases who were actively involved in burning the crackers.

On initial assessment, nine patients had a vision of 6/60 or less, with three patients having a vision of only light perception (PL). All three patients with PL only vision were less than five years of age. The distribution of cases with a vision of 6/60 or less was equal between those who were actively involved and those who were passersby/onlookers. Three patients less than 5 years of age did not cooperate for vision recording.

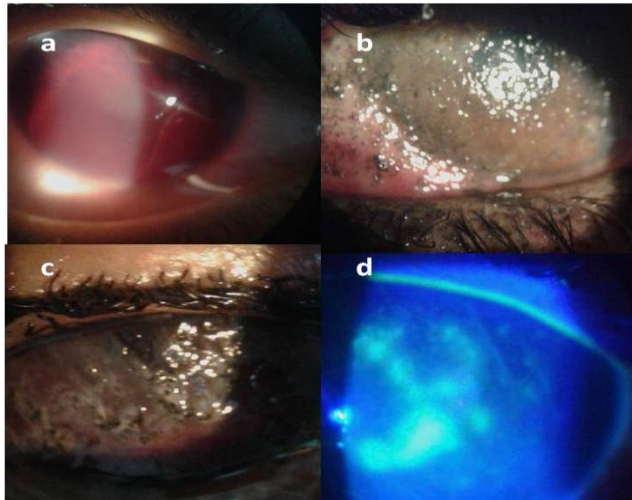


**Figure 1 - The spectrum of cracker related ocular injuries**

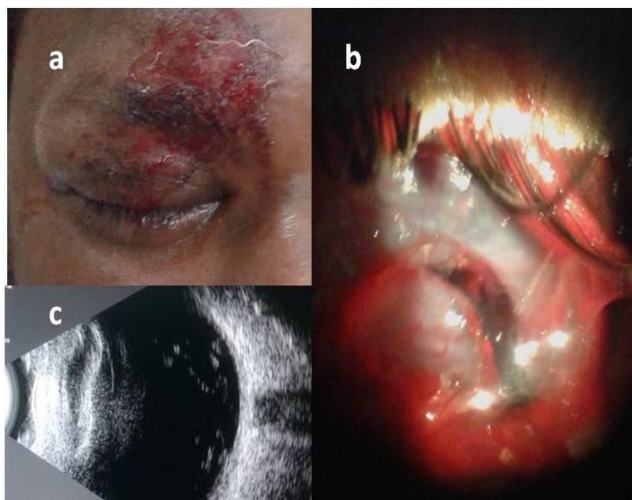
According to BETTS, 22 eyes had closed globe injuries and only one eye had open globe injury (Fig. 1, 2, & 3). Among the closed globe injuries, the common features were skin burns, corneal epithelial defects and corneal foreign bodies (soot particles). The most common

serious manifestation was hyphema, seen in 11 eyes. All cases with eyelid skin burn; conjunctival and corneal foreign bodies were treated on an outpatient basis. The cases were treated as per the standard protocol for the management of ocular burns and chemical injuries. All

external injuries were treated with a thorough wash with an irrigating saline solution. Soot particles and foreign bodies were removed under local anesthesia. Patients were prescribed antibiotic drops, lubricating solutions, and cycloplegic drops. All the cases with visual acuity 6/60 or less were admitted for further evaluation and management.



**Figure 2** a) shows hyphaema. b) Soot particles on external surface with limbal ischemia. c) Charred eyelashes and multiple foreign bodies on the cornea. d) Fluorescein staining showing extensive epithelial defects on the cornea.



**Figure 3** a) Edematous lids with superficial skin burns and abrasions. b) corneoscleral laceration. c) Ultrasound showing vitreous hemorrhage in a case with total hyphema.

Of the five admitted patients (Table 1), two patients with hyphema had a good visual outcome of 6/9 after total

clearing of blood from the anterior chamber on medical management. One other patient had total clearing of hyphaema but with persisting vitreous hemorrhage; had a vision of ½ meter. Two patients required surgical intervention. One patient with blunt trauma, subluxated lens, vitreous hemorrhage and RD had a pars plana lensectomy and vitrectomy with silicone oil injection had a poor outcome due to decompensated cornea. He had just a perception of light. The patient with open globe injury, with a corneoscleral laceration, had primary wound repair. The eyeball was soft and ultrasound showed multiple hemorrhagic choroidal detachments. Perception of light was doubtful.

## DISCUSSION

Cracker related body injuries in general and ocular injuries, in particular, are common during festivals and national celebrations like Deepavali in India, the spring festival in China, Independence Day in the United States and the Chaharshanbe Soori in Iran. Considering their explosive nature, the use of firecrackers causes serious injury and cost to the family and society. This injury and cost to the society are quite substantial considering the disproportionately higher involvement of younger individuals, as can be seen in the present study.

This is a hospital based single center prospective case series of firecracker-related ocular injuries seen on the day of Deepavali this year. The majority of patients were below the age of 25 years, and a majority of them were males. The number of onlookers or those getting accidentally injured was more than the cases who were actively involved in lighting crackers. This is different from a systematic review by Wisse RP et al, where the victims among bystanders were less than 50% [4]. There were instances where individuals walking on the road, sitting in their shop or house were hit by a flying cracker. The most common type of cracker causing ocular injury in this study was a bomb, small or big. This was similar to a study by Kumar R, et al from South India [1]. Right eye involvement was the common factor among all those who were actively involved. The reasons could be the dominant nature of right eye and the victim approaching closer to the firecracker to check the status of ignition.

The most common injuries were hyphaemas, corneal abrasions, corneal foreign bodies and lid injuries. Chang et al report similar manifestations in their study from “The

11-Year Experience of a US Level I Trauma Center” [5]. Wisse et al, in their systematic review, report Corneal/adnexal burn, Contusion and Corneal abrasion as the most common ocular injuries from crackers [4]. The poor visual outcome in three eyes out of the total of 28 eyes (11%) affected in our study was due to corneoscleral laceration and posterior segment damage.

One important observation in this study is the high number of onlookers and passersby who are affected. They comprise 56.5%, compared to 43.5% of those who were actively involved in lighting the crackers. This is similar to other studies where in addition to users, a significant number of passersby and onlookers sustained ocular injuries due to fireworks. This is in contrast to a professional firework display, where ocular injuries are relatively rare. In the study by Chang et al [5], only one patient had sustained an ocular injury during a public firework display and that patient was the one who was handling the fireworks. Countries using restrictive firework legislation have a lower incidence of firework related ocular injuries [4]. Another important observation is the lack of usage of any protective eyewear in all those who were actively involved in lighting the crackers.

We make few recommendations to curtail the incidence of cracker related ocular injuries. The authorities should not allow the use of firecrackers at public places, thoroughfares, communities, settlements, and rooftops. Public fireworks can be arranged in open places during festival times. There should be a recommendation for safety and preventive measures like maintaining a safe distance and use of protective eyewear on warning labels for fireworks. Concurrent sale of protective eyewear with the sale of crackers should be made compulsory. The role of ophthalmologists in the media campaign and use of social networking highlighting the risks of cracker related ocular injuries and triage in the management is important.

## CONCLUSION

Injuries to the eye from fireworks are quite common and visually devastating. Though the majority of the cases in this case series did improve on immediate management, but a sizeable number resulted in a significant visual loss. Public education and preventive measures should reduce the incidence of fireworks-related ocular injuries in future.

## REFERENCES

1. Kumar R, Puttanna M, Sriprakash K S, Sujatha Rathod B L, Prabhakaran VC. Firecracker eye injuries during Deepavali festival: A case series. *Indian J Ophthalmol.* 2010; 58: 157-9
2. Tandon R, Agrawal K, Narayan RP, Tiwari VK, Prakash V, Kumar S, et al. Firecracker injuries during Diwali festival: The epidemiology and impact of legislation in Delhi. *Indian J Plast Surg.* 2012;45: 97-101.
3. Kuhn F, Morris R, Witherspoon CD. Birmingham Eye Trauma Terminology (BETT): terminology and classification of mechanical eye injuries. *Ophthalmol Clin North Am.* 2002; 15(2): 139-43.
4. Wisse RP, Bijlsma WR, Stilma JS. Ocular firework trauma: A systematic review on incidence, severity, outcome and prevention. *Br J Ophthalmol.* 2010; 94: 1586-91
5. Chang IT, Prendes MA, Tarbet KJ, Amadi AJ, Chang SH, Shaftel SS. Ocular Injuries from Fireworks: The 11-Year Experience of a US Level I Trauma Center. *Eye (Lond).* 2016; 30(10): 1324–30.

**How to cite this article:** Lodhi SAK, Saudhamini S, Shreya TS, Mukkavalli N. Spectrum of fireworks related ocular injuries on the day of Deepavali. *Indian J Case Reports.* 2017; 3(1): 1-4.

*Conflict of interest: None stated, Funding: Nil*