

Case Report

Ileal tuberculosis presenting with bleeding per rectum followed by perforation peritonitis: A rare presentation

Rajiv Srivastava

From Department of Surgery, Government Medical College, Haldwani, Uttarakhand, India

Correspondence to: Rajiv Srivastava, Department of Surgery, Government Medical College, Haldwani, Uttarakhand, India.

E-mail: rajivsrivastava21@rediffmail.com

Received - 23 September 2017

Initial Review - 21 October 2017

Published Online - 08 November 2017

ABSTRACT

Here, I present a rare case of ileal tuberculosis who was admitted with bleeding per rectum associated with fever for 4-5 days. His Widal test was positive so was treated in the lines of enteric fever, but subsequently patient developed perforation peritonitis. On exploratory laparotomy, the whole abdominal cavity was filled with hemorrhagic fluid along with perforation at ileal segment around half a feet proximal to ileocecal junction and site was filled with blood clot. Ileostomy was performed but the patient had persistent fever beside higher antibiotics. Latter chest X-ray of the patient showed pleural effusion on the left side, and pleural fluid analysis showed the evidence of tuberculosis. Histopathological report of ileal segment confirmed the diagnosis of tuberculosis. The patient is responding well to antituberculosis treatment and now waiting for ileostomy closure.

Key words: *Antituberculosis treatment, Bleeding per rectum, Enteric fever, Exploratory laparotomy, Ileal tuberculosis, Perforation peritonitis colonoscopy*

The clinical manifestations of intestinal tuberculosis are nonspecific. Most of the patients present with low-grade fever, weight loss, abdominal pain, anorexia, or diarrhea [1-3]. Intestinal tuberculosis presenting with lower gastrointestinal bleed is rare and accounts for only about 5% of the cases of lower gastrointestinal bleeding [4,5]. In the presence of active pulmonary tuberculosis, vague abdominal pain, weight loss, and passage of small amount of blood per rectum could suggest the possibility of intestinal tuberculosis. Massive gastrointestinal bleed occurs because of underlying obliterative endarteritis within the ulcer crater. Here, we present a case of ileal tuberculosis, who presented with bleeding per rectum and later found to have perforation peritonitis.

CASE REPORT

A 25-year-old male patient presented with the complaints of high-grade fever for 4-5 days and bleeding per rectum for 2 days. His Widal test was positive so the patient was admitted in the medicine department for further workup and treatment. In view of endemic of dengue fever, dengue serology was also done, but it was negative. The patient developed severe pain abdomen on the 2nd day of admission. X-ray abdomen confirmed the perforation; hence, he was transferred to the surgical site. On exploratory laparotomy, the whole abdominal cavity was filled with hemorrhagic fluid, and there was a perforation of around 2 cm × 2 cm half feet proximal to the ileocecal junction, and the perforation site was filled with blood clot. Subsequently, ileostomy was performed (Fig. 1).

The patient continued to have fever postoperatively, and sterile culture was reported from peritoneal fluid. Later on, the patient developed chest pain for which a chest X-ray was done. It revealed pleural effusion on the left side (Fig. 2). Pleural tapping was done and sent for examination which was suggestive of tuberculosis with high adenosine deaminase levels. Histopathological examination of the resected segment showed the granulomas which confirmed the diagnosis of tuberculosis (Fig. 3). Antitubercular treatment was started with four drugs (rifampicin, isoniazid, ethambutol, and pyrazinamide) to which patient responded well and fever subsided within 2 days. He was discharged after 7 days. Now, he is waiting for ileostomy closure. There was no recurrence of fever or bleeding on follow-up.

DISCUSSION

Abdominal tuberculosis is very common in India and developing countries. It is the 6th most common type of extrapulmonary tuberculosis. Ileocecal region is the site of involvement in 85% of the patients with tuberculosis enteritis, presumably because of the abundance of lymphoid tissue in this area. Three patterns of involvement are seen, namely, (a) hypertrophic, (b) ulcerative, and (c) ulcerohypertrophic. This is hypertrophic reaction that causes contracture and stenosis of the lumen of distal lumen which requires resection. Pathologic findings of short diseased segment of ileum are common; although it is unusual to have proximal ileum involvement without the involvement of terminal ileum [3]. The present patient had solitary stricture in the terminal ileum. The

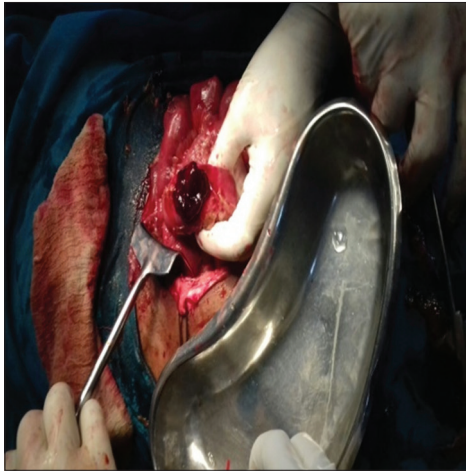


Figure 1: Ileal perforation site studded with blood clot

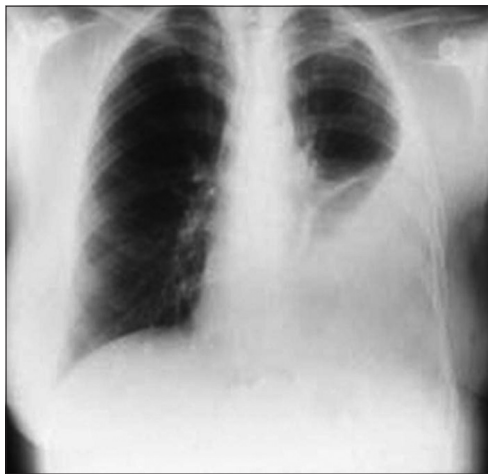

Figure 2: X-ray chest showing left-sided pleural effusion

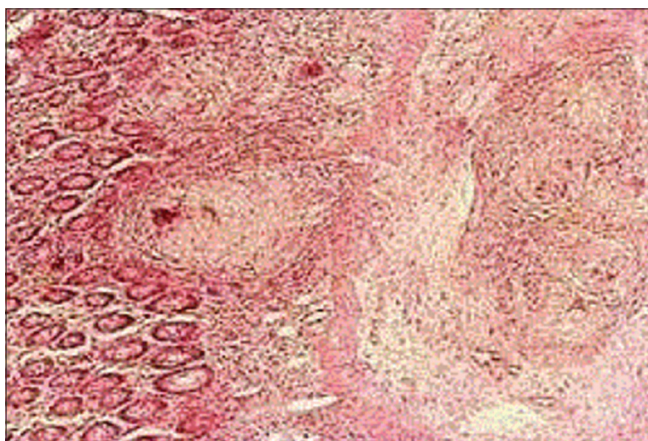


Figure 3: Mucosa and submucosa of ileal segment showing granulomas

granulomas in the bowel may be noncaseating with circumferential ulcers, which can lead to bowel obstruction. Sherman *et al.*[4] found both stricture formation and evidence of obliterative endarteritis in their patient. They found Technetium 99 m labeled red blood cell scan very helpful in localizing the bleeding lesion.

Intestinal tuberculosis is more difficult to diagnose than pulmonary tuberculosis and requires a high index of suspicion [5].

Sometimes, the patient has very short duration of complaint and ileal tuberculosis is an incidental finding. Any patient presenting with bleeding per rectum with a history of fever should be thoroughly investigated, and besides few common diseases like Crohn’s disease/ulcerative colitis, tuberculosis should be suspected. Physical examination findings are nonspecific but may include abdominal tenderness, ascites, and hepatomegaly [6-8]. Diagnosis is often delayed, as this form of tuberculosis is commonly misdiagnosed as Crohn’s disease or carcinoma of the colon due to their similar clinical, radiographic, and endoscopic presentations.

Laboratory testing is also nonspecific but may reveal anemia, leukocytosis, increased alkaline phosphatase, and hypoalbuminemia. A chest X-ray may demonstrate evidence of pulmonary TB; however, a normal reading does not exclude disease, as only 15–20% of intestinal TB is associated with active pulmonary TB. Colonoscopy is widely considered to be the most useful diagnostic tool. Bhargava *et al.*[9] have described typical endoscopic findings including segments of mucosal nodules and ulcerations (present in this case), areas of stricture, and mucosal nodules with or without pseudopolypoid folds. Granuloma is more frequently recovered from ulcerated lesions than from nodular lesions. Colonoscopy is also useful to exclude coexisting pathology, particularly in populations at risk for malignant disease. Distinction from inflammatory bowel disease is particularly important because the conventional treatment of steroids is clearly contraindicated in the setting of tuberculosis.

In a study of 130 patients with alimentary tract tuberculosis by al Karawi *et al.*,[10] the disease was located in the small bowel in 44 patients (33.8%) and the large bowel in 29 patients (22.3%). Moreover, out of 44 patients with small bowel tuberculosis, hemorrhage was observed in only one patient while it was observed in three of 29 patients with large bowel tuberculosis. Monkemuller and Lewis[11] found that colonoscopy showed lesions in two of four patients. Except for one patient, histological small intestinal tuberculosis was not found. 99 mTc red blood cell scintigraphy was useful to locate the bleeding lesion and to make a pre-operative diagnosis of hemorrhage from the ileum. Computed tomography scanning of the abdomen can exhibit mural thickening, extramural inflammation, and strictures. Colonoscopy can demonstrate ulceration, nodularity, polyps, and luminal narrowing [12]. Mukewar *et al.*[13] found ulceration to be the most common lesion, found in 88% of the patients. Biopsy of colonic ulcers typically demonstrates either caseating or noncaseating granulomas with predominantly lymphocytic chronic inflammation. Acid-fast bacilli staining can demonstrate the presence of mycobacteria; however, in one series, this was reported to be positive in only 36% of cases. Other diagnostic tests include tissue culture, polymerase chain reaction, and immunostaining.

Complications of abdominal tuberculosis are obstruction, malabsorption, blind loop syndrome, fecal fistula, cold abscess formation, hemorrhage, and perforation. Treatment revolves around antituberculosis treatment (ATT) the World Health

Organization recommends ATT for 6-9 months. Surgery is needed in nonresolving intestinal obstruction, severe hemorrhage, and acute abdomen like perforation or when diagnosis is uncertain.

CONCLUSION

The ileal tuberculosis with bleeding per rectum is a rare entity and association with perforation peritonitis is even rarer. Any patient presenting with bleeding per rectum should undergo colonoscopy and beside other causes, intestinal tuberculosis shall be kept in mind. Diagnostic laparoscopy with adequate biopsy shall be considered in selected cases. Resected segment of ileum, ileocolic region or mesenteric lymph nodes if enlarged shall be sent for histopathological diagnosis of tuberculosis.

REFERENCES

1. Sharma MP, Bhatia V. Abdominal tuberculosis. *Indian J Med Res* 2004;120:305-15.
2. Hopewell PC. A clinical view of tuberculosis. *Radiol Clin North Am* 1995;33:641-53.
3. Tishler JM. Tuberculosis of the transverse colon. *AJR Am J Roentgenol* 1979;133:229-32.
4. Sherman HI, Johnson R, Brock T. Massive gastrointestinal bleeding from tuberculosis of the small intestine. *Am J Gastroenterol* 1978;70:314-6.
5. Watanabe T, Kudo M, Kayaba M, Shirane H, Tomita S, Orino A, *et al.* Massive rectal bleeding due to ileal tuberculosis. *J Gastroenterol* 1999;34:525-9.
6. Verma P, Kapur BM. Massive rectal bleeding due to intestinal tuberculosis. *Am J Gastroenterol* 1979;71:217-9.
7. Brenner SM, Annes G, Parker JG. Tuberculous colitis simulating nonspecific granulomatous disease of the colon. *Am J Dig Dis* 1970;15:85-92.
8. Anscombe AR, Keddie NC, Schofield PF. Caecal tuberculosis. *Gut* 1967;8:337-43.
9. Bhargava DK, Tandon HD, Chawla TC, Shrinivas, Tandon BN, Kapur BM. Diagnosis of ileocecal and colonic tuberculosis by colonoscopy. *Gastrointest Endosc* 1985;31:68-70.
10. al Karawi MA, Mohamed AE, Yasawy MI, Graham DY, Shariq S, Ahmed AM, *et al.* Protean manifestation of gastrointestinal tuberculosis: Report on 130 patients. *J Clin Gastroenterol* 1995;20:225-32.
11. Monkemuller KE, Lewis JB Jr. Massive rectal bleeding from colonic tuberculosis. *Am J Gastroenterol* 1996;91:1439-41.
12. Morgante PE, Gandara MA, Sterle E. The endoscopic diagnosis of colonic tuberculosis. *Gastrointest Endosc* 1989;35:115-8.
13. Mukewar S, Mukewar S, Ravi R, Prasad A, Dua KS. Colon tuberculosis: Endoscopic features and prospective endoscopic follow-up after anti-tuberculosis treatment. *Clin Transl Gastroenterol* 2012;3:e24.

Funding: None; Conflict of Interest: None Stated.

How to cite this article: Srivastava R. Ileal tuberculosis presenting with bleeding per rectum followed by perforation peritonitis: A rare presentation. *Indian J Case Reports*. 2017;3(4):276-278.